(https://www.j
criteria/two-
stars)
(https://www.a
letter=oa)

Research Journal of Health Sciences

Journal / Research Journal of Health Sciences (/index.php/rejhs) / Vol. 6 No. 1 (2018) (/index.php/rejhs/issue/view/16912) / Articles

Published: 2018-05-18

Original Article

Editorial (https://www.ajol.info/index.php/rejhs/article/view/171303)
R.U. Anyaehie
1-2

DOI: 10.4314/rejhs.v6i1.1
(https://doi.org/10.4314/rejhs.v6i1.1)

DOWNLOAD PDF (HTTPS://W

Pattern of presentation of ear, nose, throat, head and neck injury in a developing country (https://www.ajol.info/index.php/rejhs/article/view/171304)
W.A. Adegbiji, T.G. Olajide, O.A. Olajuyin, F. Olatoke, C.C. Nwawolo
3-12

DOI: 10.4314/rejhs.v6i1.2
(https://doi.org/10.4314/rejhs.v6i1.2)

DOWNLOAD PDF (HTTPS://W

Moringa oleifera ameliorates cuprizone-induced cerebellar damage in adult female rats (https://www.ajol.info/index.php/rejhs/article/view/171305)
G.O. Omotoso, R.E. Kadir, S.F. Lewu, I.T. Gbadamosi, A.A. Akinlolu, G.O. Adunmo, R.M. Kolo, M.O. Lawal, M.O. Ameen
13-25

DOI: 10.4314/rejhs.v6i1.3
(https://doi.org/10.4314/rejhs.v6i1.3)

DOWNLOAD PDF (HTTPS://W

Butanol extract of *Manihot esculenta* leaf modulated cigarette butt leachate-mediated liver mitochondrial membrane permeabilization and its functional capacity (https://www.ajol.info/index.php/rejhs/article/view/171306)
E.I.O. Ajayi, A.E Iyoha, F.O. Abdulazeez
26-34

DOI: 10.4314/rejhs.v6i1.4
(https://doi.org/10.4314/rejhs.v6i1.4)

DOWNLOAD PDF (HTTPS://W

Optimal timing of post-operative haematocrit check in obstetric and gynaecological surgeries (https://www.ajol.info/index.php/rejhs/article/view/171307)
O.O. Aworinde, K.J. Olufemi-Aworinde, O.A. Ogunlaja, T.A. Olutogun, S.E. Akinola, A.S. Adeyemi
35-42

DOI: 10.4314/rejhs.v6i1.5
(https://doi.org/10.4314/rejhs.v6i1.5)

DOWNLOAD PDF (HTTPS://W

Pranic Healing for Partially Blind- A case study (https://www.ajol.info/index.php/rejhs/article/view/171308)
Srikanth N Jois, Nagendra K Prasad
43-47

DOI: 10.4314/rejhs.v6i1.6
(https://doi.org/10.4314/rejhs.v6i1.6)

DOWNLOAD PDF (HTTPS://W

Journal Identifiers

eISSN: 2467-8252
print ISSN: 2360-7793

About AJOL

AJOL Team (https://www.ajol.info/index.php/ajol/team)
AJOL Board (https://www.ajol.info/index.php/ajol/board)
Donors (https://www.ajol.info/index.php/ajol/donors)
Partners (https://www.ajol.info/index.php/ajol/AJOL-partners)
Sponsors (https://www.ajol.info/index.php/ajol/npo)
Contact (https://www.ajol.info/index.php/ajol/contact-AJOL)
Usage Statistics (https://www.ajol.info/index.php/ajol/statistics)
Journal Quality (https://www.ajol.info/index.php/ajol/JPPS)
About AJOL (https://www.ajol.info/index.php/ajol/about-AJOL-African-Journals-Online)

Policies

Whistle blowing (https://www.ajol.info/index.php/ajol/whistle-blowing)
Terms and conditions (https://www.ajol.info/index.php/ajol/terms-and-conditions)
Non-profit Organisation (https://www.ajol.info/index.php/ajol/npo)

AJOL is a non-profit, relying on your support.

DONATE

AJOL's largest donor partners:

Norad (https://www.norad.no/en) wellcome (https://wellcome.org/) SCOSS (https://www.scoss.org)

SIGN UP FOR TITLES OF INTEREST (HTTPS://WWW.AJOL.INFO/INDEX.PHP/AJOL/AJOLNOTIFICATIONS/REGISTERAJOLNOTIFICATIONS?NEWJOURNALSONLY=1)

Follow AJOL

(HTTPS://TWITTER.COM/ACADEMICSEDCOM/MINERICANJOURNALS-ONLINE)

Moringa oleifera ameliorates cuprizone-induced cerebellar damage in adult female rats

***Omotoso G.O.[1], Kadir R.E.[1], Lewu S.F.[1], Gbadamosi I.T.[1], Akinlolu A.A.[1], Adunmo G.O.[2], Kolo R.M.[1], Lawal M.O.[1], Ameen M.O.[3]**

Abstract

Objectives: Cuprizone is a neurotoxicant used in modeling demyelinating disorders. This study explored the effects of *Moringa oleifera* (MO) on oxidative, histomorphological and behavioural changes in cuprizone-damaged cerebellum.

Methods: Twenty adult female Wistar rats were grouped into 4, each group having five animals. Group A received 1 ml of normal saline (Control); group B received 0.4% cuprizone; group C received 15.6 mg/kgBW *Moringa oleifera* leaf extract; group D received 0.4% cuprizone and 15.6 mg/kgBW *Moringa oleifera*, orally for 5 weeks. The animals were assessed for exploratory and locomotor activities, while the cerebellum was processed for histology and assayed for nitric oxide (NO), catalase (CAT) and superoxide dismutase (SOD) activities.

Results: Cuprizone treatment caused weight reduction, disruption of Purkinje cell layer, cellular degeneration, reduction in NO, CAT and SOD activities. However, these changes were ameliorated when co-administered with MO.

Conclusion: The anti-oxidative property of *Moringa oleifera* is responsible for its ameliorative effect in cuprizone neurotoxicity.

Keywords: demyelination, cuprizone, cerebellar damage, *Moringa oleifera*, oxidative enzymes

*Correspondence author
Dr. G. O Omotoso,
http://orcid.org/0000-0001-7727-6943
Email: gabrielolaiya@yahoo.com; omotoso.go@unilorin.edu.ng

[1]Department of Anatomy, Faculty of Basic Medical Sciences, University of Ilorin, Ilorin, Nigeria.
[2]Department of Medical Biochemistry, Faculty of Basic Medical Sciences, University of Ilorin, Ilorin, Nigeria.
[3]Department of Chemistry, Faculty of Physical Sciences, University of Ilorin, Ilorin, Nigeria.

Date of Submission: December 29, 2017 *Date of Acceptance: February 22, 2018*

Research Journal of Health Sciences subscribed to terms and conditions of Open Access publication. Articles are distributed under the terms of Creative Commons Licence (CC BY-NC-ND 4.0). (http://creativecommons.org/licences/by-nc-nd/4.0).

http://dx.doi.org/10.4314/rejhs.v6i1.3

Moringa oleifera améliore les dommages cérébelleux induits par la cuprizone chez les rats femelles adultes

***Omotoso G.O.[1], Kadir E.R.[1], Lewu S.F.[1], Gbadamosi I.T.[1], Akinlolu A.A.[1], Adunmo G.O.[2], Kolo R.M.[1], Lawal M.O.[1], Ameen M.O.[3]**

Resume

Objectifs: Cuprizone est un neurotoxique utilisé dans la modélisation des troubles démyélinisants. Cette étude a exploré les effets de Moringa oleifera sur les changements oxydatifs, histomorphologiques et comportementaux du cervelet endommagé par la cuprizone.

Méthodes: 20 rats femelles Wistar adultes ont été regroupés en 4, chaque groupe ayant cinq animaux. Le groupe A a reçu 1 ml de solution saline normale (témoin); le groupe B a reçu 0,4% de cuprizone; le groupe C a reçu 15,6 mg / kg de poids corporel d'extrait de feuille de Moringa oleifera; le groupe D a reçu 0,4% de cuprizone et 15,6 mg / kg de Moringa oleifera, par voie orale pendant 5 semaines. Les animaux ont été évalués pour des activités exploratoires et locomotrices, tandis que le cervelet a été traité pour l'histologie et testé pour les activités oxyde nitrique (NO), catalase (CAT) et superoxyde dismutase (SOD).

Résultats: Le traitement par cuprizone a entraîné une réduction du poids, une perturbation de la couche cellulaire de Purkinje, une dégénérescence cellulaire, une réduction des activités de NO, de CAT et de SOD. Cependant, ces changements ont été améliorés quand co-administré avec MO.

Conclusion: La propriété antioxydante de Moringa oleifera est responsable de son effet améliorateur dans la neurotoxicité de la cuprizone.

Mots-clés: démyélinisation, cuprizone, lésions cérébelleuses, Moringa oleifera, enzymes oxydatives

*Correspondance auteur
Dr. G. O Omotoso,
http://orcid.org/0000-0001-7727-6943
Email: gabrielolaiya@yahoo.com; omotoso.go@unilorin.edu.ng

[1]Department of Anatomy, Faculty of Basic Medical Sciences, University of Ilorin, Ilorin, Nigeria.
[2]Department of Medical Biochemistry, Faculty of Basic Medical Sciences, University of Ilorin, Ilorin, Nigeria.
[3]Department of Chemistry, Faculty of Physical Sciences, University of Ilorin, Ilorin, Nigeria.

Date of Submission: December 29, 2017 *Date of Acceptance: February 22, 2018*

Research Journal of Health Sciences subscribed to terms and conditions of Open Access publication. Articles are distributed under the terms of Creative Commons Licence (CC BY-NC-ND 4.0). (http://creativecommons.org/licences/by-nc-nd/4.0).

http://dx.doi.org/10.4314/rejhs.v6i1.3

INTRODUCTION

Cuprizone (CPZ) is a typical myelin toxicant that selectively injures oligodendrocytes and induces demyelination in the central nervous system (CNS) of rodents (1). The cuprizone model is commonly used for toxic demyelination (2), and results in a form of reversible demyelination, with spontaneous remyelination occurring shortly after its withdrawal. The extent of demyelination induced by cuprizone has been found to be dose-dependent (3,4). Doses that have been used overtime include: 0.1%, 0.2%, 0.3%, 0.4%, 0.5%, and 0.6%. Increase in cuprizone concentrations, however, results in mitochondrial dysfunction (5).

Copper is an essential element for the function of several metalloproteases and decreased levels are observed in a number of neurodegenerative disorders (6). A consistent pattern of demyelination has been observed mainly with corpus callosum. Oligodendrocyte depletion was also reported in the cerebellar peduncles, cortex and dorsal hippocampus commissures (7). Copper ions accelerate lipid peroxidation, by two mechanisms; first, they convert hydrogen peroxide to OH^{-} (a free radical) in the Fenton reaction by splitting the O–O bond. With increased lipid peroxidation, the cell membrane loses its integrity as oxidative stress is induced (8).

The mechanism by which cuprizone exacts its neurotoxic effects is still being investigated and possible modes of action have been reported. According to Benetti et al., (9) although cuprizone is neurotoxic, it does not cross the neuronal cell membrane. One possible mode of action therefore is by the copper chelation activity (10), leading to low serum level of copper and demyelination in mice (11). After these initial works on cuprizone, several studies have been conducted over the decades using CPZ as a model for the induction of demyelination in different experimental animal species including mice, rats, guinea pigs, hamsters of different strains (12,13). Marked cellular changes and altered copper and zinc homeostasis in body tissues and CNS have been reported following chronic cuprizone intoxication (14). Presence of structural changes in mitochondrial morphology such as the formation of megamitochondria has been reported (12).

In recent years, more researches have been focused on oxidative stress as a consequence of imbalance in cellular redox homeostasis. A major role of reactive oxygen species (ROS) in the pathophysiology of demyelination and CNS inflammatory disorders have been shown over time (15). An imbalance in cellular redox homeostasis leads to oxidative stress which may as well be caused by a number of biological mechanisms resulting in production of excess ROS (16). Changes leading to high concentration of ROS have a high likelihood of causing tissue damage and cell death within the CNS (17). An increase in ROS leads to production of toxic molecules, such as lipid peroxidants which are strong reactive electrophiles capable of inducing oxidative stress (18).

ROS and their reactive products cause injury to the cells of neurons and oligodendrocytes (19). ROS plays a major role in encouraging tissue damage in CNS inflammation (15). There is a complex relationship between oxidative injury and anti-oxidant defences; however, cells possess diverse means of reducing ROS. These include the activities of endogenous oxidative enzymes such as nitric oxide, glutathione peroxidase, catalase and superoxide dismutase, amongst others.

The cerebellum is a component of the CNS that plays an important role in the coordination of voluntary movements such as posture and balance, bringing about smooth and balanced muscular activity. However, it is a common site of injury whenever demyelination occurs, especially in individuals with progressive neurological conditions (20). Derailment in the normal functions of the cerebellum is a major cause of disability, regardless of treatment with disease-modifying agents (21). Meanwhile, cerebellar dysfunction brought about by demyelination is thought to occur due to injury to both the white matter and gray matter (22).

Moringa oleifera is a medicinal plant with high nutritional and numerous health benefits, and various parts of the plant such as the leaves, seeds and pods, contain copper and some other heavy metals (23). The active phytochemicals of the aqueous extract of the leaves include anthraquinone, terpenoids, cardiac glycoside, tannins, carotenoids, phenols, saponins, anthocyanin, quacetin and luteolin (24,25). Some studies have demonstrated *Moringa oleifera* as being antitumor, antihypertensive, antispasmodic, and hepatoprotective, including its ability to lower reactive oxygen species and cholecterol levels (26,27,28). *Moringa oleifera* has the capacity to supply the free atoms needed by the human body and mitigate the effect of free radicals which are observed in cuprizone-induced demyelination

(29). This study was designed to determine the cytoprotective ability of *Moringa oleifera* leaf extract in cuprizone-induced cerebellar injury.

MATERIALS AND METHODS

Experimental Animals

Twenty adult female rats of average weight 120 g were obtained from Bolaji Enterprise, Ilorin and kept in the Animal House of Faculty of Basic Medical Sciences, University of Ilorin, following ethical considerations. The rats were ascertained at the Department of Anatomy to be the Wistar strain of albino rats and were maintained on normal rodent feeds procured from Ogo-Oluwa Livestock Enterprises, Ilorin. The feeds and water were provided liberally. The animals were weighed at intervals during the experiments.

Administration of Drugs and Plant Extracts

Cuprizone (CPZ) was purchased from Sigma-Aldrich®, Germany. CPZ was prepared with the feeds at a dose of 0.4% CPZ (2). *Moringa oleifera* (MO) plant was obtained and fractionation of the ethanolic extract of the leaves of the plant was carried out using the silica gel open column method at the Department of Chemistry, University of Ilorin, Nigeria. The fraction MoF6 was used in the present study to evaluate the toxicity effects of MO leaves on adult female Wistar rats. Mode of administration of MO was oral and the treatment lasted for a period of 5 weeks.

Experimental Design

The rats were categorised into 4 groups, each having five (5) rats as shown below:

Group A: Control, received 1 ml normal saline;

Group B: received 0.4% cuprizone diet

Group C: received 15.6 mg/kg BW *Moringa oleifera*

Group D: received a combination of cuprizone diet and *Moringa oleifera* at same doses as Groups B and C respectively.

Behavioural Testing

Rats were tested in the open field apparatus following the last administration to assess locomotor and exploratory activities (30). The open field apparatus was made from plywood measuring 100 cm x 100 cm with walls 50 cm high. The floor was divided into square grids each measuring 25 cm in length with a blue marker and a centre square of the same length was drawn with a red marker. During the test, rats were randomly picked from each group by the tails and dropped at the center square and allowed to explore the open field for 10 minutes while a video camera located above the apparatus was used to record their activities. Three behaviours were scored from the recorded video by an independent observer who analyzed the number of lines crossed, rearing frequency and stretch attend posture frequency (30).

Animal Sacrifice and Tissue Collection

The Wistar rats were sacrificed through cervical dislocation at the end of the behavioural assessment following the five week treatment. The cranium of each animal was exposed, the brain removed carefully and weighed. The cerebellum was also excised and weighed. Brain samples were either fixed in 4% paraformaldehyde (PFA) or placed in 30% cold sucrose solution.

Tissue Processing for Histochemical and Biochemical Studies

PFA-fixed tissues were processed routinely for histological and histochemical examination of the cerebellum using Haematoxylin and Eosin and Cresyl fast violet stains after the cerebellum was dehydrated through grades of alcohol, cleared with xylene, infiltrated and embedded in paraffin and then sectioned using a rotary microtome.

The enzymes nitric oxide (NO), catalase (CAT) and superoxide dismutase (SOD) were assayed to assess the level of enzyme activities in the cerebellum of Wistar rats using standard methods. Homogenate of the cerebellum was made with ice cold 30% sucrose solution with the use of a Teflon homogenizer. The homogenate was then scooped and poured into a 5 ml plain labeled specimen bottle and then placed in the centrifuging tube containing ice. The homogenate was centrifuged for about 15minutes at 3000 rpm. The supernatant of the homogenate was decanted into another plain labeled specimen bottle for further biochemical assay.

Statistical analysis

For quantitative measures, the groups were analyzed using one-way analysis of variance (ANOVA), and Tukey post hoc test was used for group comparison where appropriate. The level of significance was set at $p<0.05$.

RESULTS

Physical Observation

There was a marked decrease in gain in body weights in the group exposed to cuprizone

when compared to the control animals. The rats that received CPZ and MO showed a gain in weight compared to control group. Rats treated with MO showed a marked increase in weight compared to control although this weight gain was not statistically significant ($p>0.05$). The animals that received normal saline had the lowest weight difference, however, this least growth rate was not statistically significant ($p>0.05$). The weight difference in rats exposed to cuprizone (Group B) and cuprizone and MO (Group D) was not statistically significant (Figure 1).

Behavioural analysis

Rearing frequency, number of lines crossed and stretch attend posture frequency were extrapolated from the open field test. CPZ-treated animals presented with significantly reduced rearing frequency relative to control ($p<0.005$), MO-treated animals ($p<0.005$), as well as CPZ+MOR group ($p<0.05$). Also, the rearing frequency of the CPZ+MO group was significantly lower than that of the control and MO treated rats (both at $p<0.005$). Likewise, CPZ-only group manifested a depleted number of lines crossed when compared to the control ($p<0.005$) and MO treated animals ($p<0.005$). Correspondingly, CPZ significantly increased the level of stretch attend posture frequency in the CPZ-only group when compared with control group, MO group and CPZ+MO group (all at $p<0.005$). The stretch attend posture frequency of animals in the CPZ+MO group was significantly higher than that of the MO treated rats ($p<0.05$).

Oxidative stress biomarkers

The level of activity of nitric oxide (NO) was significantly reduced in the CPZ group. However, the groups administered with MO alone or with CPZ had a significant increase in NO level compared with cuprizone only group ($p<0.05$).

The level of catalase (CAT) in the CPZ group decreased significantly when compared to the control group ($p<0.05$). The animals that received MO had higher levels of CAT compared with the Control ($p>0.05$). The CPZ+MO group was able to balance the level of CAT that was diminished in the CPZ group, though the difference was not statistically significant ($p>0.05$).

CPZ treatment led to a significant reduction in the level of superoxide dismutase (SOD) in the cerebellar cortex of adult female Wistar rats relative to the Control and the MO group ($p<0.05$), while there was no significant changes in the level of SOD in rats co-treated with CPZ+MO and the CPZ only group, though SOD level was higher in the former ($p>0.05$).

Histological and Histochemical Observations

Cerebellar neuronal morphology and cytoarchitectural assortment were studied within the cerebellar cortex across the transitional regions between the cerebellar molecular layers through the Purkinje layer into the granular layer at high power magnification. Characteristically normal morphological presentation and cellular density were observed within the cerebellar cortical layers of the control and MO treated rats. The cellular arrangement of these two groups was characterized by a single layer of Purkinje cells with conspicuous soma and axonal projection jetting deep into the molecular layer. Also, the granular layers of this group consist of small granule cells which are densely organized and deeply stained. The histoarchitectural presentation of the cerebellar cortical layer of CPZ-treated rats presented with degenerated Purkinje cells with pyknotic cell bodies and inconspicuous dendritic processes. Furthermore, the neuropil of the cells in this group appeared fragmented and poorly stained. The granular layer appeared less dense when compared to the control and cerebellar cortical histoarchitectural presentation. The histology of the cerebellar cortical layers of rats that were treated with CPZ+MO was characteristically similar to what was obtained from the control and MO group. It is important to note that the granular layer was less dense than that of the control slides; also, the Purkinje cells in the Purkinje layer appear to be better stained with fewer degenerative properties when compared to the CPZ-treated rats (Figure 9).

Histochemically, the control and *Moringa* slides presented with intensively stained Nissl substance with conspicuous cell bodies of the Purkinje cells and apparent axon projecting into the molecular layer. The granule cells of the granular layer were also intensively stained and compactly packed .The molecular layer was apparently delineated from granular layer by a single cell layer of the Purkinje cells. The CPZ-treated rats presented with extreme peripheral and chromatolytic Purkinje neurons in the Purkinje cell layer. A larger of these cells had degenerated despite the intense Nissl staining of the granule cells. Relative to the CPZ-treated rats, the CPZ + MO-treated rats presented with a more healthy Purkinje cell and compactly packed

granule cells in the granule cell layer with a staining intensity similar to those of the Control and MO-treated rats (Figure 10).

DISCUSSION

The consequence of the use of CPZ in the induction of CNS demyelination is not only restricted to the target nervous tissue. In the present work, CPZ-intoxicated rats recorded significant drop in body weight. The leaf extract of MO as used in this study had remarkable influence on body weight in enhancing the growth of the animals. When co-administered with CPZ, MO helped to ameliorate the weight-lowering effect of CPZ. The reduction in weight observed in CPZ-treated rats could be due to a reduction in feed intake. Similarly, previous studies have associated CPZ use with reduction in body weights (31,32). Studies by Steelman *et al*. (31) observed an initial reduction of food intake in CPZ-fed mice in the first few days of treatment. As reported by Goldberg *et al*., (33) mice fed on CPZ lost approximately 10% of their body weight during the first week of intoxication, which was followed by a gradual weight gain during the next 4 weeks. Although normal feeding habit resumes after the initial weight loss, such animals could still have significant weight loss at the end of the experiment (31).

CPZ consumption impacts remarkably on the behavioural pattern of experimental rats in this study. The pattern of change in the exploratory drive and locomotor activities of CPZ-treated animals using the open field test suggests the negating role that CPZ plays in neuronal circuitry. However, the concurrent administration of MO was able to significantly normalize the rearing frequency, number of lines crossed and the stretch attend posture.

As earlier observed, CPZ intoxication induces mitochondrial injury and subsequently increases the production of reactive oxygen species and neurons are not spared (5). There are different views by researchers on how cuprizone affects the activities of nitric oxide in the brain. However in our study, CPZ administration was associated with decreased level in NO activities. Nitric oxide (NO) is a signaling molecule that is very critical in the pathogenesis of inflammation (34). With the decreased level of NO observed in rats given CPZ only, it may seem inflammation did not occur implying a neuroprotective effect going by what was described by Cook *et al*. (34) In rats that received CPZ and MO, however, the increase in NO can be linked to the neuroprotective activities of MO. Nitric oxide plays a regulatory role in homeostatic processes, such as in the regulation of the oxidation/reduction reaction, and its concentration determines if its activities would be protective or injurious (35). Thus, the reduced level of NO activity may be a response to ameliorate the effect of increased generation of free radicals upon CPZ administration with elevated level when co-administered with MO which is known to be rich in antioxidants. Meanwhile, Abdel *et al*. (36) reported that nitric oxide has a neuroprotective role in the brain through its anti-inflammatory properties.

Other anti-oxidative enzymes examined in this study (catalase and superoxide dismutase) have similar pattern of effect, in which case cuprizone intoxication led to marked reduction in the activities of these enzymes. With the concomitant use of MO with CPZ in this study, CPZ-lowering effect of anti-oxidative enzymes was abolished due to the presence of high levels of potent natural antioxidant compounds in MO, and this is also in concordance with earlier findings (37).

Cortical demyelination occurs both in the gray and white matters of the cerebral cortex (38). Kutzelnigg *et al*. (39) studied human patients with multiple sclerosis (MS) and observed that the cerebellar cortex is particularly affected by demyelination, especially in patients with primary and secondary progressive MS. Cerebellar demyelination affected the Purkinje layer, molecular layer and extended in variable depths into the granular layer. A detailed observation showed a moderate, but signiflcant reduction of Purkinje cell density in areas of cortical demyelination, when demyelinated plaques were compared with normal cerebellar cortex of CPZ-treated animals.

CONCLUSION

CPZ induces demyelination in the cerebellum of Wistar rats and these changes are capable of disrupting the normal functions of the cerebellum. However, administration of the ethanolic extract of the leaves of MO offers protective role in ameliorating the behavioural, morphological and oxidative damage associated with demyelination.

Acknowledgement: The authors wish to acknowledge the assistance of technical staff of the Department of Anatomy, Histopathology and the Central Research Laboratory, University of Ilorin for their support in the Laboratory aspect of the work.

Conflicts of interest: The authors hereby declare

that there is no conflict of interest associated with this paper.

REFERENCES

1. Taylor LC, Puranam K, Gilmore W, Ting JPY, Matsushima GK. 17 β-estradiol Protects Male Mice from Cuprizone-induced Demyelination and Oligodendrocyte Loss. *Neurobiol Dis, 2010; 39*(2):127–137.
2. Stidworthy MF, Genoud S, Suter U, Mantei N, Franklin RJ. Quantifying the early stages of remyelination following cuprizone-induced demyelination. *Brain Pathology*, 2003; 13: 329–339.
3. Hiremath MM, Saito Y, Knapp GW, Ting JP, Suzuki K, Matsushima GK. Microglia/macrophage accumulation during cuprizone-induced demyelination in C57BL/6 mice. *J Neuroimmunol*, 1998; 92: 38–49.
4. Hillis JM, Davies J, Mundim MV, Al-Dalahmah O, Szele FG. Cuprizone demyelination induces a unique inflammatory response in the subventricular zone. *Journal of Neuroinflammation, 2016; 13*(1): 190. http://doi.org/10.1186/s12974-016-0651-2
5. Faizi M, Salimi A, Seydi E, Naserzadeh P, Kouhnavard M, Rahimi A, et *al*. Toxicity of cuprizone a Cu(2+) chelating agent on isolated mouse brain mitochondria: a justification for demyelination and subsequent behavioral dysfunction. Toxicol Mech Methods, 2016; 26(4):276-83.
6. Schrag M, Mueller C, Oyoyo U, Kirsch WM. Iron, zinc and copper in the Alzheimer's disease brain: a quantitative meta-analysis. Some insight on the influence of citation bias on scientific opinion. *Prog Neurobiol*, 2011; 94(3):296–306.
7. Mirona VE, Kuhl mann T, Antelc JP. Cells of the oligodendroglial lineage, myelination, and remyelination. Biochimica et Biophysica Acta (BBA) - Molecular Basis of Disease, 2011. 1812(2): 184-193.
8. Garthwaite J, Boulton CL. Nitric oxide signalling in the central nervous system. *Ann Rev Physiol*, 1995; 57:683–706.
9. Benetti F, Ventura M, Salmini B, Ceola S, Carbonera D, Mammi S, *et al*. Cuprizone neurotoxicity, copper deficiency and neurodegeneration. *NeuroToxicology*, 2010; 31(5):509-17.
10. Nilsson G. A new colour reaction on copper and ceratin carbonyl compounds. *Acta Chem Scand* 1950; 4:205-8
11. Carlton WW. Response of mice to the chelating agents sodium diethyldithiocarbamate, alpha-benzoinoxime, and biscyclohexanone oxaldihydrazone. *Toxicol Appl Pharmacol* 1966;8:512-521
12. Asano M, Wakabayashi T,. Ishikawa K, Kishimoto H. Mechanism of the formation of megamitochondria by copper-chelating agents. IV. Role of fusion phenomenon in the cuprizone-induced megamitochondrial formation. *Acta Pathol Jpn*, 1978; 28:205-213.
13. Adamo AM, Paez PM, Escobar Cabrera OE, Wolfson M, Franco PG, Pasquini JM *et al.* Remyelination after cuprizone-induced demyelination in the rat is stimulated by apotransferrin. *Exp Neurol* 2006; 198:519-29.
14. Zatta P, Raso M, Zambenedetti P. Copper and zinc dismetabolism in the mouse brain upon chronic cuprizone treatment. *Cell Mol Life Sci* 2005; 62:1502–1513.
15. Cross AH, Manning PT, Keeling RM, Schmidt RE, Misko TP. Peroxynitrite formation within the central nervous system in active multiple sclerosis. *J Neuroimmunol*, 1998; 88(1-2):45-56.
16. Murphy MP. How mitochondria produce reactive oxygen species. *Biochemical Journal* 2009; 417:1-13.
17. Aggarwal S, Yurlova L, Simons M. Central nervous system myelin: structure, synthesis and assembly. *Trends Cell Biol* 2011; 21(10):585–93.
18. Abarikwu SO, Pant AB, Farombi EO. 4-Hydroxynonenal induces mitochondrial mediated apoptosis and oxidative stress in SH-SY5Y human neuronal cells. *Basic Clin Pharmacol Toxicol* 2012; 110(5):441-8.
19. French HM, Reid M, Mamontov P, Smmons RA, Grinspan JB. Oxidative stress disrupts oligodendrocyte maturation. *J Neurosc Res* 2009;87(14):3076-87.
20. Calabrese M, Mattisi I, Rinaldi F, Favaretto A, Atzori M, Bernardi V. *et al*. Magnetic resonance evidence of cerebellar cortical pathology in multiple sclerosis. *J Neurol Neurosurg Psychiatry* 2010; 81:401-4.
21. Waxman SG. Cerebellar dysfunction in multiple sclerosis: evidence for an acquired channelopathy. *Prog Brain Res* 2005; 148:353-65.
22. Wilkins A. Cerebellar Dysfunction in Multiple Sclerosis. *Front Neurol* 2017; *8:* 312. http://doi.org/10.3389/fneur.2017.00312
23. Fulgie LJ. The Miracle Tree: *Moringa oleifera:* Natural Nutrition for the Tropics; *Church World Service* Dakar 1999; 68.
24. Nweze NO, Nwafor FI. Phytochemical, proximate and mineral composition ofleaf extracts of Moringa oleifera Lam. from Nsukka, South-Eastern Nigeria. IOSR *J.Pharm. Biol. Sci*. 2014;9:99–103.
25. Omotoso GO, Gbadamosi IT, Olajide OJ, Dada-Habeeb SO, Arogundade TT, Emmanuel OY. *Moringa oleifera* phytochemicals protect the brain against experimental nicotine-induced neurobehavioural disturbances and cerebellar degeneration. *Pathophysiology* 2018; 25:57–62.
26. Luqman S, Srivastava S, Kumar R, Maurya AK, Chanda D. Experimental Assessment of *Moringa oleifera* Leaf and Fruit for Its Antistress, Antioxidant, and Scavenging Potential Using In Vitro and In Vivo Assays. *Evidence-Based Complementary and Alternative Medicine* Volume 2012 (2012),

http://dx.doi.org/10.1155/2012/519084
27. Sharma V, Paliwal R. Potential Chemoprevention of 7,12-Dimethylbenz[a]anthracene Induced Renal Carcinogenesis by *Moringa oleifera* Pods and Its Isolated Saponin. Indian J Clin Biochem. 2014; 29(2): 202–209.
28. Omodanisi EI, Aboua GY, Oguntibeju O. Therapeutic potentials and pharmacological properties of *Moringa oleifera Lam* in the treatment of diabetes mellitus and related complications. *Trop J Pharm Res* 2017;16 (7):1737-1746
29. Dayrit FM, Alcantar AD, Villasenor IM. Studies on *Moringa oleifera* seeds, Part I: The antibiotic compound and its deactivation in aqueous solution. *Philippine Journal of Science* 1990; 119:23-32.
30. Stanford SC. The Open Field Test: Reinventing the Wheel. *J Psychopharmacol* 2007; 21(2007):134–5.
31. Steelman AJ, Thompson JP, Li J. Demyelination and remyelination in anatomically distinct regions of the corpus callosum following cuprizone intoxication. *Neurosci Res*. 2012;72(1): 32–42.
32. Sachs HH, Kathryn K. Bercury KK, Daniela C. Popescu DC, *et al*. A New Model of Cuprizone-Mediated Demyelination/ Remyelination. ASN Neuro. 2014; 6(5): 1759091414551955. https://www.ncbi.nlm.nih.gov/pmc/articles/PMC4187018/
33. Goldberg J, Clarner T, Beyer C, Kipp M. Anatomical distribution of cuprizone-induced lesions in C57BL6mice. *J Mol Neurosc* 2015; 57(2):166-75. Sharma JN, Al-Omran A, Parvathy SS. Role of nitric oxide in inflammatory diseases. Inflammopharmacol 2007; 15(6):252–259.
34. Cook HT, Cattell V. Role of nitric oxide in immune-mediated diseases. *Clinical Science* 1996; 91(4): 375–384.
35. Mahindrakar YS, Thorat AP, Iyer CM. Oxidant and Antioxidant Status in Parkinson's Disease. *Indian Medical Gazette* 2014:195-202.
36. Abdel BNA, Zaidi ZF, Fatari JA, Sayed-Ahmed MM, Yakub H. Nitric oxide Pros and Cons: The role of L-arginine a nitric oxide precursor and ideborne, a co-enzyme Q analogue in ameliorating cerebral hypoxia in rat. *Brain Res Bull* 2010; 83(2): 49-56.
37. Sheikh A, Yeesmin F, Agarwal S, Rahman M, Islam K. Protective effects of *Moringa oleifera* Lam. leaves against arsenic-induced toxicity in mice. *Asian Pac J Trop Biomed* 2014; 4(1):S353-S358.
38. Bo L, Vedeler CA, Nyland HI, Trapp BD, Mork SJ. Subpial demyelination in the cerebral cortex of multiple sclerosis patients. *J Neuropathol Exp Neurol* 2003; 62(7):723–732.
39. Kutzelnigg A, Faber-Rod JC, Bauer J, Lucchinetti CF, Sorensen PS, Laursen H, *et al*. Widespread demyelination in the cerebellar cortex in multiple sclerosis. *Brain* Pathol. 2007; 17(1):38-44.

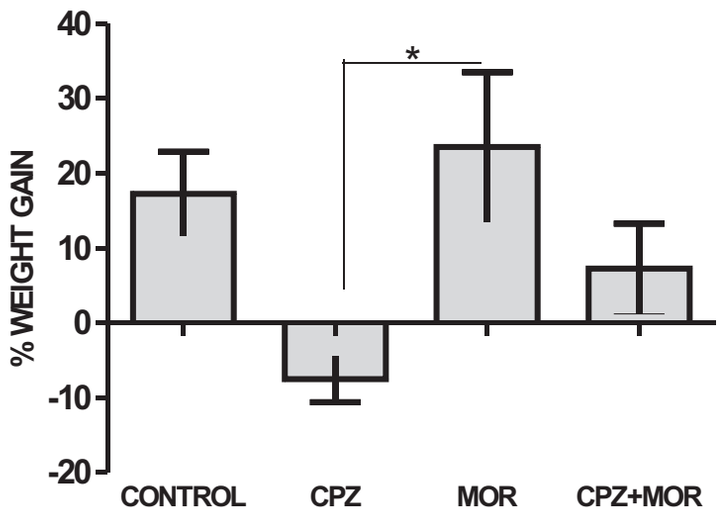

Figure 1: Percentage Body weight gain in Wistar rats. CPZ = Cuprizone, MOR = *Moringa oleifera*, CPZ + MOR = Cuprizone and *Moringa oleifera*. * is significant level of difference at $p<0.05$.

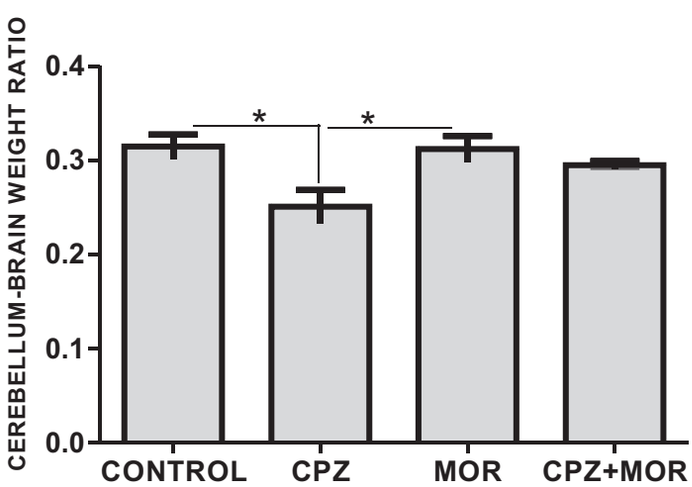

Figure 2: Cerebellum-brain weight ratio of Wistar rats. CPZ = Cuprizone, MOR =*Moringa oleifera*, CUP + MOR = Cuprizone and *Moringa oleifera*. * Significant difference ($p<0.05$).

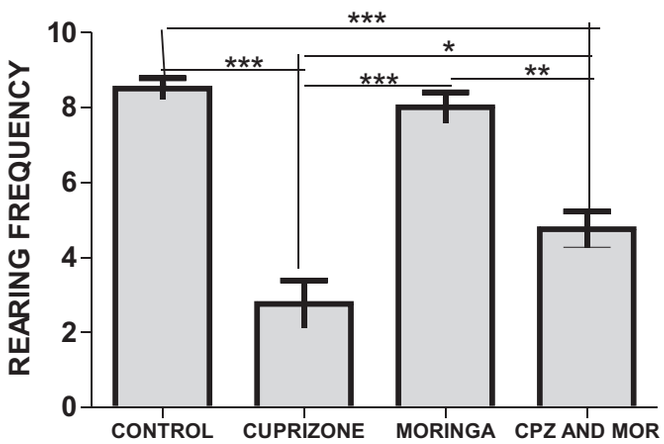

Figure 3: Open field test to show rearing frequency in all groups.
*, ** and *** are significant levels of difference at p<0.05, p<0.01 and p<0.005 respectively.
CPZ + MOR = Cuprizone and *Moringa*

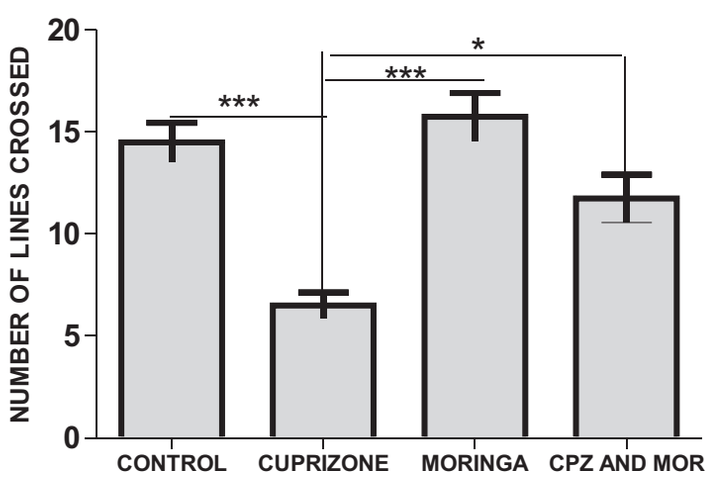

Figure 4: Open field test to show number of lines crossed in each group.
*, ** and *** are significant levels of difference at p<0.05, p<0.01 and p<0.005 respectively.
CPZ + MOR = Cuprizone and *Moringa*

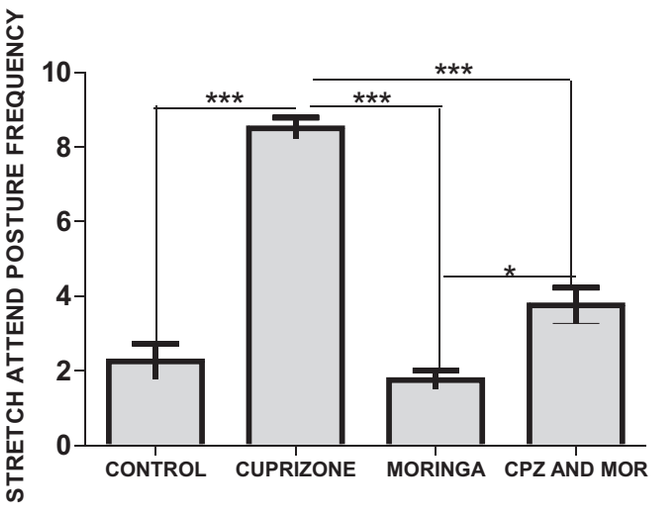

Figure 5: Open field test to show stretch attend frequency in each group.
CPZ + MOR = Cuprizone and *Moringa oleifera*.
* and *** are significant levels of difference at p<0.05 and p<0.005 respectively

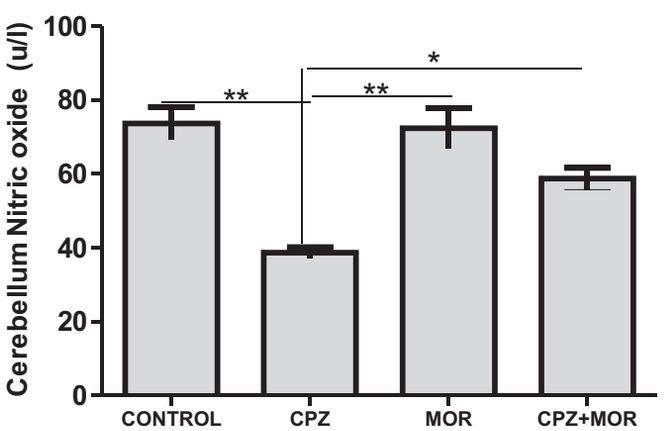

Figure 6: Activity of nitric oxide in the cerebellum of female Wistar rats.
CPZ = Cuprizone, MOR =*Moringa oleifera*, CPZ + MOR = Cuprizone and *Moringa oleifera*.
* and ** are significant levels of difference at p<0.05 and p<0.01 respectively

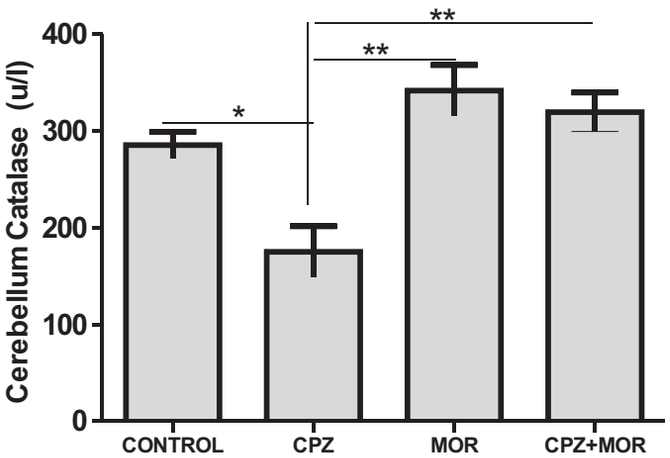

Figure 7: Activity of catalase in the cerebellum of female Wistar rats.
CPZ = Cuprizone, MOR =*Moringa oleifera*, CPZ + MOR = Cuprizone and *Moringa oleifera*.
* and ** are significant levels of difference at $p<0.05$ and $p<0.01$ respectively.

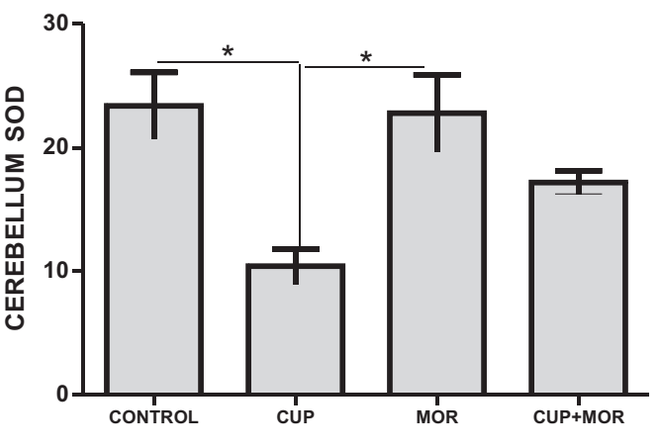

Figure 8: Activity of superoxide dismutase (SOD) in the cerebellum of Wistar rats.
CUP = Cuprizone, MOR =*Moringa oleifera*, CUP + MOR = Cuprizone and *Moringa oleifera*.
* Significant difference ($p<0.05$).

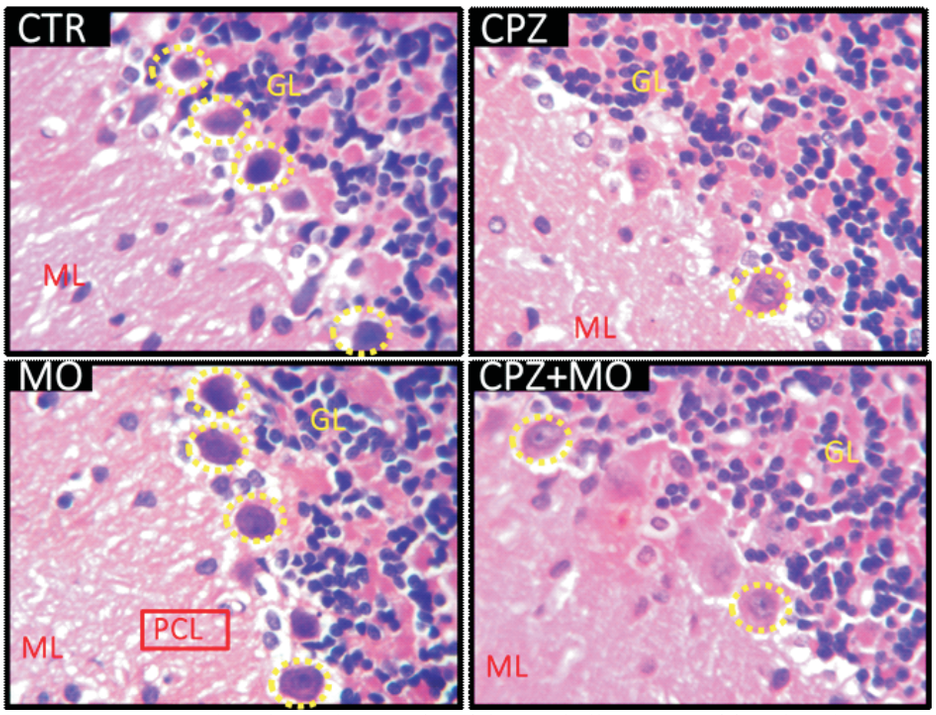

Figure 9: Representative photomicrographs of the cerebellar cortex of female Wistar rats showing the molecular layer (ML) Purkinje cells dotted (yellow circle) and the granular layer (GL).CTR and MO had densely packed and intensely stained granule cells within the granular layer, compared with CPZ and CPZ+MO sections. CTR=Control, CPZ=Cuprizone, MO=*Moringa oleifera* and CPZ + MO=Cuprizone and *Moringa*. H&E x400.

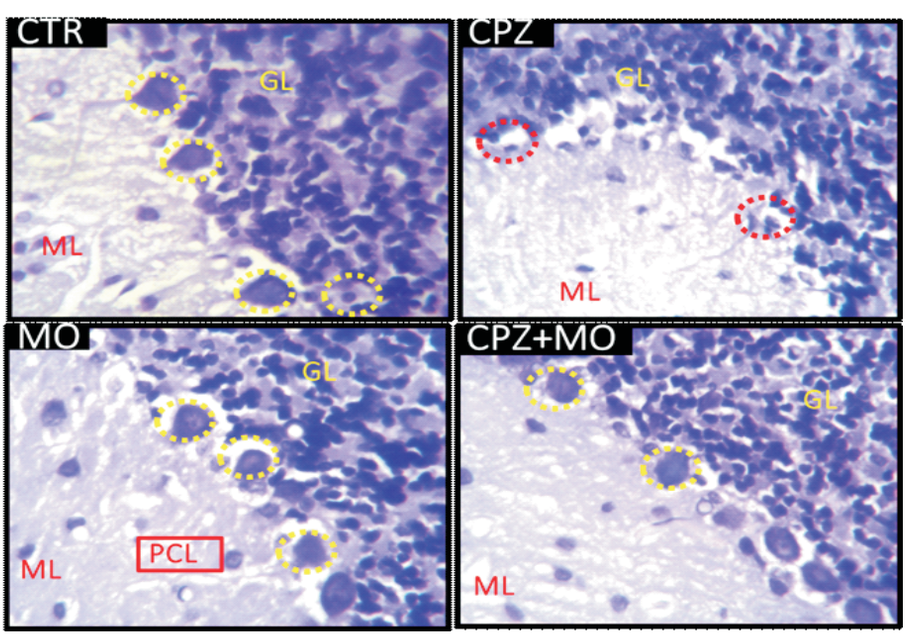

Figure 10: Representative photomicrograph to demonstrate Nissl bodies in the cerebellar cortex of Wistar rats. CTR and MO were more intensely stained compared with CPZ and CPZ+MO sections. In CPZ section, the Purkinje layer was irregular in outline and less populated with cells (red rings) compared with other sections, with the CPZ+MO group showing restored outline and Pukinje cell population (yellow rings). The molecular layer (ML) in CPZ group was sparsely populated with cells. CTR= Control CPZ=Cuprizone MO=*Moringa oleifera* and CPZ + MO=Cuprizone and *Moringa*. Cresyl fast violet x400.