Official Publication of
Society of Experimental and
Clinical Anatomists of Nigeria

Journal of Experimental & Clinical Anatomy

ISSN 1596-2393

VOL. 12 | Issue 2 | Jul-Dec 2013

Wolters Kluwer Health | Medknow

JECA

Original Article

Effects of albendazole administration on the testicular histology of adult Wistar rats

Gabriel O. O., Ade S.A., Oluwafemi A. O.[1]

Departments of Anatomy and [1]Physiology, Faculty of Basic Medical Sciences, College of Health Sciences, University of Ilorin, Ilorin, Nigeria

Abstract

Background: The testicular cytoarchitectural effects of albendazole administration were studied in adult Wistar rats. **Materials and Methods:** The animals were grouped into three groups, with six (6) rats per group. While animals in the control group A were given water, the treatment groups B and C received 15 mg/kg and 30 mg/kg respectively of albendazole orally for three consecutive days. The animals were sacrificed by cervical dislocation about 24 hours after drug administration, and the testes removed, fixed in 10% formal saline and processed for histological consideration, using Haematoxylin and Eosin stains. **Results:** Varying degrees of histological changes were noticed in the seminiferous tubules, which were marked in the group that received the higher dose of the drug. **Conclusion:** These structural distortions and degenerations of testicular tissues that occurred after albendazole administration are dose-dependent, and could affect reproductive functions in males.

Key words: Albendazole, histology, testes, Wistar rats

INTRODUCTION

Albendazole is an anthelminthic drug used in the treatment of many parasitic infestations (Chaurasia *et al.*, 2010, Cárdenas *et al.*, 2010). It is employed in the treatment of neurocysticercosis, a common cause of seizures in affected individuals, and is also capable of lowering the rate of seizure recurrence (Abba *et al.*, 2010). In patients with seizures due to viable parenchymal cysts, antiparasitic therapy decreases the burden of parasites and is safe and effective, at least in reducing the number of seizures with generalisation (Garcia *et al.*, 2004). In some localities, albendazole is the drug of choice in neurocysticercosis due to its low costs and availability, and parasite localisation (Cárdenas *et al.*, 2010).

According to the study by Critchley *et al.*, (2005), albendazole, in combination with ivermectin, has small effect on microfilaraemia in the treatment of lymphatic filariasis, but this was not consistently demonstrated. In children with neurocysticercosis, a combination therapy with albendazole and praziquantel showed greater resolution of lesions than sole albendazole treatment although seizure control was similar in both groups (Kaur *et al.*, 2009). Studies in animal models show that albendazole affects embryonic and foetal development when administered during pregnancy (Teruel *et al.*, 2009).

Very few studies are available on the effects of albendazole treatment on the reproductive organs. Studies in nematodes administered with sublethal dose of albendazole metabolites showed severe ultrastructural abnormalities in spermatogenic cells, which are reversible upon withdrawal of the drug (Osman *et al.*, 1994). The current study was aimed at determining the histological

Address for correspondence:
Dr. Gabriel O. Omotoso,
Department of Anatomy, Faculty of Basic Medical Sciences,
College of Health Sciences, University of Ilorin,
P.M.B. 1515, Ilorin, Nigeria.
E-mail: gabrielolaiya@yahoo.com

Access this article online	
Quick Response Code:	Website: www.jecajournal.org
	DOI: 10.4103/1596-2393.127957

alterations that exist in the testes of animal models administered with therapeutic doses of albendazole.

MATERIALS AND METHODS

Experimental Rats

Eighteen (18) adult male Wistar rats of mean weight 337.64 ± 10.17 g were used for the experiment. The animals were housed in individual cages and allowed to acclimatise prior to commencement of the experiment. They were kept under hygienic and favourable condition, and maintained under a 12 h light/12 h dark cycle, with feeds and water available *ad libitum*.

Experimental Design

The animals were randomly grouped into three (3), with six (6) rats in each group, as follows:

- Group A: Control, fed with rat pellets and water only
- Group B: received 15 mg/kg/d of albendazole
- Group C: received 30 mg/kg/d of albendazole.

Administration of Drug

Group A animals served as the control; they were given rat pellets and water only, while animals in the treatment groups B and C received 15 mg/kg/d and 30 mg/kg/d albendazole (100 mg/5 ml; procured from One-Step Pharmacy®, Ilorin, Nigeria), respectively. The drug was administered orally using a feeding tube and syringe, for three consecutive days (Chaurasia *et al*., 2010).

Animal Sacrifice and Sample Collection

The animals were sacrificed by cervical dislocation about 24 hours after completion of drug administration. The abdomen was dissected, and tissue specimens of the testes were removed and fixed in10% formal saline for histological processing, using the routine haematoxylin and eosin stains.

RESULTS

Histological Observation

The testes of the control experimental rats showed a normal cytoarchitecture, with well-outlined seminiferous tubules and interstitial spaces, with both spermatogenic and non-spermatogenic cells [Figure 1]. The cells of the spermatogenic series were at different stages of development, and the lumens were occupied with apparently normal and mature spermatozoa. The testicular histology of the animals given 15 mg/kg of albendazole revealed deeply stained structure, with a slight reduction in number of spermatogenic cells. The interstitial spaces appeared wider in thickness compared to those of the control group [Figure 2].

Photomicrograph of the testes of Wistar rats that received 30 mg/kg of albendazole showed loss of spermatogenic, non-spermatogenic (sustentacular cells) and interstitial cells, reduction in population of mature spermatozoa in the lumens of the seminiferous tubules and some degrees of disintegration of the cells [Figure 3].

DISCUSSION

Albendazole can be administered at a dose of 15 mg/kg or 30 mg/kg (Göngora-Rivera *et al*., 2006) for therapeutic purposes. It has been used extensively in the management of helminthic infections, solely or in combination with other anthelminthics. Most researchers have focused on its use in parasitic infestations with involvement of the central nervous

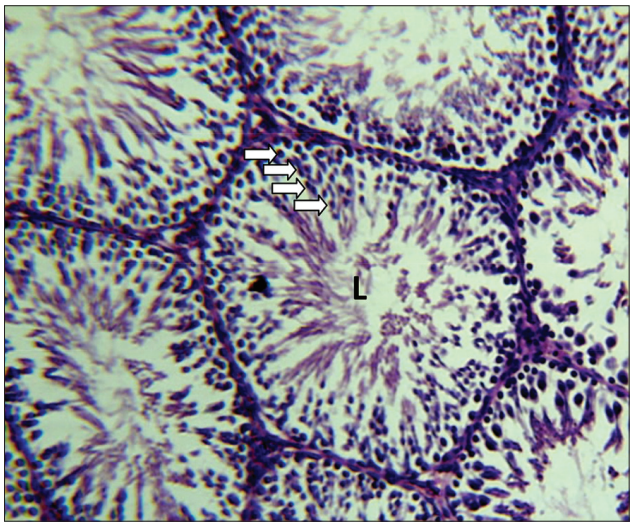

Figure 1: Photomicrograph of the testis of Wistar rats in the control group A showing apparently normal outline of the seminiferous tubules, interstitium and spermatogenic cells (arrows) at different stages of development, and lumens (L) with normal population of mature spermatozoa(H and E, x200)

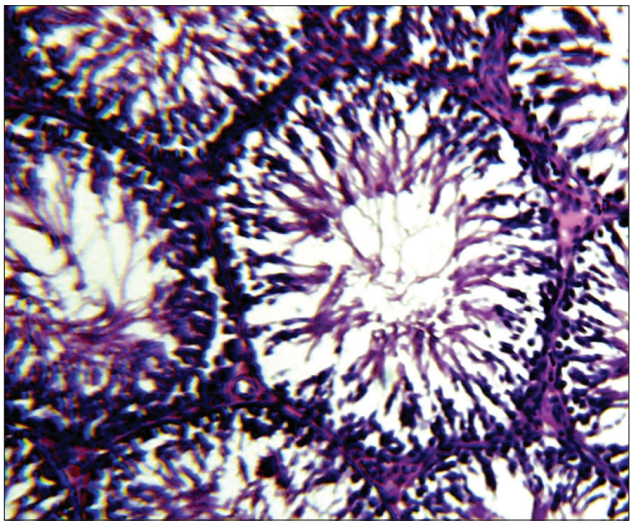

Figure 2: Photomicrograph of the testis of Wistar rats (group B) which received 15 mg/kg albendazole showing deeply stained microstructure and slight reduction in the population of spermatogenic cells. The interstitial spaces were wider than those of control animals (H and E, x200)

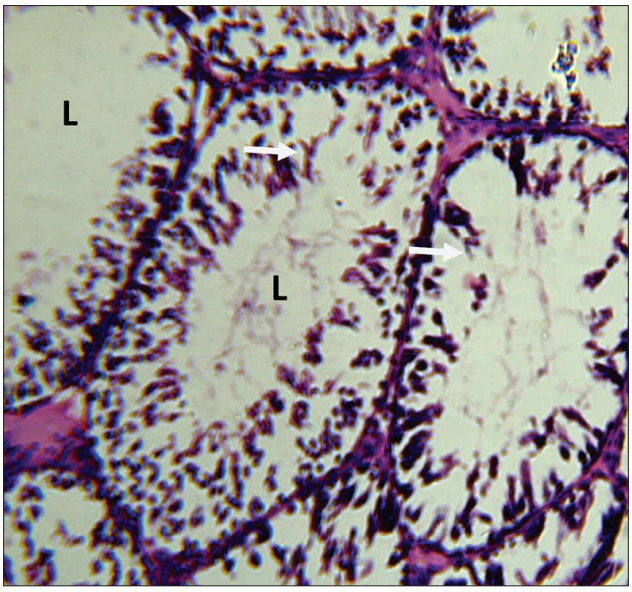

Figure 3: Photomicrograph of the testis of Wistar rats (group C) which received 30 mg/kg albendazole showing loss of spermatogenic cells, reduced density of mature spermatozoa within the lumens (L) of the seminiferous tubules, scanty supporting cells (arrows) and some degrees of disintegration and degeneration of the cells (H and E, x200)

system, such as neurocysticercosis. The implication of this drug on reproductive structures and functions is not well documented. In this histological evaluation of the testes in Wistar rats, various changes were noticed, that could compromise the testicular functions. These changes were especially marked in the testes of animals that received the higher dose of albendazole. Distortions of the architectural framework of the seminiferous tubules noticed in the high dose groups could be a result of the loss in sustentacular cells.

The mechanism whereby albendazole affects seminiferous tubules of the testis has not been clearly demonstrated or documented. However, the loss or reduction in the sustentacular cells, or any abnormalities arising from these cells, which are principally meant to support and nourish the developing spermatogenic cells, could be responsible for the reduction in number of the spermatogenic cells, the poor development of sperm cells, or degeneration of these cells. Hence, there is a possibility that most sperm cells do not develop to maturity before their eventual degeneration, when albendazole is used at a high dose. This, however, needs to be further proven, in order to ascertain more specifically the cause and mechanism of these changes.

The structural changes noticed in the interstitial spaces between the seminiferous tubules of treated animals could affect other structures within the interstitium, such as the connective tissue fibres and cells, and the neurovascular tissues; any compromise in the functions of these components would also affect the developing sperm cells and their functions. In conclusion, this histological study of the testes of Wistar rats revealed that higher doses of albendazole resulted in cytoarchitectural changes, which probably could affect testicular and reproductive functions in males.

REFERENCES

1. Abba K, Ramaratnam S, Ranganathan LN (2010). Anthelmintics for people with neurocysticercosis. Cochrane Database Syst Rev (3): CD000215.
2. Cárdenas G, Carrillo-Mezo R, Jung H, Sciutto E, Hernandez JL, Fleury A (2010). Subarachnoidal Neurocysticercosis non-responsive to cysticidal drugs: A case series. BMC Neurol 10: 16.
3. Chaurasia RN, Garg RK, Agarwall A, Kohli N, Verma R, Singh MK, *et al*. (2010). Three day albendazole therapy in patients with a solitary cysticercus granuloma: A randomized double blind placebo controlled study. Southeast Asian J Trop Med Public Health 41 (3): 517-25.
4. Critchley J, Addiss D, Gamble C, Garner P, Gelband H, Ejere H (2005). Albendazole for lymphatic filariasis. Cochrane Database Syst Rev (4): CD003753.
5. Garcia HH, Pretell EJ, Gilman RH, Martinez SM, Moulton LH, Del Brutto OH, *et al*. (2004). A trial of antiparasitic treatment to reduce the rate of seizures due to cerebral cysticercosis. N Engl J Med 350(3):249-58.
6. Göngora-Rivera F, Soto-Hernández JL, González Esquivel D, Cook HJ, Márquez-Caraveo C, Hernández Dávila R, *et al*. (2006). Albendazole trial at 15 or 30 mg/kg/day for subarachnoid and intraventricular cysticercosis. Neurology 66(3):436-8.
7. Kaur S, Singhi P, Singhi S, Khandelwal N (2009). Combination therapy with albendazole and praziquantel versus albendazole alone in children with seizures and single lesion neurocysticercosis: A randomized, placebo-controlled double blind trial. Pediatr Infect Dis J 28(5):403-6.
8. Osman AM, Jacobs DE, Plummer JM (1994). *In vivo* effect of sublethal concentrations of albendazole metabolites on the structure of the reproductive organs of Dictyocaulus viviparus. J Helminthol 68(2):161-6.
9. Teruel M, García V, Catalano R (2009). Effects of albendazole sulphoxide on embryonic, foetal and placental parameters in Wistar rats. Int J Morphol 27(4):1147-53.

How to cite this article: Gabriel OO, Ade SA, Oluwafemi AO. Effects of albendazole administration on the testicular histology of adult Wistar rats. J Exp Clin Anat 2013;12:50-2.

Source of Support: Nil, **Conflict of Interest:** None declared.