**ORIGINAL ARTICLE**

Official Journal of the
Neuroscience Society of Nigeria
(NSN)

ISSN 1116-4182

# *Moringa oleifera* IS PROTECTIVE AGAINST MICROARCHITECTURAL AND NEUROCHEMICAL CHANGES ASSOCIATED WITH CUPRIZONE-INDUCED PREFRONTAL CORTEX NEUROTOXICITY IN FEMALE WISTAR RATS

**Gabriel O. Omotoso[1], Ismail T. Gbadamosi[1], Adelaja A. Akinlolu[1], Mubarak O. Ameen[2], Risikat E. Kadir[1], Rukayat Jaji-Sulaimon[1], Ahmad B. Abdulwahab[1], Rhoda M. Kolo[1]**

[1]Department of Anatomy, Faculty of Basic Medical Sciences, University of Ilorin, Ilorin, Nigeria
[2]Department of Chemistry, Faculty of Physical Sciences, University of Ilorin, Ilorin, Nigeria

***Received: ……. January 2018***
***Accepted: ……. May 2018***

## ABSTRACT

Cuprizone administration causes selective damage to axonal myelin sheath and has been used to model demyelinating diseases in neuroscience research. This study aimed at determining the protective effects of *Moringa oleifera* on cuprizone-induced neurotoxicity in the prefrontal cortex (PFC). Sixteen adult female Wistar rats were procured and grouped into 4: Group A was given normal saline, Group B received 0.4% cuprizone diet, Group C was administered with 1.875 mg/ml of *Moringa oleifera* and Group D received a combination of 0.4% cuprizone diet and 1.875 mg/ml of *Moringa oleifera*. All the groups were treated orally for 35 consecutive days after which they were sacrificed. Thereafter the PFC was processed for histological demonstration, while tissue homogenate was used to assay the activity of superoxide dismutase (SOD). Cuprizone administration caused significant reduction in body weight and SOD activities. It also caused an alteration in the microarchitecture and Nissl profile of the PFC. *Moringa oleifera* intervention led to restoration of body weight, SOD levels, Nissl profile and the histology of the PFC. The use of preparations of *Moringa oleifera*, especially the leaf-component, could offer some protective measures to individuals suffering from demyelinating conditions, especially in addressing the associated weight changes and frontocortical dysfunction.

**Key words:** *Cuprizone, Demyelination, Moringa oleifera, Weight, Prefrontal cortex*

## INTRODUCTION

Neurotoxins are chemical substances that are destructive to nervous tissues thereby affecting different parts of the nervous system (Adams and Olivera 1994). The injury, depending on the extent, affects various cellular components, processes and functions, with distinct phenotypic manifestations. Cuprizone (CPZ) is a copper chelator, with selective toxicity against oligodendrocytes, which are responsible for the production of myelin in the central nervous system (Taylor et al. 2010). This activity leads to destruction of myelin sheaths that encapsulate the axons of neurons, thereby adversely affecting neuronal morphology and functions, including axonal impulse conduction and metabolic processes, resulting in different forms of demyelinating conditions, the commonest of which is multiple sclerosis (MS) (Chari 2007). Although the

Correspondence: Gabriel O. Omotoso, Ph.D., Department of Anatomy, Faculty of Basic Medical Sciences, University of Ilorin, P.M.B. 1515, Ilorin, Nigeria, E-mail: omotoso.go@unilorin.edu.ng, +2347030505707

blood-brain barrier (BBB) in the CPZ model is kept intact with no evidence of T cell infiltration, extensive activation of macrophages and microglial are obvious (Bakker and Ludwin 1987; McMahon et al. 2002; Hillis et al. 2016). Dietary CPZ administration is a method that is well-characterized and reliable, and is used in studying de- and re-myelination processes involved in demyelinating diseases (Franco-Pons et al. 2007). The withdrawal of CPZ from the diet allows endogenous re-myelination (Hillis et al. 2016), hence its suitability in studying the re-myelination process.

*Moringa oleifera* leaf is frequently used in traditional medicine in many cultures due to its acclaimed health benefits. It has been used in the management of many clinical conditions due to its various properties, which include: anti-tumour, antipyretic, antiepileptic, anti- inflammatory, antihypertensive, antioxidant, anti-diabetic, anti-bacterial, antifungal and hepatoprotective activities, amongst many others (Pal et al. 1995; Guevara et al. 1999; Shih et al. 2011; AbdEl-Rahman et al. 2015).

Clinical assessment of the frontal lobe revealed transient neurological deficits in several young patients with multiple sclerosis (Mendozzi et al. 1993), hence, this study aimed to characterize the histomorphological and biochemical changes in the prefrontal cortex of Wistar rats following treatment with CPZ diet and *Moringa oleifera*.

## MATERIALS AND METHODS

### Experimental Animals

All protocols and treatment procedures were done according to the Institutional Animal Care and Use Committee (IACUC) guidelines and as approved by the Faculty of Basic Medical Sciences, University of Ilorin, Nigeria.

A total of 16 female Wistar rats (*Rattus norvegicus*) with an average weight of 163.74 ± 3.59 g were purchased from a private animal holding and kept under standard laboratory conditions in the Animal House of the Faculty of Basic Medical Sciences, University of Ilorin, Nigeria. They were fed with pelletized feed and grower's mash which were purchased from Ogo-Oluwa Feed and Flour Mill Limited, Sango, Ilorin. The rats were provided with tap water *ad libitum*.

### Reagent Preparation and Treatment Regimen

Cuprizone (99%) was purchased from Sigma-Aldrich®, Germany (C9012-25G), and prepared at a dose of 400 mg CPZ in 100 g of rat feed (0.4% CPZ diet), (Stidworthy et al. 2003). The fresh leaves of *Moringa oleifera* were collected in Ilorin, Kwara State and identified at the Herbarium of the Department of Plant Biology, University of Ilorin, where a voucher specimen with a voucher number UILH/001/1008 was deposited. Fractionation of the ethanolic extract of the leaves of the plant was carried out using the silica gel open column method at the Department of Chemistry, University of Ilorin, Nigeria. Column chromatography was carried out on 798 g concentrate of *Moringa oleifera*, followed by thin layer chromatography. In all, seven fractions were obtained, out of which only one was used. The fraction used had a yield of 10.86 g of the extract, making 1.36%.

The rats were divided into four groups A, B, C and D, each consisting of four rats. Group A was administered 1 ml of distilled water, Group B received 0.4% CPZ diet, Group C received 1.875 mg/ml of *Moringa oleifera* leaf extract, while Group D was administered with a combination of 0.4% CPZ diet and 1.875 mg/ml of *Moringa oleifera*. Treatment of animals was by the use of an oral cannula for 35 consecutive days during which CPZ toxicity would have been achieved (Zhen et al. 2017).

### Animal Sacrifice and Tissue Processing

Twenty-four hours following termination of experiment, the animals were sacrificed by cervical dislocation. The animals were decapitated and the brain tissues were carefully excised and weighed. The prefrontal cortex was stereotaxically excised and weighed. The right PFC was fixed in 4% paraformaldehyde (PFA). Histological staining was carried out in paraffin embedded sections (following the method of Canene-Adams 2013). Thin sections from paraffin embedded tissues were processed histologically (Hematoxylin and Eosin stain) and histochemically (Cresyl fast violet stain) using the methods described by Fischer et al. (2008) and Kádár et al. (2009) respectively. The left PFC of each animal was obtained and pulverized in 0.25 M sucrose with the aid of an automated homogenizer at 4ºC. Lysates from the brain were centrifuged for 10 min at 12,000 rpm to obtain the supernatant comprising organelle synaptosomes. The supernatants were aspirated into plain labelled glass cuvette placed in ice. SOD activity was assayed using SOD lysate immunosorbent assay kit procured from Bio Legend Inc., San Diego, CA, USA.

### Light Microscopy and Data Analysis

PFC sections were mounted on glass slides and captured using Olympus binocular research microscope (Olympus, New Jersey, USA), connected to a 5.0 MP Amscope Camera (Amscope Inc, USA.). The percentage change in body weight, relative PFC weight and SOD outcomes were plotted using one way ANOVA with Tukey's multiple comparisons test. Significance was set at $p < 0.05$, $p < 0.01$, $p < 0.005$. The outcomes were represented in bar charts with error bars to show the mean and standard error of mean respectively.

## RESULTS

### Morphological Observations

The body weights of the Wistar rats were obtained on the first day and last day of treatment as the initial and final weights respectively. The percentage weight gain was estimated as the ratio of weight gain to the initial weight multiplied by 100. The animals in the CPZ group had a significantly low percentage weight

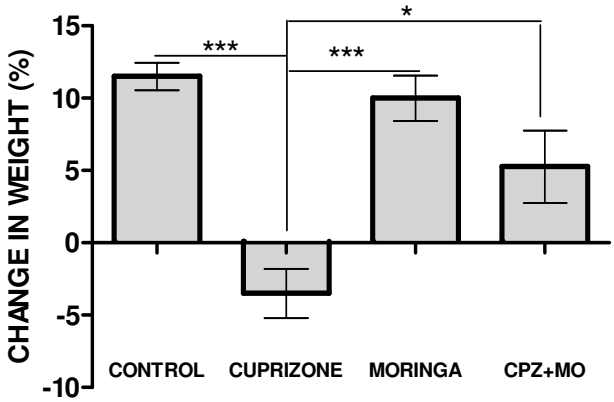


**Figure 1: Percentage change in weight of experimental animals across the groups**. The cuprizone group had a significant reduction in body weight relative to the control ($p < 0.005$), *Moringa* ($p < 0.005$) and CPZ+MO group ($p < 0.05$). * and *** are significant values at $p < 0.05$ and 0.005 respectively.

loss relative to the control and *Moringa oleifera* groups ($p < 0.005$ for both). This finding suggested that CPZ caused a reduction in the body weight of the Wistar rats treated with CPZ alone. Post-treatment of animals with MO helped the Wistar rats to normalize their body weight as it was observed that the percentage increase in the body weight of animals treated with both CPZ and *Moringa oleifera* was significantly higher than that of the CPZ rats ($p < 0.05$). There was no significant difference in the

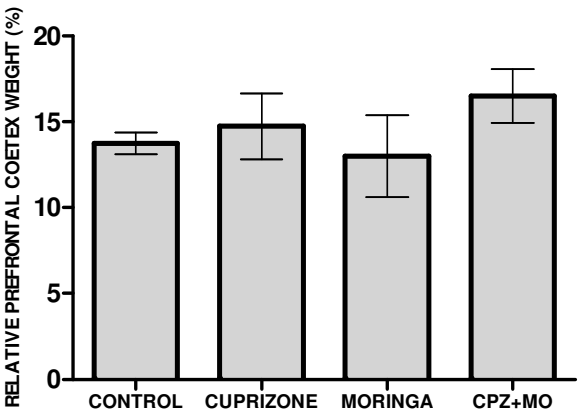


**Figure 2: Weight of the prefrontal cortex relative to the brain weight of experimental animals**. There was no significant difference across the experimental groups ($p < 0.05$).

percentage weight gain of the control group relative to the *Moringa oleifera* group ($p > 0.05$) (Figure 1). When the brains of the Wistar rats were excised, they were weighed and dissected to obtain the PFC. The relative PFC weight was obtained as a ratio of the PFC weight to the whole brain weight. There was no significant difference in the relative brain weight of the experimental animals across the four groups ($p > 0.05$) (Figure 2).

### *Moringa oleifera* Suppresses Cuprizone-Induced Oxidative Stress

In the present study, we assayed for the activities of superoxide dismutase to quantify the height of generation of singlet and reactive oxygen species within the PFC of the Wistar rats. In the CPZ group, CPZ activities induced a reduction in the level of SOD relative to the control group ($p < 0.005$) and *Moringa oleifera*-treated rats ($p < 0.01$). Wistar rats treated with a combination of *Moringa oleifera* and CPZ diet had a significantly higher SOD level relative to the CPZ group ($p < 0.005$) and lower SOD levels compared to the *Moringa oleifera*-treated rats ($p < 0.01$). There was no significant difference in the SOD levels of the control group when compared to the rats treated with *Moringa oleifera* ($p > 0.05$) (Figure 3).

### Histological and Histochemical Findings

Thin sections of the PFC were studied

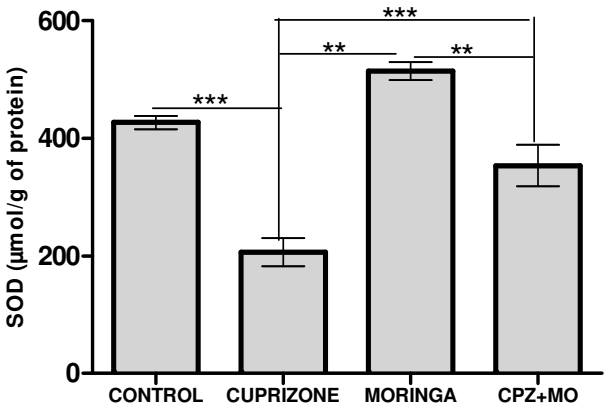


**Figure 3: Superoxide dismutase activities in the PFC.** CPZ+MO= cuprizone plus *Moringa*. ** and *** are significant values at $p < 0.01$ and 0.005 respectively.

qualitatively using Hematoxylin and Eosin, and Cresyl Fast Violet stains to characterize histopathological changes. High power magnification of the dorsolateral prefrontal cortex of the control group and *Moringa oleifera*-treated rats had similar histomorphological presentations. The pyramidal neurons in the external pyramidal layer of this region appeared normal with large soma and neural processes all properly seated within their respective

neuropils surrounded by supporting cells. The cellular density appeared characteristically normal with typical distribution of neuronal and non-neuronal cells. The histochemical manifestation of pyramidal cells showed intensely stained Nissl substances, suggesting healthy and intact neuronal morphology.

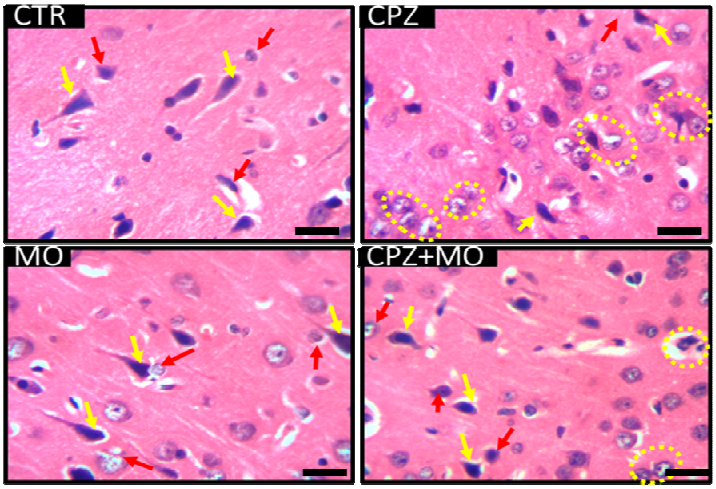


**Figure 4: Representative photomicrographs of the external pyramidal layer of the dorsolateral prefrontal cortex of Wistar rats**. CTR=control, MO= *Moringa*, CPZ=cuprizone. The control group and *Moringa*-treated rats presented with large pyramidal neurons with large soma and adjoining axons (yellow arrow). The nuclei of pyramidal cells and supporting cells (red arrows) were deeply stained. CPZ-treated rats presented with pyknotic changes as the pyramidal and supporting cells were arranged in clusters (dotted yellow circles). CPZ+MO-treated rats presented with an external pyramidal layer that was characteristically similar to those of the control group and *Moringa* groups. H&E stain. Scale bar= 25µ

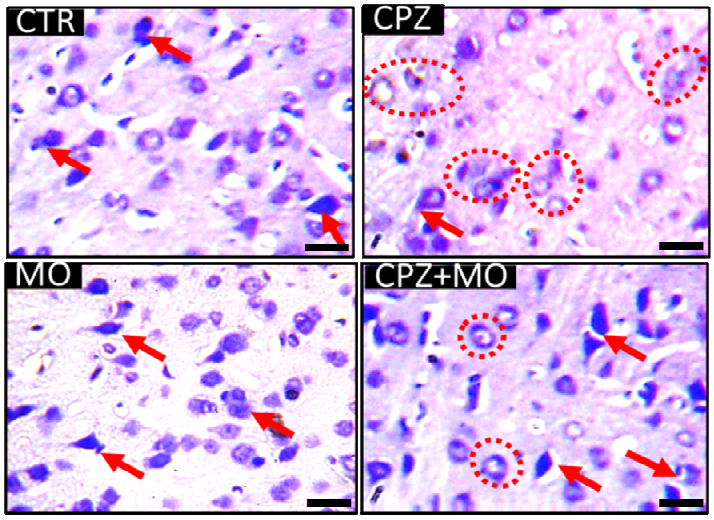


**Figure 5: Representative photomicrographs of the dorsolateral PFC showing the Nissl substance of the neuronal cells in the external pyramidal layer.** CTR= control, CPZ= cuprizone and MO= *Moringa oleifera*. CTR and MO presented with large pyramidal neurons (red arrows) with intensely stained Nissl substance. CPZ group presented with clusters of chromatolytic pyramidal neurons (red circles- broken lines), while CPZ+MO treated rats presented with characteristically stained large pyramidal neuron with few poorly stained pyramidal cells (small red circles-broken lines). Cresyl fast violet stain; Scale bar= 25µ

Animals treated with CPZ only presented with degenerative changes within the PFC. The neuronal and supporting cells appeared in pyknotic clusters with fragmented neuropils and degenerated neural processes. The cells also presented with mild chromatolysis using the Nissl staining techniques which suggested that CPZ compromised cellular integrity and histomorphology of the PFC of Wistar rats. *Moringa oleifera* intervention significantly restored the histomorphological integrity of the PFC. Rats that received this treatment regimen (CPZ+ *Moringa oleifera*) presented with typical cellular distribution within the PFC. The pyramidal cells appeared with large soma and intensely stained Nissl substances (Figures 4 and 5).

## DISCUSSION

In the present study, we evaluated the role of *Moringa oleifera* on CPZ -induced reduction in body weight, oxidative stress, microarchitectural distortion and chromatolysis in the prefrontal cortex. CPZ caused a significant loss in the body weight but had no effect on the weight of the frontal cortices of the experimental animals. This finding suggests that CPZ raised the basal metabolic rate of the animals treated with CPZ thereby causing such animals to use or burn more adipose tissues compared to animals in the other experimental group. The use of CPZ for the induction of CNS demyelination is usually accompanied by other effects outside myelin metabolism. As observed from earlier studies (Steelman et al. 2012), reduction in body weight is often associated with CPZ ingestion; however, simultaneous treatment with *Moringa oleifera as used in the current work helped the animals* to gain and sustain their body weights. Several studies have shown that *Moringa oleifera* is used as food supplement in certain parts of the world (Paul et al. 2013). Some evidences have implicated excessive singlet and triplet generation in the pathogenesis of multiple sclerosis (Lucchinetti et al. 2000; Lassmann 2010). The excessive generation of these reactive species results into oxidative stress. In the present study, the activity of SOD was quantified to access the antioxidant status of the PFC. SOD is an enzyme that is in the frontline of defense against oxidative stress. It catalyzes the conversion of highly reactive superoxide to less reactive hydrogen peroxide which is then broken down into water and oxygen molecule

by the action of catalase. CPZ depleted the level of SOD in the PFC of animals treated with CPZ, thereby compromising the intrinsic antioxidant system. This finding suggests that CPZ induced a superfluous generation of reactive oxygen species (ROS) which cannot be catered for by the intrinsic antioxidant defense system. Other authors have earlier observed this also (Acs et al. 2009; Kashani et al. 2014). The excess ROS will compromise the integrity of the neuronal and non-neuronal cells by exacerbating lipid peroxidation. Lipid peroxidation results from oxidative degradation of lipids and involves the removal of electrons from the lipid cell membrane by ROS (Sen et al., 2009). Lipid peroxidation leads to compromised cell membranes and cellular damage (Halliwell and Gutteridge 1984).

Qualitative analysis of thin sections of the PFC in animals treated with CPZ revealed pathological alterations. We observed degenerative changes in the pyramidal cells of the external pyramidal layer of the dorsolateral prefrontal cortex. Some of these cells appeared with fragmented neuropils with degenerated cellular processes while others appeared in pyknotic cluster of darkly stained neurons. These degenerative changes can be attributed to the reduction in SOD level which compromised the integrity of the intrinsic antioxidant system thereby increasing the oxygen scavenging activity of reactive species from the lipid bilayer of cells in the PFC. CPZ further compromised the integrity of the Nissl profile of the pyramidal cell as we observed chromatolysis in these cells.

Treating the animals with *Moringa oleifera* leaf extract significantly reversed the pathological alteration induced by CPZ. *Moringa oleifera* was able to normalize the level of SOD in the PFC of the experimental animals thereby ameliorating the rate of lipid peroxidation. This, *Moringa oleifera* was able to do this either by acting as an antioxidant in its own capacity or initiating a cascade of chemical events that will ultimately result in the generation of more SOD. The leaves of *Moringa oleifera* are rich in flavonoids which are phenolic substances with antioxidant properties exerted by scavenging or quenching free radicals, chelating metal ions, or inhibiting enzymatic systems responsible for free radical generation (Sharida et al. 2012). We have recently reported that MO has neuroprotective properties both in the frontal cortex and cerebellum (Gbadamosi et al. 2016; Omotoso et al. 2017).

## CONCLUSION

Owing to CPZ-induced oxidative stress, weight loss, microarchitectural distortion and chromatolysis of PFC, *Moringa oleifera* can, as an economical therapeutic agent, reverse the detrimental effect of CPZ by scavenging reactive species or inhibiting free radical generation. *Moringa oleifera* therefore has a potential use in the development of efficacious therapy in multiple sclerosis management.

**Conflict of Interest**

None declared.

## REFERENCES

AbdEl-Rahman, M., Soliman, A. S., Morsi, M. K. S. and Mehrez, A. M. A. (2015) Hepatoprotective effect of ellagic acid rich extract of *Moringa oleifera* leaves on the CCl4 intoxicated rats. International Journal of Life Sciences Research. 3(3):91-99.

Acs, P., Kipp, M., Norkute, A., Johann, S., Clarner, T., Braun, A., Berente, Z., Komoly, S. and Beyer, C. (2009) 17-β estradiol and progesterone prevent cuprizone provoked demyelination of corpus callosum in male mice. Glia. 57:807-814.

Adams, M. E. and Olivera, B. M. (1994) Neurotoxins: Overview of an emerging research technology. Trends in Neuroscience. 17(4):151-155.

Bakker, D. A. and Ludwin, S. K. (1987) Blood-brain barrier permeability during cuprizone-induced demyelination: Implications for the pathogenesis of immune-mediated demyelinating diseases. Journal of Neurological Sciences. 78:125-137.

Canene-Adams, K. (2013) Preparation of formalin-fixed paraffin-embedded tissue for immunohistochemistry. Methods in Enzymology. 533:225-233.

Chari, D. M. (2007) Remyelination in multiple sclerosis. International Review of Neurobiology 79:589-620.

Fischer, A. H., Jacobson, K. A., Rose, J. and Zeller, R. (2008) Hematoxylin and eosin staining of tissue and cell sections. Cold Spring Harbour Protocols. doi:10.1101/pdb.prot4986.

Franco-Pons, N., Torrente, M., Colomina, M. T. and Vilella, E. (2007) Behavioral deficits in the cuprizone-induced murine model of demyelination/remyelination. Toxicology Letters. 169:205-213.

Gbadamosi, I. T., Omotoso, G. O., Olajide, O. J., Dada-Habeeb, S. O., Arogundade, T. T., Lambe, E. and Obasi, K. K. (2016) Moringa protects against nicotine-induced morphological and oxidative damage in the frontal cortex of Wistar rats. Anatomy. 10:170-176.

Guevara, A. P., Vargas, C., Sakurai, H., Fujiwara, Y., Hashimoto, K. (1999) An anti-tumor promoter from *Moringa oleifera* Lam. Mutation Research/Genetic Toxicology and Environmental Mutagenesis. 440:181-188.

Halliwell, B., and Gutteridge, J. M. (1984) Free radicals, lipid peroxidation, and cell damage. Lancet 2(8411):1095.

Hillis, J. M., Davies, J., Mundim, M. V., Al-Dalahmah, O. and Szele, F. G. (2016) Cuprizone demyelination induces a unique inflammatory response in the

subventricular zone. Journal of Neuroinflammation. 13:190. https://doi.org/10.1186/s12974-016-0651-2.

Kádár, A., Wittmann, G., Liposits, Z. and Fekete, C. (2009) Improved method for combination of immunocytochemistry and Nissl staining. Journal of Neuroscience Methods. 184:115-118.

Kashani, I. R., Rajabi, Z., Akbari, M., Hassanzadeh, G., Mohseni, A., Eramsadati, M. K. (2014) Protective effects of melatonin against mitochondrial injury in a mouse model of multiple sclerosis. Experimental Brain Research. 232:2835-2846.

Lassmann, H. (2010) What drives disease in multiple sclerosis: inflammation or neurodegeneration? Clinical and Experimental Neuroimmunology 1(1):2-11.

Lucchinetti, C., Bruck, W., Parisi, J., Scheithauer, B., Rodriguez, M. and Lassmann, H. (2000) Heterogeneity of multiple sclerosis lesions: implications for the pathogenesis of demyelination. Annals of Neurology. 47(6):707-717.

McMahon, E. J., Suzuki, K. and Matsushima, G. K. (2002) Peripheral macrophage recruitment in cuprizone-induced CNS demyelination despite an intact blood-brain barrier. Journal of Neuroimmunology. 130:32-45.

Mendozzi, L., Pugnetti, L., Saccani, M. and Motta, A. (1993) Frontal lobe dysfunction in multiple sclerosis as assessed by means of Lurian tasks: effect of age at onset. Journal of Neurological Sciences. 115:S42-S50.

Omotoso, G. O., Gbadamosi, I. T., Olajide, O. J., Dada-Habeeb, S. O., Arogundade, T. T. and Yawson, E. O. (2017) *Moringa oleifera* phytochemicals protect the brain against experimental nicotine-induced neurobehavioral disturbances and cerebellar degeneration. Pathophysiology 25:57-62.

Pal, S. K., Mukherjee, P. K., Saha, K., Pal, M. and Saha, B. P. (1995) Antimicrobial action of the leaf extracts of Moringa oleifera Lam. Ancient Science of Life 14:197-199.

Paul, L. T., Fowler, L. A., Barry, R. J., and Watts, S. A. (2013) Evaluation of Moringa oleifera as a dietary supplement on growth and reproductive performance in Zebrafish. Journal of Nutritional Ecology and Food Research. 1(4):322-328.

Sen, S., Chakraborty, R., De, B. and Mazumder, J. (2009) Plants and phytochemicals for peptic ulcer: An overview. Pharmacognosy Review. 3(6):270-279.

Sharida, F., Syazana, A.S. and Palanisamy, A. (2012) Moringa *oleifera* hydroethanolic extracts effectively alleviate acetaminophen-induced hepatotoxicity in experimental rats through their antioxidant nature. Molecules. 17:8334-8350.

Shih, M. C., Chang, C. M., Kang, S. M. and Tsai, M. L. (2011) Effect of different parts (leaf, stem and stalk) and seasons (summer and winter) on the chemical compositions and antioxidant activity of Moringa oleifera. International Journal of Molecular Sciences. 12:6077-6088.

Steelman, A. J., Thompson, J. P. and Li, J. (2012) Demyelination and remyelination in anatomically distinct regions of the corpus callosum following cuprizone intoxication. Neuroscience Research. 72(1):32-42.

Stidworthy, M. F., Genoud, S., Suter, U., Mantei, N. and Franklin, R. J. (2003) Quantifying the early stages of remyelination following cuprizone-induced demyelination. Brain Pathology. 13(3):329-339.

Taylor, L. C., Puranam, K., Gilmore, W., Ting, J. P. Y. and Matsushima, G. K. (2010) 17 β-estradiol protects male mice from cuprizone-induced demyelination and oligodendrocyte loss. Neurobiology of Disease. 39(2):127-137.

Zhen, W., Liu, A., Lu, J., Zhang, W., Tattersall, D. and Wang, J. (2017) An alternative cuprizone-induced demyelination and remyelination mouse model. American Society for Neurochemistry Neuro. 9(4): doi: 10.1177/1759091417725174.

© Copyright Nigerian Journal of Neuroscience. All rights reserved.