CONTENTS

Volume 32 Number 2, April, 2025

Editorial comments ____ v

Original articles

Prevalence of Hepatitis B Virus Infection among Attendees of Antenatal Care Clinics at Primary Health Care Centres in North-Central, Nigeria
A.R. Yusuf, O.I. Musa. A.A. Yusuf, A.T. Adebayo-Ayanda ____ 01
https://dx.doi.org/10.4314/tjhc.v32i2.1

Assessment of prescription quality and incidence of drug therapy problems among patients in selected primary health facilities in Maiduguri metropolitan area, Borno State
P.O. Onah ____ 11
https://dx.doi.org/10.4314/tjhc.v32i2.2

A Survey of knowledge and perception of surrogacy among health care providers in selected institutions in Ilorin
S. M. Gwadabe, A.O Olarinoye, L.O. Omokanye, H.O. Raji, K.T. Adesina, M.A. Musa, A Ibrahim, A.O. Abdulmussawir, M. Ijaiya, S.T Suleiman. ____ 19
https://dx.doi.org/10.4314/tjhc.v32i2.3

Newbouldia Laevis Enhanced Bcl-2 Expression and Germinal Epithelial Proliferation in adolescent Wistar rats
M.Y. Adana, A.D. Adebayo, S.A. Aina, Q.R. Nathan, O.G. Onigbolabi, M.S. Ajao ____ 25
https://dx.doi.org/10.4314/tjhc.v32i2.4

Sub-Acute Toxicological Evaluation of An Artemesia-Based Moringa Supplement (AMS)
S.O. Afolabi, O.E. Olorundare, O.B. Akanbi, M.K. Bello, J.T. Folahan and S. Ibiyemi ____ 32
https://dx.doi.org/10.4314/tjhc.v32i2.5

Ameliorative Effects of Nigella Sativa Oil on Permethrin-Induced Neurotoxicity in the Cerebellum of Male Wistar Rats
F. S. Lewu, J. A. Adediji, I. A. Bolarinwa, R. A. Adeyemo, B. O. Ojo, L. T. Omoboye, G. O. Omotoso. ____ 39
https://dx.doi.org/10.4314/tjhc.v32i2.6

Review Article

Review of *Plasmodium vivax* Malaria in Indonesia and Malaysia: Epidemiology of The Infection and The Presence of The Vector Across Time
L. Handayani, I. Fitriani ____ 47
https://dx.doi.org/10.4314/tjhc.v32i2.7

CamScanner

Original Article

Newbouldia Laevis Enhanced Bcl-2 Expression and Germinal Epithelial Proliferation in adolescent Wistar rats

M.Y. Adana, A.D. Adebayo, S.A. Aina, Q.R. Nathan, O.G. Onigbolabi, M.S. Ajao

Department of Anatomy, Faculty of Basic Medical Sciences,
College of Health Sciences, University of Ilorin, Ilorin, Nigeria

Abstract

Background: In traditional medicine, numerous plant extracts have been used as infertility treatments to enhance chances of procreation over the years. The use of Newbouldia laevis as an adjuvant has been shown in experimental animal models to have the ability to either stimulate or suppress male reproductive processes at specific dosages. This study aimed to compare the effects of graded dosages of Newbouldia laevis and zinc on male fertility.

Materials and Methods: Thirty-six male adolescent Wistar rats, weighing between 55 - 125 g were randomly divided into six groups of five rats each. They were treated with normal saline, Zinc, and *Newbouldia laevis* at different doses and duration, viz: low-dose short-term (LS) and high-dose short-term (HS) for a period of 28 days, and low-dose long-term (LL), and high-dose long-term (HL) for of 56 days. The semen parameters, histomorphometric analysis, and Bcl-2 expression, a protein that controls apoptosis, were studied to assess the testicular health in experimental animals.

Results: The results demonstrated that high doses of *Newbouldia laevis* impaired semen parameters, particularly the motility and population of sperm cells, irrespective of treatment duration. The population of germinal epithelial cells was unchanged. However, the expression of Bcl-2 was reduced in the high dose (HS and HL) groups when compared to other groups.

Conclusion/Recommendations: The study suggests that moderate use of *Newbouldia laevis* extract for a limited period may have beneficial effects on male fertility potential with effects comparable to those of Zinc.

Keywords: *Newbouldia laevis*; semen parameters, germinal epithelium, Zinc, Bcl-2

Introduction

Nowadays, infertility has become a real public health problem because of its increasing prevalence, widespread distribution, and the difficulties inherent in its management. Infertility affects millions of people of reproductive age worldwide and has an impact on their families and communities. It is estimated that 48 million couples and 186 million individuals live with infertility globally.[1] Epidemiological data conclude that about 15% of couples go through troubles in having children and refer to physicians in search of solutions.[2] Infertility imposes stress on infertile couples and in different ways threatens their mental health in the form of emotional and psychological problems such as frustrations, fear and anxiety, depression, anger and aggression.[3] Infertility can be caused by female reproductive issues, as well as male reproductive problems.

Male factor infertility (MFI) is thought to be the cause of up to 50% of all cases of infertility globally and at least 30 million men worldwide are infertile with the highest rates in Africa and Eastern Europe.[4] There are potentially many different causes of male infertility, including hormonal, anatomical, and secondary exposure to exogenous substances. MFI is typically diagnosed through an abnormal semen analysis. While the semen analysis has multiple measured parameters, the most important are abnormalities in sperm count, ranging from fewer than normal sperm (oligospermia) to undetectable sperm cells (azoospermia), sperm

Correspondence to:

Misturah Y. Adana
Department of Anatomy,
Faculty of Basic Medical Sciences,
College of Health Sciences, University of Ilorin,
P.M.B. 1515, Ilorin, Nigeria.
Email: misturahadana@gmail.com,
adana.my@unilorin.edu.ng
ORCID: 0000 0001 8538 7838

https://dx.doi.org/10.4314/tjhc.v32i2.4

motility, and sperm morphology.[5] Many medications have been invented to tackle infertility, including clomiphene citrate and Tamoxifen. Some other trace elements have also been discovered to positively affect male fertility and are even contained in human semen. Examples include calcium (Ca), magnesium (Mg), selenium (Se) and particularly Zinc (Zn).[6]

Zinc is an essential mineral required for prenatal and postnatal development. It is a trace mineral, necessary for many enzyme activities and chemical reactions in the body. It is a major player in the creation of DNA, the growth of cells, the building of proteins, the healing of damaged tissue, and supporting a healthy immune system. As a hormone balancer, it helps hormones such as testosterone, prostrate and sexual health and functions as an antibacterial agent in men's urea system. It plays a role in epithelial integrity, showing that Zn is essential for maintaining the lining of the reproductive organs and may have a regulative role in the progress of capacitation and acrosome reaction.[7] In contrast, Zn deficiency impedes spermatogenesis is a reason for sperm abnormalities and has a negative effect on serum testosterone concentration. Based on these findings, the Zn micro-element is very essential for male fertility. It could be considered as a nutrient marker with many potentials in the prevention, diagnosis, and treatment of male infertility).[8]

In some parts of Africa and indeed Nigeria, a wide variety of plants are of great medicinal and nutritional importance. It has been documented that from time immemorial, plants have been used medicinally. Many plants/plant extracts have been used as fertility agents in folklore and traditional medicines without producing apparent toxic effects. Several plants have been used to enhance fertility, producing results similar to that of Zinc, an example of which is the *Newbouldia laevis* (*N. laevis*) plant. *N. laevis* is a rapidly growing perennial shrub that belongs to the Bignoniaceae family and extensively found in West and Central Africa. It is popularly referred to as the 'tree of life' or 'fertility tree' in Nigeria. It is locally referred to as ewe Akoko, Aduruku, or Ogirisi by the Yoruba, Hausa and Igbo tribes respectively.

Most importantly, *N. laevis* has been shown to have a great impact on improving fertility in both males and females. According to the research carried out by Sansone and colleagues, the result reveals that *N. laevis* extract may produce inhibitory effects or induce hormonal imbalances in males at certain dosages, as exemplified in the experimental animal models.[9] According to empirical evidence, in women, the *N. laevis* plant is used to treat a range of gynaecological issues, including miscarriage, irregular menstruation, suppression of menstrual flow, and others. These effects have been attributed to the rich phytonutrient mix of the herb.[10] Although *N. laevis* leaves modify several reproductive hormones in males, its overdose can modestly lower testosterone levels.[11] This research aims to determine the comparative effect of Zinc and graded doses of *N. laevis* on male fertility.

Materials and Methods

Collection and aqueous extraction of Newbouldia laevis

The leaves of *Newbouldia laevis* were harvested in Oke-ose Ilorin, Kwara State, Nigeria. The plant was authenticated at the Botany Department of the University of Ilorin, Nigeria. Extraction was done by methods described by Akande et al., 2020.[10] The fresh leaves of the harvested *N. laevis* were washed with distilled water to remove dust and other foreign particles. The leaves were then air-dried on a clean surface at room temperature and ground into a fine powder using a blender. Exactly 400 g of the powdered leaf sample of *N. laevis* was soaked in a clean container with distilled water. The mixture was allowed to stand for 72 hours with constant stirring. The filtrate was then separated by repeated filtration with sterile filter paper. The filtrates were concentrated at room temperature; then, the aqueous part was allowed to dry.[12] The crude extracts obtained were stored in a tight container and kept in a refrigerator at 4°C for further use.

Animal care

Thirty-six (36) male Wistar rats were purchased from Ilorin. The animals were housed at the animal house of the Faculty of Basic Medical Sciences, University of Ilorin. The rats were immediately weighed, and their weights recorded. They were kept in well-ventilated plastic cages with wood shavings. The Ethical Committee (Institutional Animal Care and Use Committee - IACUC) of the University of Ilorin approved the protocol with reference number UERC/ASN/2022/2362.

Animal grouping and treatments

The thirty-six (36) male Wistar rats weighing between 55 - 125g were obtained and bred in the animal house of the College of Health Sciences, University of Ilorin and were used for the research. The rats were randomly assigned into 6 groups of 5 rats each, viz: Normal Saline (NS), Zinc (ZN), Low dose short-term (LS), High dose short-term (HS), Low dose long-term (LL), High dose long-term (HL). The rats were fed daily with rat pellets grower mash. All animals were given water ad libitum. The animals were allowed to acclimatize for a period of 2 weeks. Animals were weighed once every week during this acclimatization period. Female Wistar rats were later purchased for mating as the research proceeded. The 50 mg-strength Zinc tablets were used

in this study.

Experimental design

Animals were randomly placed into six groups of five animals each, according to the treatment given. Group NS had normal saline, ZN had 100mg/kg of Zinc,[13] and LS and HS were given 200mg/kg and 400mg/kg [9] of *Newbouldia laevis* extract, respectively, daily for 28 days. While LL and HL had 200mg/kg and 400mg/kg daily for 56 days, respectively. The animals were weighed weekly for dose adjustments.

Animal sacrifice and tissue collection

The animals were sacrificed at 28 days and 56 days following daily administration via cervical dislocation. The rats' limbs were pinned in supination for easy access to the organs. A distal abdominal incision was made close to the urogenital area, and a cut was made along the abdomen, cutting the dome of the diaphragm and exposing the thoracic cavity, after which blood was carefully withdrawn from the apex (left ventricle) of the heart using a 5 ml syringe into an EDTA bottle. The testes were carefully excised from the abdomen and weighed using a sensitive scale to the nearest 0.1g. The relative testicular weights (RTW) were calculated (using the formula; RTW = Testicular weight /Final body weight)

The cauda epididymis was separated from the testis and minced in 2 ml of normal saline. The resulting epididymal sperm suspension was used in determining the semen parameters. The excised testes were fixed in 10% formaldehyde solution.

Semen Analysis

The percentage of progressively motile sperm was evaluated using a light microscope at 400× magnification. For this procedure, one drop of sperm suspension was placed in the Neubauer's counting chamber. Sperm motility was divided into four levels according to certain criteria such as slowly progressive forward movement, rapid progressive forward movement, residual motion and those motionless were counted in several microscopic fields and percentages of motile and immotile sperm cells were recorded.

In counting sperm cells, a small amount of prepared epididymal sperm suspension was diluted with 10% formalin in phosphate-buffered saline in the ratio 1:20. An aliquot of the diluted suspension, about 10ul was transferred into a Neubauer's counting chamber using a Pasteur pipette, and the solution was allowed to remain for seven minutes. Then the sperms at the four corners and the centre of the central square were counted.

Tissue processing for histological Analysis

The fixed testes underwent a series of histological processes to enable viewing of the cytoarchitecture. Histological slides were examined under a light microscope at low (X10) and high (X40) magnifications and photographed using a USB camera and then comparisons were made between the control and treated groups.

Bcl-2 Expression

Sections of 5 µm thickness obtained from routine paraffin were deparaffinized and subjected to antigen retrieval by heating in a citrate-based antigen unmasking solution, pH 6.0 (Vector Labs, CA, USA) for 30 minutes in a steamer and allowed to cool on the bench at room temperature for another 30 minutes. Endogenous peroxidase blocking was performed in 0.3 % hydrogen peroxide in phosphate-buffered saline (PBS, pH 7.4) for 10 minutes. Sections were then incubated at room temperature for 2 hours in primary rabbit antibodies diluted in a universal antibody diluent and blocking reagent, UltraCruz® Blocking Reagent (Santa Cruz, USA). The primary antibody used was Bcl-2 (Novus Biologicals, USA; NB100-56098) at 1:2500, sections were washed in PBS and incubated in ImmPRESS™ HRP Anti-Rabbit IgG (Peroxidase) Polymer Reagent, made in horse (Vector Labs, USA). Colour was developed with DAB Peroxidase (HRP) Substrate Kit (Vector Labs, USA), and sections were counter-stained in hematoxylin [14,15]

Statistical Analysis

Data was expressed as mean ± standard error of the mean (SEM). The difference between means was determined using Analysis of Variance (ANOVA). A p-value9 < 0.05 was considered significant.

Results

Relative Testicular Weight

Animals in groups LS, HS and HL showed rapid weight gain, but this was not reflected in the testicular weights. There were no significant differences in the relative testicular weights across the groups. (See table 1)

Semen Analysis

Sperm motility

Groups ZN, LS and LL had significantly higher numbers of progressively motile sperms compared with the NS group. Group HS has the lowest percentage. HS and HL displayed significantly lower motility than the Zn group ($p<0.05$). See Figure 1

Sperm Count

Findings in the sperm concentration are similar to those with the motility. The Zinc group had the highest concentration, with comparable counts in the LS and LL groups. The HS and HL groups have lesser numbers of sperm cells per milliliter of semen. (See Figure 2)

Table 1: Relative Testicular Weight across all animal groups

Groups	Weight gain	Final Body Weight	Testicular Weight	Relative Testicular Weight
NS	66.00 ± 13.79	173.8 ± 15.37	1.79 ± 0.434	1.338 ± 0.06
ZN	73.200 ± 36.18	210.6 ± 26.87	2.43 ± 0.200	1.190 ± 0.075
LS	101.80 ± 9.29*	241.8 ± 11.70	2.99 ± 0.22	1.246 ± 0.107
HS	94.80 ± 6.08*	236.4 ± 9.08	2.64 ± 0.06	1.124 ± 0.048
LL	76.40 ± 14.47	233.0 ± 14.15	2.53 ± 0.21	1.094 ± 0.088
HL	98.60 ± 11.84*	247.2 ± 16.59	2.90 ± 0.14	1.180 ± 0.054

* significant difference compared to NS

Table 2: Population of BCl-2-stained cells in the germinal epithelium

Group	Mean ±SEM
NS	790.00 ± 15.15
ZN	1028.00 ± 6.87*
LS	1035.00 ± 7.40*
HS	1043.40 ± 4.91*
LL	1131.00 ± 7.74*
HL	769.80 ± 14.32*

*Significantly different compared to NS

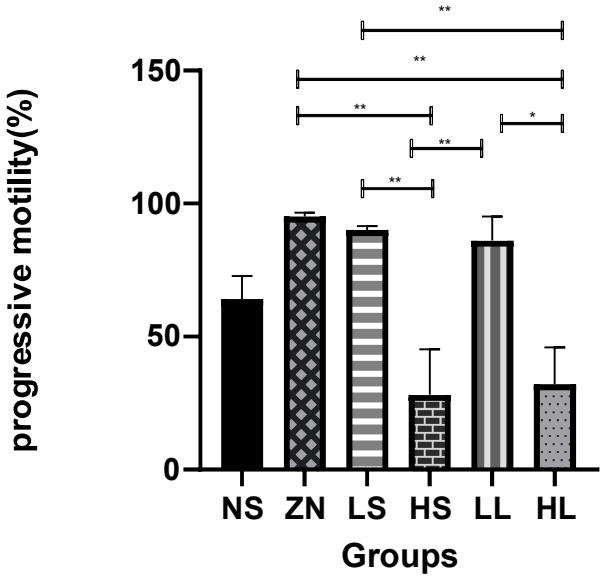

Figure 1: Progressive sperm motility for animals in groups NS, ZN, LS, HS, LL and HL. * indicates significant difference between two groups at p< 0.05, ** indicates significant difference between two groups at p< 0.01.

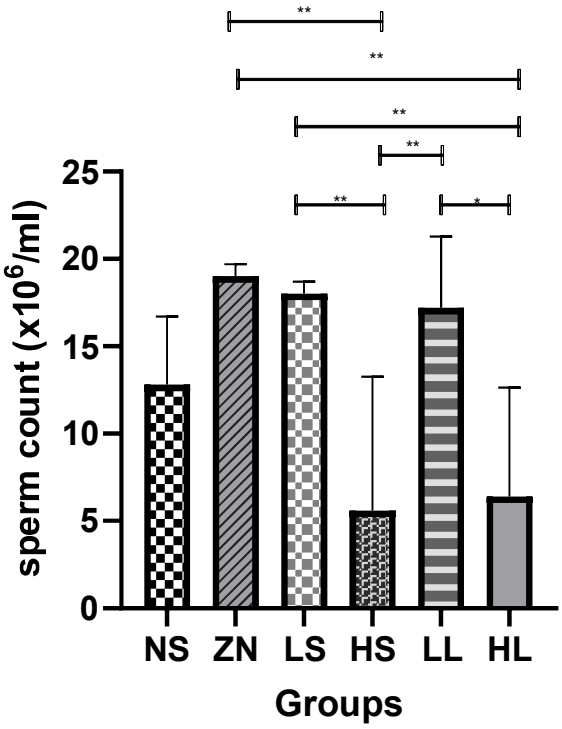

Figure 2: Sperm count for animals in groups NS, ZN, LS, HS, LL and HL. * indicates significant difference between two groups at p< 0.05, ** indicates significant difference between two groups at p< 0.01.

Histological Observation

Histological examination of tissue sections from the testes of animals in the experimental groups displayed varying observations. The NS group displayed normal progression of the cells of the spermatogenic series from the spermatogonic cells line lines on the basement membrane to the mature spermatozoa in the lumen. Testicular tissues of the rats receiving low and high doses of Newbouldia laevis displayed a depleted and distorted progression of the cells of the germinal epithelium. While the distortion in the high dose groups appeared to be accompanied by hyperchromasia, the low dose groups were associated with widening of the lumen and vacuolation in the germinal epithelium (see Figure 3).

Bcl-2 expression

BCL-2 is found on the outer membrane of cells' mitochondria, where it functions to support cellular viability and impede the activities of proteins that encourage apoptosis. Immunohistochemical

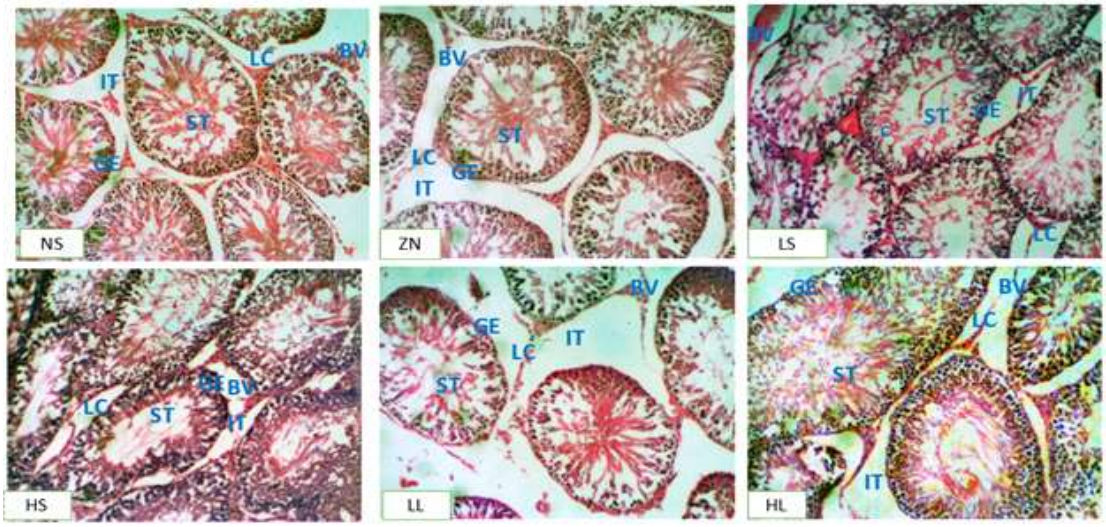

Figure 3: Histology of the testes of the Control and Experimental groups (H and E 100x magnification). NS – Control group, ZN – Zinc group, LS – Low dose of N. laevis in the short term, HS – High dose of N. laevis in the short term, LL – low dose of N. laevis in the long term, and HL- high dose of N. laevis in long term. GE- germinal epithelium, ST- spermatid, LC- Leydig cells, IT- Interstitium, BV- Blood vessels

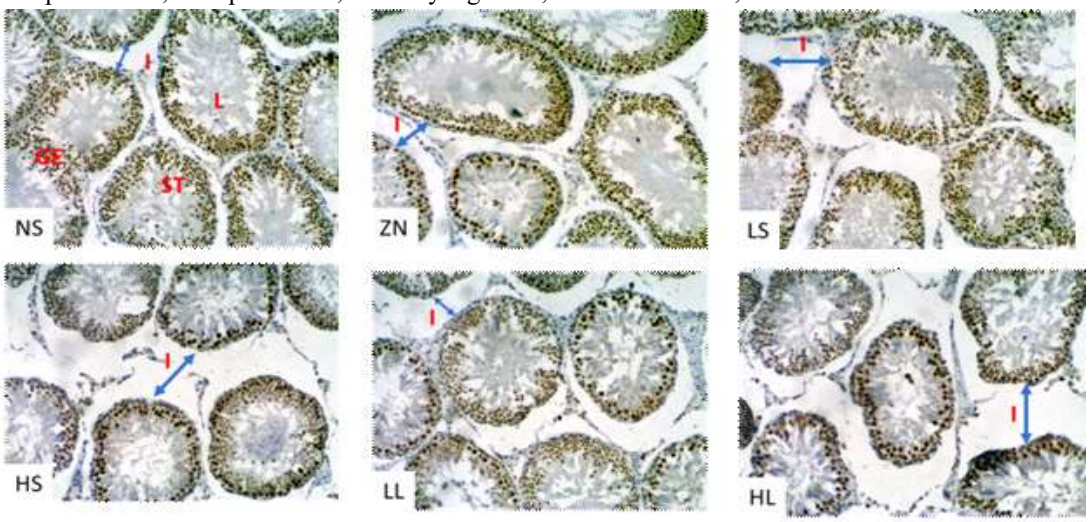

Figure 4: Immunohistochemical view of the testes of the Control and Experimental groups (BCL2 100x magnification). NS – Control group, ZN – Zinc group, LS – Low dose of N. laevis in the short term, HS – High dose of N. laevis in the short term, LL – low dose of N. laevis in the long term, and HL- high dose of N. laevis in the long term. GE- germinal epithelium, ST- seminiferous tubule, LC- Leydig cells, I- Interstitium.

expression of Bcl-2 in tissues, particularly the germinal epithelium of the testes, is an indication of the proliferative properties of its cells. In this examination, a 100x magnification was used to assess the expression of Bcl-2 in the seminiferous tubule of the rats' testes. The study revealed that rats in groups HS and HL displayed fewer Bcl-2 stained cells when compared to NS and ZN groups. The expression in LS and LL were comparable to that of the ZN group (see Figure 4).

BCL2 staining cell count

The number of Bcl-2-stained cells in the HL group was low compared to those of the other groups (NS, ZN, LS, and LL). The LS expressed the highest Bcl-2 in the germinal epithelium (see Table 2).

Discussion

The present study was carried out to determine the effect of *Newbouldia laevis* on the testicular histoarchitecture and compare its effect with that of Zinc, a trace element known for the vital role it plays in the development of the three major accessory sex glands in male reproduction (the testis, epididymis, and prostate). It plays a key role in the initial stages of germ cell development and spermatogenesis.[6]

Several pathological conditions such as varicocele and orchitis, as well as exposure to therapeutic and toxic environmental agents, can lead to testicular dysfunction through multiple mechanisms including oxidative stress, inflammation and apoptosis, which ultimately will lead to male infertility.[11] A search for

agents that can prevent and protect against reproductive challenges becomes imperative. Natural agents have become a thing in many health conditions today.[16,17] In recent years, Newbouldia laevis has gained attention due to its massive and profound health benefits.[18] Previous reports show the potency of *Newbouldia laevis* for the management of male infertility.[16] However, its definitive role in male reproductive biology has not yet been evaluated.

The organ weight serves as a reliable as well as reasonably sensitive marker of testicular health.[19] Testis size, weight, and tubular diameter often decrease as a result of the loss of germ cells from the seminiferous tubules and decreasing seminiferous tubule fluid secretion. Certain toxicants cause a brief rise in testis size due to an increase in interstitial fluid, but a drop in weight will always accompany the degeneration of the seminiferous epithelium.[20] In the study, the administration of *Newbouldia laevis* did not affect the testicular weight. The testicular weights were maintained even in the groups with altered testicular histoarchitecture.

Zinc is also involved in various biochemical processes of the body and is said to positively affect male fertility. Hence, in this study, it was found that Zn induced increases in sperm motility and count. A comparable effect was observed in low-dose *Newbouldia laevis*, irrespective of the duration, while high doses have shown deleterious effects on sperm motility. This was also observed in the effects on sperm count. Likewise, a recent study on rabbits revealed similar findings.[21] In recent years, *Newbouldia laevis* has gained attention due to its massive and profound health benefits. Previous reports show the potency of *Newbouldia laevis* for the management of male infertility.[16] Different animal species have been used to demonstrate the fertility-enhancing properties of Newbouldia laevis in males. Studies done in rabbits,[22] Wistar rats,[23,24] and albino rats[17] suggest the beneficial properties of the herb. However, its definitive role in human reproductive biology has not yet been evaluated. The findings of these research also conclude that the low doses appear to be safer and more beneficial to the reproductive system.[17,24]

The testicular histoarchitectural findings were also in tandem with the reports from semen analysis. The testes of the rats treated with a high dose of *Newbouldia laevis* displayed distorted germinal epithelium with very large interstitium and smaller seminiferous tubules. While this study has revealed both the beneficial and deleterious effects of *Newbouldia laevis* on male reproductive potential, many authors have reported the positive effects of this plant on fertility.[18,21] *Newbouldia laevis* maintained the normal histoarchitecture of the testes at modest doses, while degenerative changes were observed at higher doses.

The immunohistochemical study of Bcl-2 expression reveals that the protein was mostly seen in cell populations with a long lifespan and cells with the capacity to proliferate.[25] It has been shown that a reduction in Bcl-2 levels causes cell death through apoptosis.[26] Additionally, Bcl-2 overexpression has been shown to prevent epithelial cells from dying.[27,28] In this study, Bcl-2 expression was higher with the use of *Newbouldia laevis*. This was observed in the spermatogonia cells and the primary spermatocytes. High doses of the herb exhibited depletion of the spermatogonia population in the germinal epithelium, which also indicates a reduction in cellular proliferation. The length of exposure to *Newbouldia laevis*, however, reveals no effect on the expression of Bcl-2 in the cells. Moderate uses of *Newbouldia laevis* may promote tissue regeneration and maintenance in the testes. This agrees with the findings of Adebisi et al., 2024.[23] Similarly, in a study of the effects of glyphosate-induced testicular toxicity in rabbits, *Newbouldia laevis* restored the testicular histoarchitecture.[22]

This study revealed that low doses of *Newbouldia laevis* have a beneficial effect comparable to the use of Zinc on male fertility potential. However, the herb has been shown to have dose—and duration-dependent adverse effects on reproductive functions in male rats. A more detailed study of the biochemical effects of this herb will help analyze the exact mechanism for the observed results. Similarly, in a study of the effects of glyphosate-induced testicular toxicity in rabbits, *Newbouldia laevis* restored the testicular histoarchitecture.

Acknowledgments
The authors appreciate the contributions of the technical staffs of the Department of Anatomy, University of Ilorin for their support during this study.

References

1. World Health Organization. WHO fact sheet on infertility. LWW; 2021. p. e52.
2. Sharlip ID, Jarow JP, Belker AM, Lipshultz LI, Sigman M, Thomas AJ, et al. Best practice policies for male infertility. Fertility and sterility. 2002 May 1;77(5):873-82.
3. Agbodjento E, Klotoé JR, Sacramento TI, Dougnon V, Tchabi FL, Déguénon E, et al. Ethnobotanical knowledge of medicinal plants used in the treatment of male infertility in southern Benin. Advances in Traditional Medicine. 2021 Dec;21:655-73.
4. Agarwal A, Mulgund A, Hamada A, Chyatte MR.

A unique view on male infertility around the globe. *Reproductive Biology and Endocrinology*. 2015/04/26 2015;13(1):37. doi:10.1186/s12958-015-0032-1
5. Brezina PR, Yunus FN, Zhao YJJor, infertility. Effects of pharmaceutical medications on male fertility. 2012;13(1):3.
6. Mirnamniha M, Faroughi F, Tahmasbpour E, Ebrahimi P, Beigi Harchegani AJRoeh. An overview on role of some trace elements in human reproductive health, sperm function and fertilization process. 2019;34(4):339-348.
7. Fallah A, Mohammad-Hasani A, Colagar AHJJor, infertility. Zinc is an essential element for male fertility: a review of Zn roles in men's health, germination, sperm quality, and fertilization. 2018;19(2):69.
8. Zhao J, Dong X, Hu X, et al. Zinc levels in seminal plasma and their correlation with male infertility: A systematic review and meta-analysis. 2016;6(1):22386.
9. Egba SI, Sunday GI, Anaduaka EG. The effect of oral administration of aqueous extract of Newbouldia laevis leaves on fertility hormones of male albino rats. *J Pharm Biol Sci*. 2014;9(3):61-4.
10. Akande E, Oladejo B, Oladunmoye M, Abodunrin T. Antibacterial effects of Newbouldia laevis {P. BEAUV} on the bacteria isolated from the blood of hepatitis C virus positive individuals. *Asian Plant Research Journal*. 2020;4(1):26-34.
11. Sansone A, Di Dato C, de Angelis C, Menafra D, Pozza C, Pivonello R, et al. Smoke, alcohol and drug addiction and male fertility. Reproductive biology and endocrinology. 2018 Dec;16:1-1.
12. Akande E, Oladejo B, Oladunmoye M, Abodunrin TJAPRJ. Antibacterial effects of Newbouldia laevis {P. BEAUV} on the bacteria isolated from the blood of hepatitis C virus positive individuals. 2020;15(1):26-34.
13. Ahmad M, Hassan B, Abbass S, Butt NI, Sabir M, Ali L. Effect of Zinc Supplementation on Heat Induced Gross Changes in Testes of Adult Mice. 2020:
14. Erukainure OL, Ijomone OM, Sanni O, Aschner M, Islam MS. Type 2 diabetes induced oxidative brain injury involves altered cerebellar neuronal integrity and elemental distribution, and exacerbated Nrf2 expression: therapeutic potential of raffia palm (Raphia hookeri) wine. *Metabolic brain disease*. 2019;34:1385-1399.
15. Ijomone OM, Olatunji SY, Owolabi JO, Naicker T, Aschner M. Nickel-induced neurodegeneration in the hippocampus, striatum and cortex; an ultrastructural insight, and the role of caspase-3 and α-synuclein. *Journal of Trace Elements in Medicine and Biology*. 2018;50:16-23.
16. Alabi OA, Okorie B, Simon-Oke IA, Atanda HC, Olumurewa JA, Adebo TCJP. Cellular toxicity and DNA damage induced by Newbouldia laevis used for male infertility treatment in prokaryotic and eukaryotic models. 2024;261(1):53-64.
17. Oluwayemisi BT, Kehinde AN, Carole NC, Moses ZZ, Ifeanacho NW. Fertility Enhancing Efficacy of Ethanol Leaf Extract of Newbouldia laevis (Boundary Tree) In both Male and Female Albino Rats. 2023;
18. Okagu IU, Ndefo JC, Agbo MOJPS. Trado-medical uses, chemical constituents and biological activities of Newbouldia laevis (Bignoniaceae): a review. 2021;28(1):51-75.
19. Negm WA, El-Kadem AH, Hussein IA, Alqahtani MJJB. The mechanistic perspective of bilobetin protective effects against cisplatin-induced testicular toxicity: Role of Nrf-2/Keap-1 signaling, inflammation, and apoptosis. 2022;10(5):1134.
20. Haschek WM, Rousseaux CG, Wallig MA. Chapter 18 - Male Reproductive System. In: Haschek WM, Rousseaux CG, Wallig MA, eds. *Fundamentals of Toxicologic Pathology (Second Edition)*. Academic Press; 2010:553-597.
21. Kolo H, Abdulraheem B, Otu BO, Kolo PS, Banjo A, Dikko A. Semen Characteristics of Rabbit Bucks Fed Graded Levels of Newbouldia laevis Leaf Meal. 2022;
22. Ansa AA, Odegbunam CV, Ogechi GJ, Obidike FI. Testicular histomorphology, sperm and testicular morphometric evaluation of glyphosate exposed rabbit bucks treated with hydro-alcoholic leaf extract of Newbouldia laevis. *Acta Scientiarum Animal Sciences*. 2025;47(1)
23. Adebisi K, Leko B, Idaguko C. Influence of aqueous leave extract of Newbouldia laevis on cadmium chloride-induced toxicity in pituitary-testicular axis of rats. *Journal of Experimental and Clinical Anatomy*. 2024;21(2):172-179.
24. Murtala AA, Akindele AJ, Oreagba IA. Ninety-Day Toxicological Assessment of Preparation of the Medicinal Plant Newbouldia laevis (P. Beauv.) Seem.(Bignoniaceae) in Rats. *Natural Product Communications*. 2024;19(5):1934578X241257080.
25. Vornic I, Pop O, Pascalau A, Andreescu G, Beiusan C, Manole F, et al. Assessing the role of Bcl-2 and p53 in apoptotic mechanisms in spontaneous abortions. Pharmacophore. 2024;15(2-2024):1-6.
26. Klanova M, Klener P. BCL-2 proteins in pathogenesis and therapy of B-cell non-Hodgkin lymphomas. *Cancers*. 2020;12(4):938.
27. Lu Q-L, Abel P, Foster CS, Lalani E-N. bcl-2: Role in epithelial differentiation and oncogenesis. *Human Pathology*. 1996/02/01/ 1996;27(2):102-110. doi:https://doi.org/10.1016/S0046-8177(96)90362-7
28. Veleta KA, Cleveland AH, Babcock BR, He YW, Hwang D, Sokolsky-Papkov M, et al. Antiapoptotic Bcl-2 family proteins BCL-xL and MCL-1 integrate neural progenitor survival and proliferation during postnatal cerebellar neurogenesis. Cell Death & Differentiation. 2021 May;28(5):1579-92.