Chromosomal and histopathogical alterations in *Clarias gariepinus* (Siluriformes, Clariidae) following exposure to Shea butter effluent

Olufemi D. Owolabi[1], Oluyinka A. Iyiola[2]
[1]Fisheries and Hydrobiology Research Laboratory, Department of Zoology, University of Ilorin, P.M.B 1515, Ilorin, Kwara State, Nigeria.
[2]Cell Biology and Genetics Unit, Department of Zoology, University of Ilorin, P.M.B 1515, Ilorin, Kwara State, Nigeria.

Corresponding author: Olufemi D. Owolabi
E-mail: olulabi@unilorin.edu.ng; Phone: +2348034313927,

ABSTRACT

Background: Aquatic ecosystems have been a consistent recipient of industrial effluents capable of inducing genotoxic and histopathological effects on aquatic organisms if untreated.

Objectives: The aim of this study was to examine the genotoxic, using chromosomal aberration (CA) assay, and histopathological effects of Shea butter effluent (SBE) on *Clarias gariepinus*; one of the most widely consumed fish in Nigeria.

Methods: Fish were exposed to different lethal concentrations (0.00, 0.045, 0.050, 0.055, 0.060 g/l) for 96 hours and varying chronic concentrations (0.00, 0.0045, 0.0050, 0.0055, 0.0060 g/l) of SBE for 14, 21 and 28 days after range finding test. Fish were intraperitoneally-injected with 0.05% colchicine 2-3 hours before sacrifice. Physico-chemical parameters and heavy metal contents of the SBE were determined using standard procedures. After exposure, fish were sacrificed and dissected to remove the gills, liver and kidney from both the experimental and control groups. These organs were analysed for chromosomal aberrations and histopathological lesions.

Results: There was a significant increase in CA frequency ($P < 0.05$) induced by SBE in gills, liver and kidney among the treated groups compared with the control. Various types of CA observed were chromatids gaps and deletions, acentric, dicentric and ring chromosomes. Histopathological analyses revealed epithelial lifting, necrosis, lamellar fusion, oedema and haemorrhage in the gill, while vacuolation, hyperplasia, sinusoids, hypertrophy and necrosis were observed in the liver.

Conclusion: This study suggests that untreated SBE contains potentially genotoxic and clastogenic substances capable of inducing DNA damage and histopathological lesions in *C. gariepinus*.

Key words: Shea butter, effluent, chromosome aberration, histopathology, *Clarias gariepinus*

Altérations chromosomiques et histopathologiques chez *Clarias gariepinus* (Siluriformes, Clariidae) après exposition aux effluents de beurre de karité

Olufemi D. Owolabi[1], Oluyinka A. Iyiola[2]

[1]Laboratoire de recherche sur les pêches et l'hydrobiologie, Département de zoologie, Université d'Ilorin, P.M.B 1515, Ilorin, État de Kwara, Nigéria.
[2]Unité de biologie cellulaire et de génétique, Département de zoologie, Université d'Ilorin, P.M.B 1515, Ilorin, État de Kwara, Nigéria.

Auteur de correspondance : Olufemi D. Owolabi
E-mail: olulabi@unilorin.edu.ng; Téléphone : +2348034313927,

RESUME

Contexte : Les écosystèmes aquatiques sont un récepteur constant d'effluents industriels capables d'induire des effets génotoxiques et histopathologiques sur les organismes aquatiques s'ils ne sont pas traités.

Objectifs : Le but de cette étude était d'examiner les effets génotoxiques, à l'aide du test de l'aberration chromosomique (AC), et les effets histopathologiques de l'effluent de beurre de karité (SBE) sur *Clarias gariepinus*; un des poissons les plus consommés au Nigeria.

Méthodes : Les poissons ont été exposés à différentes concentrations létales (0,00, 0,045, 0,050, 0,055, 0,060 g/l) pendant 96 heures et à diverses concentrations chroniques (0,00, 0,0045, 0,0050, 0,0055, 0,0060 g/l) de SBE pendant 14, 21 et 28 jours après le test de recherche de distance. Les poissons ont reçu une injection de 0,05% de colchicine par voie intrapéritonéale 2 à 3 heures avant le sacrifice. Les paramètres physico-chimiques et les teneurs en métaux lourds de la SBE ont été déterminés à l'aide de procédures standard. Après exposition, les poissons ont été sacrifiés et disséqués pour éliminer les branchies, le foie et les reins des groupes expérimental et témoin. Ces organes ont été analysés pour rechercher des aberrations chromosomiques et des lésions histopathologiques.

Résultats : Il y avait une augmentation significative de la fréquence des AC ($P < 0,05$) induite par la SBE dans les branchies, le foie et les reins parmi les groupes traités par rapport au groupe témoin. Les divers types de CA observés étaient les chromatides chromosomes acentriques, dicentriques et cycliques. Les analyses histopathologiques ont révélé un soulèvement épithélial, une nécrose, une fusion lamellaire, un œdème et une hémorragie dans les branchies, tandis qu'une vacuolisation, une hyperplasie, des sinusoïdes, une hypertrophie et une nécrose étaient observées dans le foie.

Conclusion : cette étude suggère que les SBE non traités contiennent des substances potentiellement génotoxiques et clastogènes capables d'induire des lésions de l'ADN et des lésions histopathologiques chez *C. gariepinus*.

Mots clés : beurre de karité, effluent, aberration chromosomique, histopathologie, *Clarias gariepinus*

INTRODUCTION

In many developing countries of the world, aquatic ecosystems are often being used as recipient of chemical pollutants, industrial effluents and xenobiotics. The close proximity of industries to water bodies could lead to greater influx of untreated industrial effluents into the aquatic environment and thereby contaminate the environment. This has, over the years, been reported to be deleterious to aquatic life and subsequently human.[1] Developing nations including Nigeria rely on products from small scale industries for the ever-increasing population which continuously generate liquid and solid wastes that have not been properly treated before being released into water bodies; due to failure of law enforcement by government and concerned agencies. One of such products from small-scale industries is shea butter which is produced from raw shea nuts. Shea nuts are obtained from Shea tree belonging to the family Sapotaceae and it is indigenous to Africa. Shea butter is mostly sought after because of its immense usefulness in cooking, cosmetics, as skin and hair moisturizer, pharmaceutical and traditional needs.[2] It is known for its healing properties against skin rashes, insect bites and stings, acne, burns etc. These benefits probably informed the increased production and use of shea butter. In Nigeria, the major method of shea butter extraction from the shea kernel/nut is through the traditional technique, which is not only cumbersome but environmentally unfriendly.This production process involves several steps which include but not limited to seed harvesting and treatment, cleaning, boiling, oil extraction and recovery and drying. The effluent wastewater produced during each processing stage could likely contain highly concentrated organic substances; and should these be washed as run-off into waterbodies, it may cause devastating effects on aquatic biota and their consumers.

The discharge of industrial effluent into aquatic ecosystem has been of great public health concern for many decades in many countries of the world.[3] Industrial wastewater are known to contain odorous, offensive and hazardous substances which can affect water quality, thereby causing death or reproductive failure in fish and/or accumulate in fish tissues and may portend long-term health risks to human.[4] Available information have shown that heavy metals are the major constituents of industrial wastewater; and have always been of serious concern because of their toxicity, bioaccumulation and biomagnification in living organisms.[4] Furthermore, their persistence and non-biodegradable nature when released into the environment has contributed to their concern.[5] A number of substances contained in industrial wastewater are reported to likely be genotoxic, mutagenic and carcinogenic and have also been suspected to be a possible cause of human health hazards such as cancer and cardiovascular diseases.[6, 7] However, information on the chemical constituents of shea butter effluent (SBE) and their cytotoxic potentials in aquatic biota is scarce, inspite of being reported to be toxic and may likely pose serious threat to fishes and human health.[8,9]

Fish are known to be suitable model for monitoring the effects of contaminants in aquatic ecosystems because of their ability to metabolize and bioaccumulate xenobiotics. *Clarias gariepinus* is a popular food fish in Nigeria, widely distributed and commonly grown by fish farmers because of their hardiness. Its labile food/feeding and benthopelagic habits enhance its surface area of exposure to aquatic contaminants, hence it is often cultured in water bodies contaminated with agricultural and industrial effluents.[10] In order to have a better understanding of the negative impact of xenobiotics on organisms, different biomarkers are used. Cellular and tissue levels biomarkers such as chromosomal and histological alterations in different fish organs give valuable information about such impact. Histopathology is a very sensitive biomarker and with the use of cytogenetic endpoints such as chromosomal aberrations assays, the effects of toxicants at sublethal levels in *vivo* can easily be understood. There are many documented reports on the genotoxic, cytotoxic and DNA damaging effects of xenobiotics on fish.[11-14] Previous studies also reported various structural abnomalities in fish gill and liver which support the evidence that industrial wastewater effluent is toxic to fish.[15-18]

Study on the genetic damage caused by SBE in fish is imperative in order to assess and monitor pollution in aquatic environment. Currently, dearth of information exists on the possible genotoxic, cytotoxic and pathological effects of SBE on aquatic vertebrates. This study is, therefore, aimed at investigating the possible occurrence of chromosomal and histological changes in the tissues of *Clarias gariepinus* exposed to SBE-contaminated water; with a view to providing baseline data on biosafety levels of SBE for aquatic survival and formulation of strategies for bioremediation.

METHODS

Shea butter effluent collection, physicochemical and heavy metal analyses

Raw sheabutter effluent (SBE) was collected in three

25-litre containers each from the local factory of shea butter in Tede, Atisbo Local Government Area, Oke-Ogun, Oyo State, Nigeria (latitude 3.42^{0}E and longitude 8.54^{0}N). The effluent-filled containers were put in water containing ice blocks to prevent the fermentation of the effluent. This was then transported to the Fisheries and Hydrobiology Laboratory, Department of Zoology, University of Ilorin, Ilorin. The effluent was analyzed to determine a number of physico-chemical parameters such as biological oxygen demand (BOD), chemical oxygen demand (COD), total dissolved solids (TDS), alkalinity, chlorides, phosphates, sulphates, nitrate ions and ammonia according to methods described by APHA (2005).[19] Eight heavy metals namely cadmium (Cd), copper (Cu), chromium (Cr), iron (Fe), mercury (Hg), zinc (Zn), nickel (Ni) and manganese (Mn) in the effluent were analyzed using Perkin atomic absorption spectrophotometer (Perking Elmer E. Analyst, 2000, USA) following standard analytical methods (USEPA, 1996; APHA, 2005).[20,19]

Animals and experimental design

Juvenile *C. gariepinus* with average weight of 9.47±1.13 g and average length of 8.02±0.5cm were obtained from commercial fish farm in Ilorin, Kwara State, Nigeria. Prior to experiments, fish were acclimated to laboratory conditions for 14 days in 50-litre tanks with a constantly aerated chlorine-free borehole water (pH=7.6) maintained under 12/12 h dark/light photoperiod. During acclimation, water was changed once every two days to avoid pollution through the feeds that were not eaten and their waste in order to reduce mortality. Fishes were fed twice daily at 9.00 hours and 16.00 hours with pelleted feed (Coppens) at 3% of their body weight. The fishes were observed for any possible behavioural changes through their swimming activities and physical change.[20]

Range finding, acute and chronic toxicity assays

Acute toxicity test was conducted to determine the 96 h LC_{50} value of the effluent following standard guidelines.[21] Presumptive tests were conducted to find out the range of concentrations to be used in the acute bioassays. Based on the data obtained from the range finding tests, four nominal concentrations (0.045, 0.050, 0.055, 0.060 g/l) of the effluent were prepared by serially diluting the stock with water and the control groups were set up in a static renewal bioassay for the in vivo experiment. To each concentration, ten fish were introduced in triplicates and were deprived of food for the 96 h period the acute exposure lasted. Behavioural changes and mortality were monitored throughout the experiment. Fish were assumed dead when there was no body movement after gentle prodding. For chronic assay, ten fish specimens were randomly selected and placed each in plastic aquarium containing sublethal concentrations (0.0045, 0.0050, 0.0055 and 0.0060 g/l) equivalent to 1/10th each of the concentrations used for acute assay. The set-up was in triplicates including the control group (borehole water without sheabutter effluent). Fish were fed twice daily with 4% feed per body weight. The experiment spanned 28 days and water was changed every 2 days to maintain the potency of the effluent and level of dissolved oxygen as well as minimizing the metabolic wastes and food remains during the experiment. After 14, 21 and 28 days of exposure to varying concentrations of SBE, three fish from each treatment and the control group were sacrificed and their gill, liver and kidney excised for chromosomal aberration, while samples for histopathology assays were sacrificed and their gill and liver removed at the end of 28 days. Approximately 2-3 hours prior to sacrifice and dissection in both acute and chronic assays, the three fish from the control group were intraperitoneally injected with 0.05% colchicine at 1 ml per 100 g body weight. The experimental protocol was approved by the University of Ilorin Ethical Committee and the experiments strictly adhered to the "Principles and Guides for the Use and Care of Laboratory Animals" as contained in the US National Institutes of Health publication (NIH number 85-23, revised 1985).

Fish chromosomal aberration assay

This was undertaken with some modifications after the earlier reported method (Nagpure et al.2007)[22]. Both control and effluent-exposed fish were anaesthetized with ethylene glycol prior to dissection in order to remove the gill, liver and kidney in a petri dish and then cut into small pieces. Cell suspension was prepared by homogenizing each of the tissues in 8 ml hypotonic solution. The suspension was then poured into 15 ml centrifuge tube and incubated for 20-25 minutes at room temperature. One ml of freshly prepared Carnoy's fixative was added in order to stop the hypotonic action. Following gentle mixing with pasture pipette, cell suspension was centrifuged at 1200-1500 rpm for 10 minutes at room temperature and supernatants were carefully removed. The resultant cell pellets were slowly overlaid with 6-8 ml freshly prepared chilled Carnoy's fixative. The tubes were kept in refrigerator for half an hour after which the cell suspensions were centrifuged at 1200-1500 rpm for 10 minutes at room temperature. Supernatant was removed without

disturbing cell pellet at the bottom and fresh Cannoy's tubes kept in refrigerator for half an hour. This last step was repeated 3-5 times until transparent cell suspension is obtained and the clear cell suspension was dropped it using a micropipette onto grease free, pre cleaned slide. Finally the fixative was again added and slides were stained with 4-5% Giemsa stain in phosphate buffer (pH 6.8) for 15-20 minutes and the metaphase spread was then viewed under the microscope (OLYMPUS CX22 series). Mitotic index (MI) was calculated by counting the metaphase cells from 3000 cells/concentration using a cell counter (DURGA Limited, Korea) and expressed in percentage. MI was calculated from 6 slides/concentration (i.e. 2 slides/fish). Percentage frequency of aberration was calculated as total number of chromosomal aberrations divided by the total number of dividing cells × 100. Approximately 200 well spread metaphase cells/fish were analyzed.

Histopathological assay

At the end of 28 days exposure, the gill, liver and kidney were carefully removed and separately fixed in Bouin's fluid for 24 hours at room temperature to prevent putrefaction and autolysis. The tissues were washed in running tap water to remove excess picric acid and consecutively dehydrated in graded concentrations (i.e. 70 80, 90 and 100%) of alcohol. Tissues were then cleared in xylene and infiltrated in paraffin wax. Tissue sections of 4-6 µm thickness were cut from paraffin wax using a rotary microtome, deparaffinized in xylene and thereafter stained with Haematoxylin-Eosin (HE). Histopathological lesions were examined and photomicrographs taken using Olympus Vanox-T microscope with Olympus digital camera (C-2020 Z).

Statistical analysis

Data were analyzed using analysis of variance (ANOVA) and Duncan's multiple range test, to test for different level of treatments and to compare the means, respectively. Test of significance was at 95% confidence limit ($P < 0.05$). The data were presented as mean ± S.E.

RESULTS

Table 1 shows the physicochemical characteristics of the shea butter effluent and the heavy metals contained in the effluent. The brownish coloured effluent had a pH (8.71) higher than both the national and international maximum permissible limits. BOD, COD, chloride, nitrate, phosphate, NH_3, Cd, Pb, Cr, Cu, Fe, Ni and Zn were also higher than NESREA and USEPA standard limits for effluent discharged into water bodies. Ten types of CAs observed at various concentrations of SBE and control groups were chromatid gap, acentric fragment, chromatid and chromosome breaks, sticky, fragment, dicentric and ring chromosomes, chromosome and centromeric gaps (Table 2). There was a gradual and statistically significant ($P < 0.05$) concentration-dependent induction of CAs in the tissues examined. The number of CAs observed in the tissues followed an increasing order: gill(358)>liver(260)>kidney(248). Significantly higher ($P < 0.05$) frequencies of CAs were recorded in all the treated groups compared to the colchine treated groups. Mitotic index was lower in all the tested concentrations compared to the colchine treated. There were significant differences ($P < 0.05$) in MI among the fishes treated with 0.050, 0.055, 0.060 g/l of SBE when compared to those in control groups.

The means and frequencies of chromosomal aberrations in the gill, liver and kidney of *C. gariepinus* exposed to different concentrations of SBE are shown in Tables 3, 4 and 5. At each concentration, the means and frequencies of chromosomal aberrations in each tissue significantly increased ($P < 0.05$) with increase in exposure duration compared to the control groups. Highest means and frequencies of aberrations in the tissues occurred at the highest concentration (0.0060 g/l) of SBE. In the gill, frequency of aberration increased from 38% at day 14 of exposure to 45.32% at day 28 at the highest effluent concentration (Table 3). Similarly, frequency of aberration recorded a peak value in the liver at 0.0060 g/l of SBE (Table 4), but the frequency recorded at day 14 (68.67%) was insignificantly different ($P > 0.05$) from that of day 28 (68.56%), while in the kidney chromosomal aberrations significantly increased from 39.1% at day 14 to 50.6% at day 28 (Table 5). During chronic exposure, the mean number of chromosomal aberration increased in ascending order as follows: liver(610)>kidney(493.98)>gill(275.66). Generally, in all the tissues examined MI values were significantly reduced ($P < 0.05$) compared to the control and the reduction was concentration dependent.

Histological alterations in the gill and liver of *C. gariepinus* exposed to varying concentrations of SBE for 28 days respectively, are shown in Figures 1and 2. In the group treated with borehole water devoid of SBE, there were no observable changes in the gill structure. However, histopathological alterations such as disruption of lamellar core, epithelial lifting, epithelial necrosis, oedema, haemorrhage and lamellar fusion were observed (Fig. 1). Severity of these alterations in the gill architecture became more pronounced as the concentrations of SBE increased. Prominent histological

changes such as increased sinusoidal space, mild vacuolation and fatty degeneration, hyperplasia, hypertrophy and necrosis were observed in the liver of fish exposed to varying concentrations of SBE for 28 days compared to the normal appearance of the liver architecture in control (Fig. 2). These alterations also became severe with increasing concentrations of the effluent.

TABLE 1: Physico-chemical characteristics of the shea butter effluent assessed for genotoxicity.

Parameters*	Effluent sample	[a]NESREA[23]	[b]USEPA[24]
Colour	Brown	-	-
pH	8.75	6.5 – 8.5	6.50-8.50
BOD	156.48	3	250
COD	577.25	90	410
DO	2.81	-	-
TDS	355	500	500
Salinity	427	-	-
Alkalinity	180	150	20
Hardness	50	-	
Chloride	5200	300	250
Nitrate	31.90	10	10
Phosphate	5.40	5.00	-
NH_3	28.53	0.01	-
Cd	0.10	0.005	0.005
Pb	11.00	0.01	0.015
Cr	0.42	0.01	0.10
Cu	1.29	0.001	0.30
Fe	1.30	-	0.30
Mn	0.55	-	
Ni	0.43	0.01	-
Zn	12.40	-	5.00

*All values are in mg/L except pH which has no unit and salinity (ppt.). [a]NESREA-National Environmental Standards and Regulations Enforcement Agency, [b]USEPA-United States Environmental Protection Agency, COD-Chemical oxygen demand, BOD-Biochemical oxygen demand, TDS-Total dissolved solid, DO-Dissolved oxygen

TABLE 2: Frequency of chromosomal aberrations in the tissues of *Clarias gariepinus* exposed to different concentrations of SBE for 96 hrs

Conc. (g/l)	Organs analyzed	No.of dividing cells	MI±SD	CG	AF	CB	CHB	SC	FC	CHG	DC	CMG	RC	Total no. of CA	**Frequency of Aberration (%)**	P-value
Borehole water	Gill	1200	40.00± 0.00^{k}	1	1	0	1	1	0	1	0	0	0	5	0.42	0.0007
	Liver	1101	36.70± 0.00^{j}	1	1	0	1	1	0	1	0	0	0	5	0.45	0.0000
	Kidney	1156	38.53± 0.00^{j}	1	1	0	1	1	0	1	0	0	0	5	0.43	0.0000
0.045	Gill	1065	35.50± 0.00^{i}	0	1	2	4	3	3	2	1	0	5	31	2.90	0.0400
	Liver	1031	32.82 ± 0.22^{h}	2	1	0	1	1	0	0	1	4	1	11	2.41	0.0400
	Kidney	1111	32.54 ± 0.48^{h}	2	0	1	2	1	2	3	1	1	3	16	2.22	0.0000
0.050	Gill	743	26.84 ± 0.16^{g}	3	3	7	5	1	5	3	1	2	10	40	5.38	0.0000
	Liver	792	23..26 ± 5.71^{e}	2	3	2	1	2	2	3	5	5	5	31	3.91	0.1580
	Kidney	800	26.57 ± 0.13^{f}	3	3	7	1	8	0	1	1	7	5	36	4.50	0.6060
0.055	Gill	618	9.68 ± 0.32^{d}	5	10	7	10	17	17	3	14	21	35	125	20.23	0.4010
	Liver	572	7.74 ± 1.59^{b}	4	10	3	8	8	13	7	11	20	30	78	13.64	1.0000
	Kidney	590	9.73 ± 1.76^{d}	3	6	13	12	6	4	17	10	16	25	89	15.08	0.2560
0.060	Gill	518	8.26 ± 0.14^{c}	10	24	26	24	12	8	17	18	10	13	162	31.27	0.1470
	Liver	500	6.59 ± 1.56^{b}	17	04	26	20	25	8	12	4	14	10	140	28.00	0.9950
	Kidney	494	3.51 ± 0.18^{a}	11	30	26	24	20	11	18	12	8	6	107	21.66	1.0000
Colchicine	Gill	425	4.93 ± 0.15^{a}	20	27	23	14	15	20	24	20	18	10	191	44.94	1.0000
	Liver	406	4.29 ± 0.77^{a}	24	23	20	18	14	15	18	19	15	13	178	43.84	1.0000
	Kidney	400	4.08 ± 0.75^{a}	19	20	28	15	10	11	16	22	16	13	169	42.25	1.0000

Values are means ± SE of 3 replicates. Means with different superscripts along the same column are significantly different ($P < 0.05$). MI-mitotic index, CA-chromosomal aberration, CG = chromatid gap, AF = acentric fragment, CB = chromatid break, CHB = chromosome break, SC = sticky chromosome, FC = fragment chromosome, CHG = chromosome gap, DC = dicentric, CMG = centromeric gap, RC = ring chromosome.

TABLE 3: Mean and frequency of chromosomal aberrations in the gill of *Clarias gariepinus* exposed to different concentrations of SBE

Concentration (g/l)	Exposure period (days)	No. of dividing cells	MI±SE	Total no. of CA	Mean CA±SE	Frequency of aberration(%)
Borehole water	14	1685	56.17 ± 0.00^{l}	5	2.67 ± 0.33^{a}	0.30^{a}
	21	1685	56.17 ± 0.00^{l}	5	2.67 ± 0.33^{a}	0.30^{a}
	28	1685	56.17 ± 0.00$_{l}$	5	2.67 ± 0.33^{a}	0.30^{a}
0.0045	14	672	22.43 ± 0.37^{k}	36	12.00 ± 1.20^{b}	5.36^{b}
	21	650	21.67 ± 0.06^{j}	43	14.33 ± 2.52^{c}	6.62^{c}
	28	601	20.03 ± 0.00^{j}	46	15.33 ± 3.76^{c}	7.65^{c}
0.0050	14	609	20.30 ± 0.16^{j}	44	14.67 ± 1.76^{c}	7.72^{c}
	21	505	16.83 ±0.09^{i}	54	18.00 ± 4.72^{d}	10.69^{d}
	28	496	16.53 ± 0.12^{i}	60	20.00 ± 1.00^{e}	12.10^{e}
0.0055	14	290	9.67 ± 0.18^{g}	79	26.33 ± 2.73^{f}	27.24^{f}
	21	307	9.81 ± 0.20^{g}	91	30.33 ± 1.20^{g}	29.64^{g}
	28	301	10.03 ± 0.12^{h}	94	31.33 ± 1.20^{g}	31.23^{h}
0.0060	14	248	8.26 ± 0.04^{e}	90	30.00 ± 1.00^{g}	38.00^{i}
	21	225	7.50 ± 0.04^{f}	98	32.67 ± 1.45^{h}	43.56^{j}
	28	203	6.77 ± 0.37^{d}	92	30.67 ± 2.91^{g}	45.32^{k}
Colchicine	14	212	4.93 ± 0.04^{a}	95	31.67 ± 2.31^{g}	44.81^{k}
	21	220	4.17 ± 0.04^{a}	105	35.00 ± 0.45^{h}	47.73^{l}
	28	225	4.00 ± 0.37^{a}	111	37.00 ±0.18^{i}	49.33^{m}

Values are means ± SE of 3 replicates. Means with different superscripts along the same column are significantly different ($P < 0.05$). MI-mitotic index, CA-chromosomal aberration.

TABLE 4: Mean and frequency of chromosomal aberrations in the liver of *Clarias gariepinus* exposed to different concentrations of SBE

Concentration (g/l)	Exposure period (days)	No. of dividing cells	MI±SE	Total no. of CA	Mean CA±SE	Frequency of aberration(%)
Borehole water	14	1685	56.17 ± 0.00^{g}	5	2.67 ± 0.33^{a}	0.30^{a}
	21	1685	56.17 ± 0.00^{g}	5	2.67 ± 0.33^{a}	0.30^{a}
	28	1685	56.17 ± 0.00^{g}	5	2.67 ± 0.33^{a}	0.30^{a}
0.0045	14	985	32.83 ± 0.13^{f}	80	26.67 ± 2.60^{b}	8.12^{b}
	21	954	31.80 ± 0.15^{f}	101	33.67 ± 1.20^{c}	10.59^{c}
	28	933	31.10 ± 0.13^{f}	125	41.67 ± 4.91^{d}	13.40^{d}
0.0050	14	794	26.47 ± 0.08^{e}	98	32.67 ± 0.88^{c}	12.34^{e}
	21	788	26.27 ± 0.03^{e}	136	46.67 ± 3.84^{e}	17.25^{f}
	28	762	25.40 ± 0.24^{e}	151	51.00 ± 1.45^{f}	19.82^{g}
0.0055	14	496	16.53 ± 0.11^{d}	155	51.67 ± 1.45^{f}	31.25^{h}
	21	439	14.63 ± 0.18^{c}	178	59.33 ± 1.86^{h}	40.55^{i}
	28	412	13.73 ± 0.16^{c}	172	57.33 ± 2.08^{g}	41.75^{i}
0.0060	14	249	8.28 ± 0.12^{b}	171	57.00 ± 1.53^{g}	68.67^{j}
	21	347	8.23 ± 0.08^{b}	228	76.00 ± 1.15^{i}	65.70^{k}
	28	334	7.80 ± 0.22^{b}	229	76.33 ± 1.15^{i}	68.56^{l}
Colchicine	14	345	4.78 ± 0.06^{a}	236	78.67 ± 4.06^{i}	68.41^{l}
	21	450	4.99 ± 0.05^{a}	243	81.00 ± 0.58^{j}	54.02^{j}
	28	382	4.74 ± 0.22^{a}	248	82.67 ± 1.20^{j}	64.92^{k}

Values are means ± SE of 3 replicates. Means with different superscripts along the same column are significantly different ($P < 0.05$). MI- mitotic index, CA-chromosomal aberration

TABLE 5: Mean and frequency of chromosomal aberrations in the kidney of *Clarias gariepinus* exposed to different concentrations of SBE

Concentration (g/l)	Exposure period (days)	No. of dividing cells	MI±SE	Total no. of CA	Mean CA±SE	Frequency of aberration(%)
Borehole water	14	1685	56.17 ± 0.00^{i}	5	1.67 ± 0.33^{a}	0.30^{a}
	21	1685	56.17 ± 0.00^{i}	5	1.67 ± 0.33^{a}	0.30^{a}
	28	1685	56.17 ± 0.00^{i}	5	1.67 ± 0.33^{a}	0.30^{a}
0.0045	14	976	32.53 ± 0.28^{h}	44	15.50 ± 0.50^{b}	10.12^{b}
	21	951	31.70 ± 0.05^{g}	73	24.33 ± 2.03^{c}	12.09^{c}
	28	906	30.20 ± 0.10^{g}	117	39.00 ± 4.73^{f}	12.40^{c}
0.0050	14	797	26.57 ± 0.08^{f}	117	36.33 ± 2.08^{e}	14.7^{d}
	21	794	26.46 ± 0.12^{f}	166	39.33 ± 0.58^{f}	20.9^{e}
	28	753	31.76 ± 0.05^{g}	164	41.00 ±0.84^{g}	21.8^{e}
0.0055	14	592	19.73 ± 0.19^{e}	127	39.50 ± 5.50^{f}	21.5^{e}
	21	491	16.37 ± 0.07^{d}	152	50.33 ± 2.19^{h}	30.6^{f}
	28	477	15.90 ± 0.24^{d}	169	54.67 ± 1.86^{j}	35.4^{g}
0.0060	14	302	10.07 ± 0.17^{c}	118	42.33 ± 0.50^{g}	39.1^{h}
	21	246	8.20 ± 0.09^{c}	109	55.33 ± 2.19^{i}	44.3^{i}
	28	243	8.10 ± 0.08^{c}	123	56.33 ± 1.20^{i}	50.6^{j}
Colchicine	14	186	6.20 ± 0.07^{b}	95	31.67 ± 2.00^{d}	51.1^{j}
	21	143	4.77 ± 0.11^{a}	95	31.67 ± 2.00^{d}	51.1^{j}
	28	112	3.73 ± 0.84^{a}	95	31.67 ± 2.00^{d}	51.1^{j}

Values are means ± SE of 3 replicates. Means with different superscripts along the same column are significantly different ($P < 0.05$). MI-mitotic index, CA-chromosomal aberration.

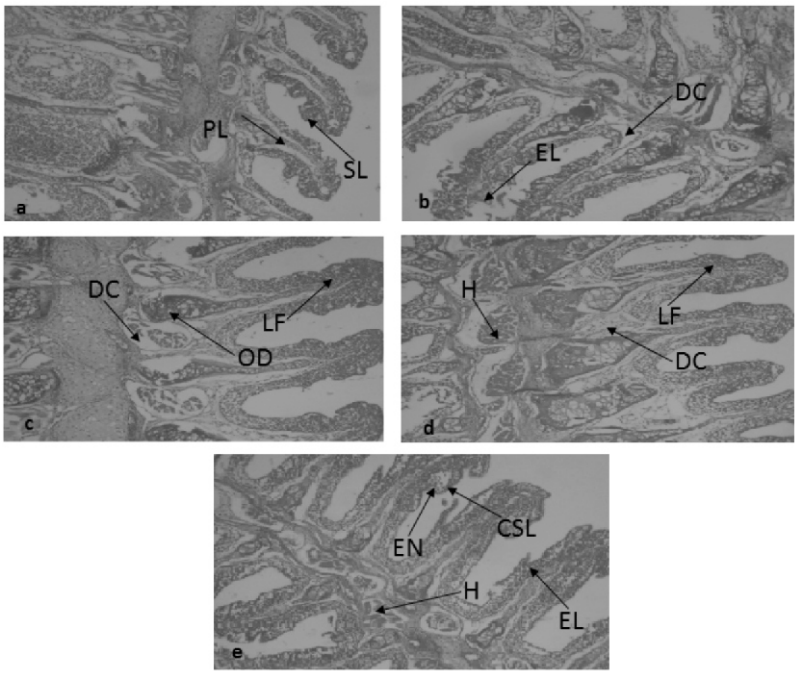

Fig. 1a-e (H & E X400): Histopathological alterations in the gill of *C. gariepinus* exposed to varying concentrations of Shea butter effluent for 28 days. (a) Gill of *Clarias gariepinus* in the control experiment showing normal appearance of primary lamella (PL) and secondary lamella (SL); (b) Gill of fish exposed to 0.0045 g/l SBE showing epithelial lifting (EL) and disruption of lamella core (DC); (c) Gill of fish exposed to 0.0050 g/l SBE lamella fusion (LF), oedema (OD) and disruption of lamellar core (DC); (d) Gill of fish exposed to 0.0055 g/l SBE showing lamella fusion, haemorrhage (H) and disruption of lamella core (DC); (e) Gill of fish exposed to 0.0060 g/l SBE showing epithelial necrosis (EN), epithelial lifting (EL), haemorrhage (H) and coiling of secondary lamellar (CSL).

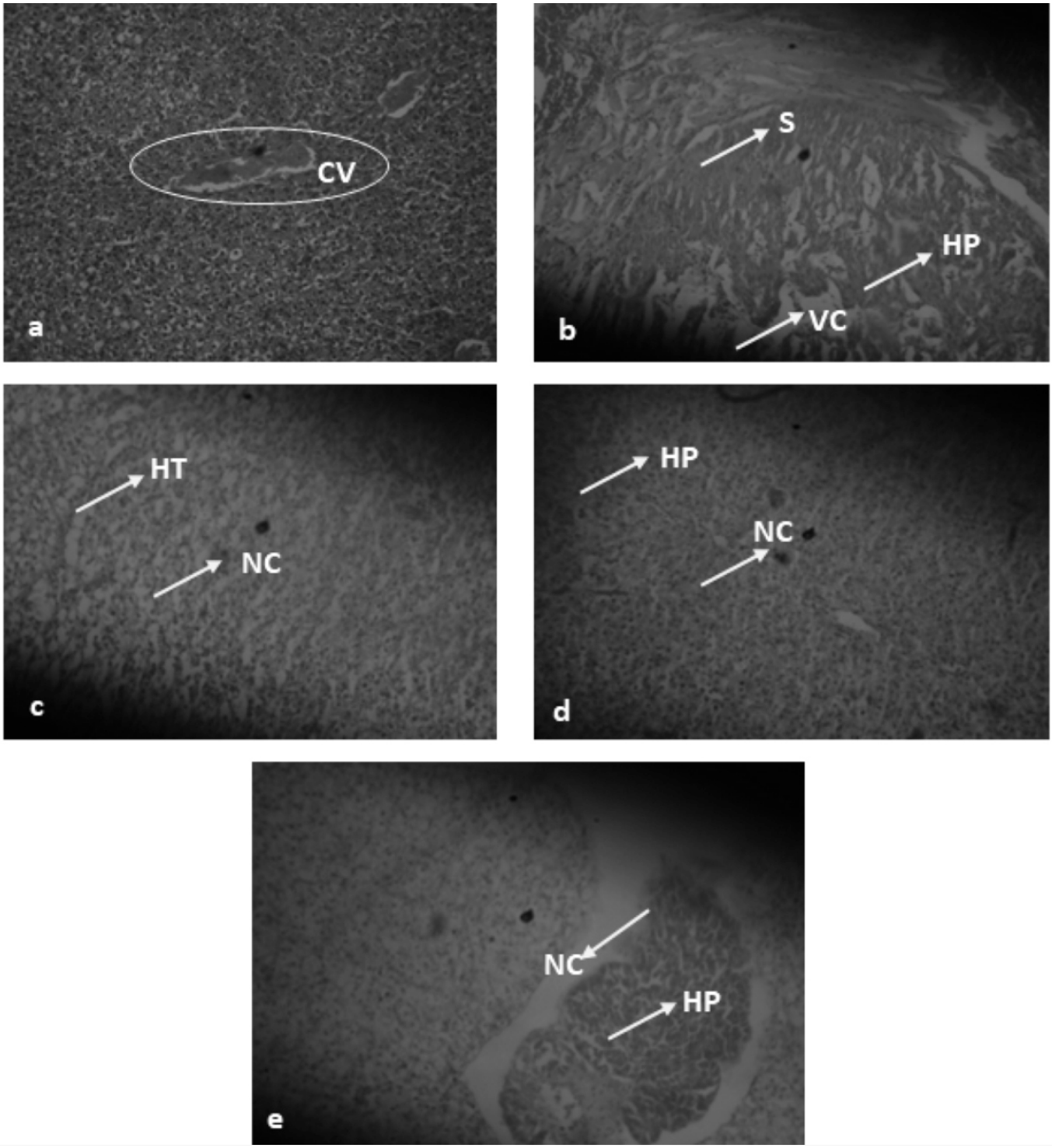

Fig. 2a-e (H&E X400): Histopathological alterations in the liver of *Clarias gariepinus* exposed to varying concentrations of Shea butter effluent for 28 days. (a) Liver of *Clarias gariepinus* in the control experiment showing normal hepatocytes with central vein; (b) Liver of fish exposed to 0.0045 g/l SBE showing sinusoidal space (S), mild vacuolation and fatty degeneration (VC) and hyperplasia (HP); (c) Liver of fish exposed to 0.0050 g/l SBE showing hypertrophy (HT) and necrosis; (d) Liver of fish exposed to 0.0055 g/l SBE showing hyperplasia (HP) and necrosis (NC); (e) Liver of fish exposed to 0.0060 g/l showing hyperplasia (HP) and necrosis (NC).

DISCUSSION

The results of this study reveal the induction of chromosomal and histopathological changes in the tissues of *C. gariepinus* upon exposure to varying concentrations of effluent from Shea butter processing industry. In literature, there is currently a dearth of documented information on the genotoxic and cytotoxic effects of SBE on *C. gariepinus*. This study is, therefore, the first attempt to evaluate the possible genotoxic effects of SBE in fish in order to provide a baseline data that may be useful for public health officials and related environmental agencies in their quests to minimize or eradicate aquatic pollution due to SBE. These findings indicate that toxic substances present in SBE may have inhibited mitotic cell division and thus explained the significant and concentration-dependent increase in frequency of CA observed in all the tissues examined. This is evident from the MI values found to be significantly lower ($P < 0.05$) in comparison with the group treated with borehole water. The observed significant increase in frequency of CA with increasing effluent concentration and exposure period in the treated fish, is in agreement with previous reports. [25, 26]

The induction of CA has been suggested to be as a result of DNA strand breaks which occur through many cellular processes such as DNA replication and DNA excision repair[27] and error in these two processes has been suggested to induce CA. DNA strand breaks are known to be potentially hazardous to cells as they can cause genome rearrangements.[27] Aquatic environments are the ultimate recipients of many agrochemicals through run off which could interact with DNA and cause gene mutations or genetic disease in fish.[28] The degree of sensitivity of each organ to SBE toxicity appear to differ with the highest frequency of CA being recorded in the gill followed by the liver and kidney during acute exposure, while the liver showed the highest CA followed by the kidney and gill during chronic exposure. This is rather strange as the kidney is the haematopoeitic organ of fish and it is expected that more cells could be prone to aberrations than the gills and the liver. The probable accumulation of SBE in the gill and liver more than the kidney may account for the higher number of chromosomal aberrations in these organs. The gill is the first major site of accumulation of chemical toxicants, while the liver is the main organ involved in the metabolism of xenobiotic. The continuous discharge of this effluent into the environment may be hazardous not only to the environment but also to resident fish species.

Wastewater from agrobased industry is known to contain genotoxic and mutagenic agents which may accumulate in fish organs and cause devastating effects to aquatic organisms. The bioaccumulation of these clastogenic chemicals in fish and other aquatic organisms may be transfered to other organisms at higher trophic levels through the food chains and could also pose serious threat to human health. Among the genotoxic and mutagenic agents that have been implicated in the induction of tumors in experimental animals and humans are heavy metals.[29] The chromosomal abnormalities observed in this study may have been due to structural changes such as deletion, duplication and replication during repair. The heavy metal constituents of the SBE are suggestive of clastogenic chemicals which could induce oxidative stress through the formation of reactive oxygen species and electrophilic radicals. The possible accumulation of these heavy metals in the tissues examined might have resulted in the formation of free radicals which upon reaction with DNA caused the chromosomal abnormalities observed. These abnormalities may subsequently cause genetic disorders, reproductive impairement, reduction of fitness and loss of biodiversity in aquatic organisms.[28] Similar studies have implicated heavy metals in the distruption of DNA duplication process, nucleotide synthesis interference and misreplication of damaged DNA resulting into malformation of DNA molecules.[30-32]

The presence of Cd, Pb, Cr, Cu, Fe, Ni and Zn in SBE above the permissible limit is indicative of the effluent toxicity, which may threaten fish survival. It has been reported that these metals could induce clastogenic and aneugenic effects in organisms.[33] Cd, Cu, Pb and Zn are known to cause cytogenetic effects due to their ability to inhibit enzyme and induce genome damage.[34-37] The presence of high concentrations of heavy metals in this study is consistent with previous reports,[4, 38] where the concentrations of Cu, Fe and Zn in wastewater effluent from cocoa processing industry exceeded the maximum permissible limits. Compared to the local (NESREA) and international regulatory standards (USEPA), the low concentration of DO and the high concentrations of BOD and COD observed in the effluent further suggest that the effluent may portend serious danger to aquatic biota upon exposure. Presently, there is paucity of information on the genotoxicity effects of SBE on aquatic biota, although a number of reports similar to the present

observations have also provided evidences to show that industrial effluents other than SBE may be genotoxic to exposed animals. [39-42]

Histopathological assessment of tissues is a recognized, sensitive and reliable method of detecting effects of toxicants in organs.[43] Histological lesions in exposed animals could serve as warning signals for the animal's well being. The various histopathological changes observed in the gill and liver of *C. gariepinus* indicate that SBE is toxic to the fish. This observation is consistent with previous report [9] which showed that the higher the concentration of SBE, the more severe the degree of damage in fish tissues. The gill is the first organ with which fish maintains a close contact with its surroundings and with its characteristic filaments and lamellae, a large surface area is created for oxygen absorption and uptake of metals; thus making the gill the major site of action of environmental pollutants.[44] The liver with its close proximity to blood supply,[45] does not only facilitates detoxification of xenobiotics, but also allows the hepatic tissue to be exposed to water contaminants.[46] This may, therefore, explain the histological deformities observed in both organs. These deformities could impair the normal functioning of the gill and liver and could also trigger other functional problems in other organs of the fish such as the kidney. Furthermore, the accumulation of toxic metals present in the SBE might have resulted into formation of reactive oxygen species (ROS) which induced the deformities.[47] Since alterations of the liver have been linked with gill and kidney alterations,[48] it is plausible that the deformities in the tissues examined may also account for the observed high frequency of CA. If this is the case, the differences observed in the frequency of CA in each of the organ examined are suggestive of organ-specific adaptive responses due to the severity of damage and the differential metabolic capacity of each organ to tolerate the toxicant. The observed histopathological disorders are typical of those caused by metal toxicity in fish.[49, 50] Such alterations have also been previously reported in fish exposed to minning effluent,[51] tannery [52] and paint wastewater.[18] The present study is not without some challenges which could pave way for future direction if resolved. First, this study may not fully depict the situation in natural water bodies, hence the need to understand the persistence nature of shea butter effluent in aquatic ecosystems for accurate risk assessment. Second, the use of confocal microscope instead of light microscope used in this study could further enhance a better identification of the various chromosomal aberrations observed. Furthermore, the adoption of DNA fragmentation assay could give a better and undoubtful insight into the types of damage at both chromosomal and DNA levels regardless of whether the organs/tissues investigated contain actively dividing cells or not.

CONCLUSION

This study has revealed that SBE contained heavy metals and other constituents in larger amounts than the maximum permissible limits by regulatory authorities. These metals and other constituents of the effluent are clastogenic and capable of inducing various chromosomal and histological abnormalities in the tissues of *C. gariepinus* upon exposure to even low concentrations of the toxicant. These results also show that the release of SBE into waterbodies, without treatment, could pose a serious threat to the survival and reproductive potential of aquatic organisms and also to humans who are exposed to the effluent and/or depend on these organisms for source of protein.

ACKNOWLEDGEMENT

The authors are grateful to Prof. S.O. Adewoye for his assistance in the collection of effluent. We also acknowledge with thanks the assistance of our students during the experimental work.

REFERENCES

1. Al-Sabti K. (1995). An in vitro binucleated blocked hepatic cell technique for genotoxicity testing in fish. *Mutation Research* 335 109-120.
2. Garba ID, Sanni SA, Adebayo CO (2015). Analyzing the structure and performance of shea butter market in Bosso and Borgu Local Government Areas of Niger State, Nigeria. *International Journal of U-and E-Service, Science and Technology* 8 (2): 321-336.
3. Cole DW, Cole R, Gaydos SJ, Gray J, Hyland G, Jacques ML, Powell-Dunford N, Sawhney C, Au WW (2009). Aquaculture: environmental, toxicological, and health issues. *International Journal of Hygiene and Environmental Health* 212: 369-377.
4. Alabi AO, Esan EB, Olorunfemi JT, Oludare OE (2017). Assessment of environmental contamination by wastewater from a cocoa processing industry using genetic and

reproductive biomarkers. *Journal of Toxicology and Risk Assessment* 3 (1): 008.

5. Yoon Y, Cao X, Zhou Q, Ma LQ (2006). Accumulation of Pb, Cu and Zn in antive plants growing on a contaminated Florida site. *Science of the Total Environment* 368: 456-464.
6. Grover IS, Kaur S (1999). Genotoxicity of wastewater samples from sewage and industrial effluent detected by the *Allium cepa* root anaphase aberration and micronucleus assays. *Mutation Research* 426: 183-188.
7. Sharma P, Marthur N, Singh A (2012): Genotoxicity of health care wastewaters: a review. *Research Journal of Chemistry and Environment* 16: 116-124.
8. Adewoye SO, Adedigba AE, Opasola OA (2013a). Impact of shea butter effluent on biochemical and haematological profiles of *Clarias gariepinus*. *Journal of Environmental Science, Toxicology and Food Technology* 5(1): 59-63.
9. Adewoye SO, Adedigba AE, Opasola OA (2013b). Effect of sublethal concentrations of shea butter effluent on the architectural layout of selected organs of *Clarias gariepinus*. *International Journal of Zoology and Research* 3(3): 45-54.
10. Hayler GS (1993). Aspects of the biology and culture of the African catfish, *Clarias gariepinus* (Burchell 1822) with particular reference to developing African countries. In: Minor JF, Roberts RJ (Eds), *Research Advances in Aquaculture IV*. pp 235-291.
11. Cavas T, Könen S (2007). Detection of cytogenetic and DNA damage in peripheral erythrocytes of goldfish (*Carassius auratus*) exposed to a glyphosate formulation using the micronucleus test and the comet assay. *Mutagenesis* 22: 263-268.
12. Manas F, Peralta L, Raviolo J, Ovando HG, Weyers A, Ugnia L, Cid MG, Larripa I, Gorla N (2009). Genotoxicity of glyphosate assessed by the comet assay and cytogenetic tests. *Environmental Toxicology and Pharmacology* 28: 37-41.
13. Guiherme S, Gaivao I, Santos MA, Pacheco M (2010). European eel (*Anguilla anguilla*) genotoxic and proxidant responses following short-term exposure to roundup-a glyphosate-based herbicide. *Mutagenesis* 25 (5): 523-530.
14. Guiherme S, Gaivao I, Santos MA, Pacheco M (2012). DNA damage in fish (*Anguilla anguilla*) exposed to a glyphosate-based herbicide-elucidation of organ specificity and the role of oxidative stress. *Mutation Research-General Toxicology and Environmental Research* 743: 1-9.
15. Adewoye SO, Fawole OO, Owolabi OD and Omotosho JS (2005). Toxicity of cassava wastewater effluents to African Catfish, *Clarias gariepinus*. *Ethiopian Journal of Science* 28 (2):189-194.
16. Ogundiran MA, Fawole OO, Adewoye SO, Ayandiran TA (2009). Pathologic lesions in the gills of *Clarias gariepinus* exposed to sublethal concentrations of soap and detergent effluents. *Journal of Cell and Animal Biology* 3 (5):78-82.
17. Agboola OA, Fawole OO (2014). Chronic toxicity of pharmaceutical effluent in *Clarias gariepinus* (Burchell, 1822). *Convenant Journal of Physical and Life sciences* 1:27-42.
18. Owolabi OD, Adewoye SO (2017). Paint wastewater induced histopathological changes in the gill and liver of African catfish, *Clarias gariepinus* (Burchell, 1822). *Ilorin Journal of Science* 4 (1): 47-60.
19. APHA (American Public Health Association)(2005). Standard methods for examination of water including bottom sediments and sludges. Standard Methods, 19th edn. p 874.
20. USEPA (United StatesEnvironmental Protection Agency)(1996). Acid Digestion of Sediments, Sludge and Soils, Method-3050B. USEPA: Washington, DC.
21. OECD (Organization of Economic Coorperation and Development)(2002). Guidelines for testing of chemicals, Guideline no. 203: fish, acute toxicity test.
22. Nagpure NS, Kumar R, Kushwaha B, Singh, PJ, Srivastava SK(2007). Genotoxicity assessment in fishes, a practical approach: National Bureau of Fish Genetic Resource, Lucknow, India 63 p.
23. NESREA (National Environmental Standards and Regulations Enforcement Agency)(2011). National Environmental (Surface and Groundwater quality) Regulations. National

Environmental Standards and Regulations Enforcement Agency.
24. USEPA (United States Environmental Protection Agency)(2011). Maximum permissible limit for effluents from waste water. http://www.epa.gov/ safewater/ mcl.html
25. Yadav KK, Trivedi SP (2009). Chromosomal aberrations in a fish, *Channa punctata* after in vivo exposure to three heavy metals. *Mutation Research* 678:7-12.
26. Kaur H, Kalotra R, Walia GK, Handa D (2013). Genotoxic effects of dyeing industry effluent on a freshwater fish, *Cirrhinus mrigala* by chromosomal aberration test. *International Journal of Pharmacy and Biological Sciences* 3 (1): 423-431.
27. Srivastava P, Singh A, Pandey AK (2016). Pesticides toxicity in fishes: Biochemical, physiological and genotoxic aspects. *Biochemical and Cellular Archives* 16 (2): 199-218.
28. Kurelec B (1993). The genotoxic disease syndrome. *Marine Environmental Research* 35 (4): 314-348.
29. Minissi S, Lombi E (1997). Heavy metal content and mutagenic activity evaluated by Vicia faba micronucleus test of Triber River sediments. *Mutation Research* 393: 17-21.
30. Evans HJ (1977). Molecular mechanisms in the induction of chromosome aberrations. In: Scott D, Bridges BA (Eds), Sobier/North Holland, Amsterdam, pp. 57-74.
31. Landolt ML, Kocan RM (1983). Fish cell cytogenetics: A measure of genetoxic effects of pollutants. In: Nriagu JO (eds), Aquatic Toxicology. John Wiley and Sons Inc, pp. 335-352.
32. Matter EE, Elserafy SS, Zowail MEM, Awwad MH (1992). Genotoxic effect of carbamyl insecticide on the grass carp, *Ctenopharygodon idella*. *Egyptian Journal of Histology* 15 (1): 9-17.
33. Dovgaliuk AI, Kaliniiak TB, Blium IAB (2001). Assessment of phyto-and cytotoxic effects of heavy metals and aluminium compounds using onion apical meristem. *Tsitologia Genetic* 35: 3-9.
34. Dash S, Panda KK, Panda BB (1988). Biomonitoring of low levels of mercurial derivatives in water and soil by *Allium* micronucleus assay. *Mutation Research* 203: 11-21.
35. Johnson FM (1998). The genetic effects of environmental lead. *Mutation Research* 410: 123-140.
36. Evseeva TI, Geras K, Khramova ES (2001). Cytogenetic effects of separate and combined action of 232Th and Cd nitrates on *Allium cepa* root meristema cells. *Tsitologia* 43: 803-808.
37. El-Shahaby AO, Aabdel-Migid HM, Soliman MI, Mashaly IA (2003). Genotoxicity screening of industrial wastewater using Allium cepa chromosome aberration assay. *Pakistan Journal of Biological Sciences* 6: 23-28.
38. Akinnusotu A, Arawande JO (2016). Qualities of effluents from three cocoa processing factories in Ondo State. *International Journal of Environment and Bioengineering* 11: 24-35.
39. Bakare AA, Alabi OA, Adetunji OA and Jenmi HB (2009). Genotoxicity assessment of a pharmaceutical effluent using four bioassays. *Genetics and Molecular Biology* 32(2): 373-381.
40. Alimba CG, Saliu JK, Adesanya A, Bakare AA (2011). Evaluation of genotoxicity of a municipal landfill leachate by micronucleus test using *Clarias gariepinus*. *Research in Environment and Life Sciences* 4 (1): 1-6.
41. Ayoola SO, Bassey BO, Alimba CG, Ajani EK (2012). Textile effluent induced genotoxic effects and oxidative stress in *Clarias gariepinus*. *Pakistan Journal of Biological Sciences* 15 (17): 804-812.
42. Bakare AA, Alabi OA, Gbadebo AM, Ogunsuyi OI, Alimba CG (2013). *In vivo* cytogenotoxicity and oxidative stress induced by electronic waste leachate and contaminated well water. *Challenges* 4 (2): 169-187.
43. Lanning LL, Creasy DM, Chapin RE, Mann PC, Barlow NJ,Regan KS, Goodman DG (2002). Recommended approaches for the evaluation of testicular and epididymal toxicity. *Toxicologic Pathology* 30: 507-520.
44. Wood CM, Kelly SP, Zhou B, Fletcher M, O'Donnell M, Eletti B, Part P (2002). Cultured gill epithelia as models for the freshwater fish gill. *Biochemical and Biophysical Acta* 1566: 72-83.
45. Hinton DE, Lauren DJ (1990). Integrative

histopathological approaches to detecting effects of environmental stressors on fishes. *American Fish Society Symposium* 8: 51-66.

46. Camargo MM, Martinez C (2007). Histopathology of gills, kidney and liver of a Neotropical fish caged in an urban stream. *Neotropical Ichthyology* 5 (3): 327-336.
47. Farombi EO, Adelowo OA, Ajimoko YR (2007). Biomarkers of oxidative stress and heavy metal levelsas indicators of environmental pollution in African catfish (*Clarias gariepinus*) from Ogun River, Nigeria. *International Journal of Environmental Research and Public Health* 4: 158-165.
48. Lindstoma-Seppa P, Koivussri V, Hanninen O (1981). Extrahepatic xenobiotic metabolism in north European freshwater fish. *Comparative Biochemistry and Physiology Part C: Comparative Pharmacology* 69: 291.
49. Younis EM, Abdel-Warith AA, Al-Asgah NA Ebaid H, Mubarak M (2013). Histological changes in the liver and intestine of Nile Tilapia, *Oreochromis niloticus* exposed to sublethal concentrations of cadmium. *Pakistan Journal of Zoology* 45 (3): 833-841.
50. Otludil B, Karadede Akin H, Unlu E (2017). Effects of sub-lethal exposure of cadmium on histopathology of gills of Nile tilapia, *Oreochromis niloticus* and the mitigating effects of *Cladophora glomerata. Acta Biologica Turcica* 30 (1): 24-30.
51. Tkatcheva V, Hyvarinen H, Kukkonen J, Ryzhkov LP, Holopainen IJ (2004). Toxic effects of minning effluents on fish gills in subarctic lake system in NW Russia. *Ecotoxicology and Environmental Safety* 57: 278-289.
52. Navaraj PS, Yasmin J (2012). Toxicological evaluation of tannery industry waste water on *Oreochromis mossambicus*, *African Journal of Environmental Science and Technology* 6 (9): 331-336.