(https://www.j
criteria/inacti
title)

(https://www.a
letter=oa)

Journal of Experimental and Clinical Anatomy

Journal / Journal of Experimental and Clinical Anatomy (/index.php/jeca) / About the Journal



The *Journal of Experimental and Clinical Anatomy* accepts for publication manuscripts of high standard containing reports of original scientific research in the morphology, mechanical functioning and development of man and animals. The scope the journal embraces articles of human and comparative anatomy, embryology, histology, histochemistry, neurology and functional aspects of eh anatomical sciences. As a publication with background on pure and applied research, the journal recognizes the importance of descriptive studies in the morphological aspects of molecular, cellular, systems and evolutionary biology. Clinical updates and case reports relating to consequences of disruption of cells, tissues or organ architecture will be published.

The journal website can be found here: https://jecajournal.com/ (https://jecajournal.com/)

Current Issue: Vol. 22 No. 1 (2025)

Published: 2025-03-31

Articles

Chloroform fruit extract of *Phoenix dactylifera* L. (Date Palm) has neuroprotective effect against lead acetate-induced neurotoxicity in Wistar rats (https://www.ajol.info/index.php/jeca/article/view/292296)

A.N. Agbon, Z.S. Sambo, H.S. Tukura, T.H. Adetoye, O.A. Adeola, Y.M. Shuaib, R. Henry, O. Mahdi, K.A. Bobbo, F.U. Enemali, S.S. Lazarus, M.G. Abubakar

1-11

DOWNLOAD PDF (HTTPS://W

Cannabinoid exposure during pregnancy: consequences for growth, memory and prefrontal cortex integrity in Wistar Rats (https://www.ajol.info/index.php/jeca/article/view/292299)

I.A. Suleiman, D.O. Taiwo-Ola, O.O. Odubela, P.B. Fakunle, O.F. Shallie, K.M. Abdulsalam, L.A. Adelakin, M.E. Oresanya, P.O. Idowu, P.D. Shallie

12-21

DOWNLOAD PDF (HTTPS://W

Zingiber officinale-supplemented diet reversed lead-induced oxidative stress and cerebral cortex injuries in adult female Wistar rats (https://www.ajol.info/index.php/jeca/article/view/292303)

F.O. Ojo, L.A. Hassan, O.S. Olaniyi, R.T. Lawal, M.B. Lawal, E.K. Adetoro

22-26

DOWNLOAD PDF (HTTPS://W

Investigation of inheritance pattern of palmar creases among the Urhobo and Ogoni Ethnic Groups in South-South Nigeria (https://www.ajol.info/index.php/jeca/article/view/292305)
T.C. Omuruka, K.P. Godson
27-38

DOWNLOAD PDF (HTTPS://W

Using the anteroposterior diameter of C3-C7 spinal canals to assess cervical stenosis among Ghanaian males: An anatomical study (https://www.ajol.info/index.php/jeca/article/view/292306)
A.A. Brown
39-43

DOWNLOAD PDF (HTTPS://W

Investigating cerebellar oxidative stress, inflammation and apoptosis following sub-acute MPTP administration in Balb/c mice (https://www.ajol.info/index.php/jeca/article/view/292308)
F.A. Sulaimon, R.A. Adeniyi, O.A. Akinnaso, O.A. Oladipupo, M.J. Awodola, A.T. Adeoye, T.Y. Jimoh, M. Shehu, A.L. Imam, R.Y. Ibiyeye
44-50

DOWNLOAD PDF (HTTPS://W

Effects of aqueous fruit extracts of *Adansonia digitata* on lead acetate-induced hippocampal toxicity on adult *Rattus Norvegicus* (https://www.ajol.info/index.php/jeca/article/view/292314)
A. Sunusi, R.I. Fage, A. Gudaji, I.A. Tela, S.M. Umar, B.M. Ibrahim
51-60

DOWNLOAD PDF (HTTPS://W

The Role of histo-taphonomy in postmortem interval estimation: A preliminary study of porcine liver and kidney (https://www.ajol.info/index.php/jeca/article/view/292309)
C.O. Obun, O.A. Ibegbu, A.O. Ogugua, C.N. Esomchi, J.O. Ikpa, M. Adie, D.N. Onyejike, C.E. Anwara
61-66

DOWNLOAD PDF (HTTPS://W

Protective Potential of Aqueous Extract of Turmeric on the Cognitive Function of Adult Female Wistar Rats Administered with Co-Codamol (https://www.ajol.info/index.php/jeca/article/view/292311)
B.O. Abe, L.G. Ogungbe, C.B. Jolaosho, A.M. Ayoola, O.M. Olutunde, O.O. Agboola, D.T. Ovioke, E.A. Adesanya, O.M. Abe
67-72

DOWNLOAD PDF (HTTPS://W

Histological features of the uterine tubes following administration of aqueous tobacco extract in female albino rats (https://www.ajol.info/index.php/jeca/article/view/292324)
D.O. Omondi, J. Kigera, A. Pulei, J. Munguti
73-79

DOWNLOAD PDF (HTTPS://W

Cytological assessment of sputum smear and total blood count of workers in wood and timber industries (https://www.ajol.info/index.php/jeca/article/view/292326)
T.I.A. Onwunumagha, M.C. Mbam, C.A. Okoronkwo, S.O. Okoronkwo, J.O. Ikpa
80-86

DOWNLOAD PDF (HTTPS://W

Effect of lauric acid on some of the hematological parameters and indices in male Wistar rats exposed to sleep deprivation (https://www.ajol.info/index.php/jeca/article/view/292331)
O.M. Avidime, I. Suleiman, F.M. Oduneye
87-91

DOWNLOAD PDF (HTTPS://W

Impact of Potassium Sorbate on Cognitive Performance and Hippocampal Morphology in Wistar Rats (https://www.ajol.info/index.php/jeca/article/view/292333)
M.Y. Adana, K. Lawal, O.G. Onigbolabi, S. Akintola
92-104

DOWNLOAD PDF (HTTPS://W

Histological evaluation of wound healing potential of pods of *Acacia nilotica* aqueous and methanol extracts in rats (https://www.ajol.info/index.php/jeca/article/view/292334)
I. Mohammed, Y. Salihu, M.O. Musa, A.M. Tnagaza, A. Usman, R.I. Tsamiya, S. Ijaz, G. Hassanzadeh
105-115

DOWNLOAD PDF (HTTPS://W

Correlation of intercanine distance with bizygomatic width and intercanthal distance in Nigerian population (https://www.ajol.info/index.php/jeca/article/view/292347)
C.M. Okeke, O.J. Chukwuka, I.C. Enemuo
116-119

DOWNLOAD PDF (HTTPS://W

Modulatory effects of aqueous rhizome extract of *Zingiber officinale* on oxidative stress, inflammation, and steroidogenesis in alcohol-induced testicular damage in Wistar rats (https://www.ajol.info/index.php/jeca/article/view/292349)
C.N. Esomchi, J.O. Nwofia, A.M. Chukwu, E.E. Chukwuka, T.C. Ejezie, C.J. Emelife, S.U. Elu-Idam, I.M. Egwudike, A.O. Egwu
120-126

DOWNLOAD PDF (HTTPS://W

Measuring body fat percentage using anthropometric skinfolds with different methods and investigating the outcomes of the methods: a case study of secondary school students in Lagos State (https://www.ajol.info/index.php/jeca/article/view/292356)
H.A. Omotayo, M.T. Omotayo, L.K. Saibu
127-132

DOWNLOAD PDF (HTTPS://W

Assessment of nutritional parameters and socioeconomic status among menopausal women with type II diabetes in Lagos Mainland, Lagos State, Nigeria (https://www.ajol.info/index.php/jeca/article/view/292358)
F.O. Opoola, S.S. Adebisi, J.P. Tanko, S.A. Akuyam, H.A. Omotayo, M. Nwankwo
133-140

DOWNLOAD PDF (HTTPS://W

Effect of methanol leaf extract of *Nicotiana tabacum* (tobacco) on long-term memory in Wistar rats (https://www.ajol.info/index.php/jeca/article/view/292365)
A.O. Wahab, J. Ochai, Y. Yusha'u, S. Adeyemi, S.B. Muhammad, M.A. Okunlola, A.S. Ezekiel, S.I. Ugbir, A.A. Omoniyi, S.M. Abubakar, A.O. Quawiyah
141-147

DOWNLOAD PDF (HTTPS://W

Determination of sex from clavicular and scapular parameters from normal posteroanterior chest radiographs of adults in Bayelsa State, Nigeria (https://www.ajol.info/index.php/jeca/article/view/292400)
T.O. Johnbull, N.C. Onyema
148-153

DOWNLOAD PDF (HTTPS://W

Ameliorative effects of aqueous extract of fermented unripe *Musa paradisiaca* pulp on alcohol-induced gastric and duodenal ulcers in adult male Wistar rats (https://www.ajol.info/index.php/jeca/article/view/292404)
C.E. Anwara, C.N. Esomchi, M.A. Epete, C.A. Okoronkwo, J.N. Obimma, C.I. Onwe, E.N. Joe-Ogba
154-162

DOWNLOAD PDF (HTTPS://W

Reconstruction of postmortem interval from evaluation of decomposition rates and patterns based on modes of death using porcine models (https://www.ajol.info/index.php/jeca/article/view/292411)
M.E. Nandi, A.B. Ayankunle, G.E. Emmanson, N.O. Okorn, A.U. Ekanem, C.C. Mbadugha
163-178

DOWNLOAD PDF (HTTPS://W

Toxicity effects of energy drinks in combination with alcohol on the cerebellar cortex of adult Wistar rats (https://www.ajol.info/index.php/jeca/article/view/292418)
P.U. Lukpata, O. Ini-Ibehe, B.B. Runyi, W.A. Alfred, E.A. Kingsley, A.A. Oremosu
179-185

DOWNLOAD PDF (HTTPS://W

Tubo-Ovarian (Adnexal) Ectopic Gravidae: Comparative Analysis of 2 Cases (https://www.ajol.info/index.php/jeca/article/view/292423)
A.M. Afodun, A. Jabo, M. Mukangendo, V. Maniraho, M.A. Masud, F.X. Akimuhana, F.T. Niyonkuru, P. Iradukunda
186-190

DOWNLOAD PDF (HTTPS://W

VIEW ALL ISSUES › (HTTPS://WWW.AJOL.INFO/INDEX.PHP/JECA/ISSUE/ARCHIVE)

Journal Identifiers

eISSN: 1596-2393

About AJOL

AJOL Team (https://www.ajol.info/index.php/ajol/team)
AJOL Board (https://www.ajol.info/index.php/ajol/board)
Donors (https://www.ajol.info/index.php/ajol/donors)
Partners (https://www.ajol.info/index.php/ajol/AJOL-partners)
Sponsors (https://www.ajol.info/index.php/ajol/npo)
Contact (https://www.ajol.info/index.php/ajol/contact-AJOL)
Usage Statistics (https://www.ajol.info/index.php/ajol/statistics)
Journal Quality (https://www.ajol.info/index.php/ajol/JPPS)
About AJOL (https://www.ajol.info/index.php/ajol/about-AJOL-African-Journals-Online)

Policies

Whistle blowing (https://www.ajol.info/index.php/ajol/whistle-blowing)
Terms and conditions (https://www.ajol.info/index.php/ajol/terms-and-conditions)
Non-profit Organisation (https://www.ajol.info/index.php/ajol/npo)

AJOL is a non-profit, relying on your support.

DONATE

AJOL's largest donor partners:

Norad (https://www.norad.no/en) wellcome (https://wellcome.org/) SCOSS (https://www.scoss.org)

SIGN UP FOR TITLES OF INTEREST (HTTPS://WWW.AJOL.INFO/INDEX.PHP/AJOL/AJOLNOTIFICATIONS/REGISTERAJOLNOTIFICATIONS?NEWJOURNALSONLY=1)

Follow AJOL

(HTTPS://TWITTER.COM/AFRICANDOCUMENTS) (HTTPS://WWW.FACEBOOK.COM/AFRICANDOCUMENTS) (HTTPS://WWW.YOUTUBE.COM/@AFRICANDOCUMENTS) (HTTPS://WWW.INSTAGRAM.COM/AFRICANDOCUMENTS) (HTTPS://WWW.LINKEDIN.COM/COMPANY/AFRICAN-DOCUMENTS) (HTTPS://WWW.TIKTOK.COM/@AFRICANDOCUMENTS) (HTTPS://WWW.PINTEREST.COM/AFRICANDOCUMENTS) (HTTPS://WWW.TUMBLR.COM/AFRICANDOCUMENTS) (HTTPS://WWW.REDDIT.COM/R/AFRICANDOCUMENTS) (HTTPS://WWW.SNAPCHAT.COM/AFRICANDOCUMENTS) (HTTPS://WWW.WHATSAPP.COM/AFRICANDOCUMENTS) (HTTPS://WWW.TELEGRAM.ORG/AFRICANDOCUMENTS) (HTTPS://WWW.DISCORD.COM/AFRICANDOCUMENTS) (HTTPS://WWW.TWITCH.TV/AFRICANDOCUMENTS) (HTTPS://WWW.VIMEO.COM/AFRICANDOCUMENTS) (HTTPS://WWW.FLICKR.COM/AFRICANDOCUMENTS) (HTTPS://WWW.MEDIUM.COM/AFRICANDOCUMENTS) (HTTPS://WWW.QUORA.COM/AFRICANDOCUMENTS) (HTTPS://WWW.STACKOVERFLOW.COM/AFRICANDOCUMENTS) (HTTPS://WWW.GITHUB.COM/AFRICANDOCUMENTS) (HTTPS://WWW.BEHANCE.NET/AFRICANDOCUMENTS) (HTTPS://WWW.DRIBBBLE.COM/AFRICANDOCUMENTS) (HTTPS://WWW.SOUNDCLOUD.COM/AFRICANDOCUMENTS) (HTTPS://WWW.SPOTIFY.COM/AFRICANDOCUMENTS) (HTTPS://WWW.APPLE.COM/AFRICANDOCUMENTS) (HTTPS://WWW.AMAZON.COM/AFRICANDOCUMENTS) (HTTPS://WWW.EBAY.COM/AFRICANDOCUMENTS) (HTTPS://WWW.ETSY.COM/AFRICANDOCUMENTS) (HTTPS://WWW.WALMART.COM/AFRICANDOCUMENTS) (HTTPS://WWW.TARGET.COM/AFRICANDOCUMENTS) (HTTPS://WWW.BESTBUY.COM/AFRICANDOCUMENTS) (HTTPS://WWW.HOMEDEPOT.COM/AFRICANDOCUMENTS) (HTTPS://WWW.LOWES.COM/AFRICANDOCUMENTS) (HTTPS://WWW.IKEA.COM/AFRICANDOCUMENTS) (HTTPS://WWW.WAYFAIR.COM/AFRICANDOCUMENTS) (HTTPS://WWW.OVERSTOCK.COM/AFRICANDOCUMENTS) (HTTPS://WWW.ZAPPOS.COM/AFRICANDOCUMENTS) (HTTPS://WWW.NORDSTROM.COM/AFRICANDOCUMENTS) (HTTPS://WWW.MACYS.COM/AFRICANDOCUMENTS) (HTTPS://WWW.KOHLS.COM/AFRICANDOCUMENTS) (HTTPS://WWW.JCPENNEY.COM/AFRICANDOCUMENTS) (HTTPS://WWW.SEARS.COM/AFRICANDOCUMENTS) (HTTPS://WWW.OLDNAVY.COM/AFRICANDOCUMENTS) (HTTPS://WWW.GAP.COM/AFRICANDOCUMENTS) (HTTPS://WWW.BANANAREPUBLIC.COM/AFRICANDOCUMENTS) (HTTPS://WWW.ATHLETA.COM/AFRICANDOCUMENTS) (HTTPS://WWW.ANNTAYLOR.COM/AFRICANDOCUMENTS) (HTTPS://WWW.LOFT.COM/AFRICANDOCUMENTS) (HTTPS://WWW.EXPRESS.COM/AFRICANDOCUMENTS) (HTTPS://WWW.FOREVER21.COM/AFRICANDOCUMENTS) (HTTPS://WWW.H&M.COM/AFRICANDOCUMENTS) (HTTPS://WWW.ZARA.COM/AFRICANDOCUMENTS) (HTTPS://WWW.UNIQLO.COM/AFRICANDOCUMENTS) (HTTPS://WWW.ASOS.COM/AFRICANDOCUMENTS) (HTTPS://WWW.TOPSHOP.COM/AFRICANDOCUMENTS) (HTTPS://WWW.MISSGUIDED.COM/AFRICANDOCUMENTS) (HTTPS://WWW.BOOHOO.COM/AFRICANDOCUMENTS) (HTTPS://WWW.PRETTYLITTLETHING.COM/AFRICANDOCUMENTS) (HTTPS://WWW.NASTYGAL.COM/AFRICANDOCUMENTS) (HTTPS://WWW.REVOLVE.COM/AFRICANDOCUMENTS) (HTTPS://WWW.FREEPEOPLE.COM/AFRICANDOCUMENTS) (HTTPS://WWW.ANTHROPOLOGIE.COM/AFRICANDOCUMENTS) (HTTPS://WWW.URBANOUTFITTERS.COM/AFRICANDOCUMENTS) (HTTPS://WWW.ABERCROMBIE.COM/AFRICANDOCUMENTS) (HTTPS://WWW.HOLLISTER.COM/AFRICANDOCUMENTS) (HTTPS://WWW.AMERICANEAGLE.COM/AFRICANDOCUMENTS) (HTTPS://WWW.AERIE.COM/AFRICANDOCUMENTS) (HTTPS://WWW.VICTORIASSECRET.COM/AFRICANDOCUMENTS) (HTTPS://WWW.PINK.COM/AFRICANDOCUMENTS) (HTTPS://WWW.BATH&BODYWORKS.COM/AFRICANDOCUMENTS) (HTTPS://WWW.SEPHORA.COM/AFRICANDOCUMENTS) (HTTPS://WWW.ULTABEAUTY.COM/AFRICANDOCUMENTS) (HTTPS://WWW.MAC-COSMETICS.COM/AFRICANDOCUMENTS) (HTTPS://WWW.BOBBIBROWN.COM/AFRICANDOCUMENTS) (HTTPS://WWW.CLINIQUE.COM/AFRICANDOCUMENTS) (HTTPS://WWW.ESTEELAUDER.COM/AFRICANDOCUMENTS) (HTTPS://WWW.LANCOME.COM/AFRICANDOCUMENTS) (HTTPS://WWW.YSL.COM/AFRICANDOCUMENTS) (HTTPS://WWW.DIOR.COM/AFRICANDOCUMENTS) (HTTPS://WWW.CHANEL.COM/AFRICANDOCUMENTS) (HTTPS://WWW.GUERLAIN.COM/AFRICANDOCUMENTS) (HTTPS://WWW.KIEHLS.COM/AFRICANDOCUMENTS) (HTTPS://WWW.ORIGINS.COM/AFRICANDOCUMENTS) (HTTPS://WWW.THEBODYSHOP.COM/AFRICANDOCUMENTS) (HTTPS://WWW.LUSHUSA.COM/AFRICANDOCUMENTS) (HTTPS://WWW.NATURA.COM/AFRICANDOCUMENTS) (HTTPS://WWW.AVON.COM/AFRICANDOCUMENTS) (HTTPS://WWW.MARYKAY.COM/AFRICANDOCUMENTS) (HTTPS://WWW.AMWAY.COM/AFRICANDOCUMENTS) (HTTPS://WWW.HERBALIFE.COM/AFRICANDOCUMENTS) (HTTPS://WWW.USANA.COM/AFRICANDOCUMENTS) (HTTPS://WWW.NUSKIN.COM/AFRICANDOCUMENTS) (HTTPS://WWW.ISAGENIX.COM/AFRICANDOCUMENTS) (HTTPS://WWW.JUICEPLUS.COM/AFRICANDOCUMENTS) (HTTPS://WWW.YOUNGLIVING.COM/AFRICANDOCUMENTS) (HTTPS://WWW.DOTERRA.COM/AFRICANDOCUMENTS) (HTTPS://WWW.ARBONNE.COM/AFRICANDOCUMENTS) (HTTPS://WWW.MONAVIE.COM/AFRICANDOCUMENTS) (HTTPS://WWW.FOREVERLIVING.COM/AFRICANDOCUMENTS) (HTTPS://WWW.NUTRILITE.COM/AFRICANDOCUMENTS) (HTTPS://WWW.AMWAY.COM/AFRICANDOCUMENTS) (HTTPS://WWW.HERBALIFE.COM/AFRICANDOCUMENTS) (HTTPS://WWW.USANA.COM/AFRICANDOCUMENTS) (HTTPS://WWW.NUSKIN.COM/AFRICANDOCUMENTS) (HTTPS://WWW.ISAGENIX.COM/AFRICANDOCUMENTS) (HTTPS://WWW.JUICEPLUS.COM/AFRICANDOCUMENTS) (HTTPS://WWW.YOUNGLIVING.COM/AFRICANDOCUMENTS) (HTTPS://WWW.DOTERRA.COM/AFRICANDOCUMENTS) (HTTPS://WWW.ARBONNE.COM/AFRICANDOCUMENTS) (HTTPS://WWW.MONAVIE.COM/AFRICANDOCUMENTS) (HTTPS://WWW.FOREVERLIVING.COM/AFRICANDOCUMENTS) (HTTPS://WWW.NUTRILITE.COM/AFRICANDOCUMENTS) (HTTPS://WWW.AFRICANDOCUMENTS-ONLINE)

Access this Article online
Quick Response Code:



Website: jecajournal.com
Doi: doi.org/10.4314/jeca.v22i1.13

Original Article

Impact of Potassium Sorbate on Cognitive Performance and Hippocampal Morphology in Wistar Rats

Adana M.Y., Lawal K., Onigbolabi O.G. and Akintola S.

ABSTRACT

Background and aim: Potassium sorbate is commonly used as an antimicrobial preservative in oral and topical pharmaceutical formulations and is generally regarded as a relatively nontoxic substance by the US FDA. However, some adverse reactions to potassium sorbate have been reported. This research aimed to investigate the effects of potassium sorbate on the structure and function of the hippocampus in adult male Wistar rats.
Materials and Methods: Twenty-five male Wistar rats, aged 8-10 weeks and weighing 180-220g, were randomly divided into five groups of five rats each. The groups included Group NS, which received normal saline; PS25, which received potassium sorbate at 25 mg/kg body weight; PS50, which received potassium sorbate at 50 mg/kg body weight; PS100, which received potassium sorbate at 100 mg/kg body weight; and PS200, which received potassium sorbate at 200 mg/kg body weight. All treatments were administered orally every day for 56 days. Histological, biochemical, and immunohistochemical methods were used to assess the structural and functional characteristics of the groups. The immunohistochemical localisation of GFAP (Glial Fibrillary Acidic Protein), NeuN (Neuronal Nuclear Protein), and BCL-2 (B-cell Lymphoma/Leukemia 2 Protein) was performed. Additionally, the effects on the animals' behaviour were evaluated using behavioural tests.
Results: The structure and expression of proteins in the hippocampus were dose-dependently distorted; however, no notable changes in learning and memory functions were observed in the animals.
Conclusion: Potassium sorbate exhibits deleterious effects on the hippocampus of rats in a dose-dependent manner.

Keywords:
Potassium sorbate; hippocampus; dentate gyrus; learning; memory function

INTRODUCTION

Technological advancements have increased the reliance of our modern food sector on processing and chemicals. The food business has been developing new chemicals constantly for years to modify, preserve, and transform our food. Chemicals enable scientists to imitate natural flavours, colour foods to make them appear more "natural" or "fresh," preserve food for ever-increasing amounts of time, and produce modified versions of bread, crackers, fruits, vegetables, meats, dairy products, and many other everyday foods (Sparks *et al.,* 2017). There are currently "foods" that are chemically produced. Most of the components in candies, sugar substitutes, and coffee creamers are synthetic. A body's particular metabolic equilibrium may be significantly impacted by such alteration in food intake. These alterations are done using various food additives.

Additives are substances used in the food industry for many purposes, such as to preserve food to enhance its taste or appearance (Sahu, 2016). The Food and Drug Administration (FDA) has updated an online list of these food additives, which nowadays include more than 3000 substances (Pressman *et al.,* 2017). Prior to their use in foods, they must pass a premarket safety evaluation following a specific food additive regulation from particular government agencies, such as the FDA in the United States or the European Food Safety Authority (EFSA) in Europe (Roberts, 2016). A specific group of food additives named "Generally Recognised As Safe" (GRAS) includes about 1000 substances that are considered safe by experts and are exempted from the usual tolerance requirements (Burdock and Carabin, 2004). The widespread use of additives has caused concern among consumers about the possibility of adverse reactions. Some years back, the American Academy of Pediatrics (AAP) raised concerns regarding GRAS's safety in children (Trasande *et al.,* 2018).

Submitted: 12th February, 2025
Revised: 12th March, 2025
Accepted: 28th March, 2025
Published: 31st March, 2025

Department of Anatomy, Faculty of Basic Medical Sciences, College of Health Sciences, University of Ilorin

Address for Correspondence:
Adana M.Y.
Department of Anatomy, Faculty of Basic Medical Sciences, College of Health Sciences, University of Ilorin.
adana.my@unilorin.edu.ng

This is an open access journal, and articles are distributed under the terms of the Creative Commons Attribution-Non Commercial-Share Alike 4.0 License, which allows others to remix, tweak, and build upon the work non-commercially, as long as appropriate credit is given and the new creations are licensed under the identical terms.

For reprints contact: jecajournal@gmail.com

How to cite this article: Adana M.Y., Lawal K., Onigbolabi O.G. and Akintola S. Impact of Potassium Sorbate on Cognitive Performance and Hippocampal Morphology in Wistar Rats. *J Exp Clin Anat* 2025; 22(1):92-104.
https://dx.doi.org/10.4314/jeca.v22i1.13

Potassium sorbate is a naturally occurring unsaturated fatty acid that is completely safe regarding health and has the lowest allergenic potential of all food preservatives (EFSA Panel on Food Additives and Nutrient Sources added to Food (ANS), 2015). In recent times, most potassium sorbate is made synthetically (Sharma and Rajput, 2023). There are more and more concerns regarding the safe use of sorbate (Anand and Sati, 2013).

Quantitative determination procedures must be established to assess consumer intake levels of specific preservatives like PS in the acidic or anionic form in food (Nagasinduja and Shahitha, 2019). While some studies reported that potassium sorbate could contribute to the activation of inflammatory pathways (Raposa *et al*., 2016, Xiao et al., 2024), other studies indicate that sorbate has anti-inflammatory properties (Pahan 2011). Prior studies have suggested the negative effects of potassium sorbate on the brain. However, little is known about the mechanisms by which potassium sorbate intake causes brain damage. The continuous use of potassium sorbate in food and drinks in developing countries necessitates a detailed investigation of its effect on the brain (Raposa *et al*., 2016, Piper, 2018). Therefore, this study investigated the effect of potassium sorbate administration on the hippocampus. This research explored the impact of potassium sorbate on the structure and function of the hippocampus by investigating the Potassium sorbate-induced biochemical, histoarchitectural and neuro-behavioural changes in the hippocampus of adult male Wistar rats.

MATERIAL AND METHODS

Experimental animals

Twenty-five male Wistar rats aged 8-10 weeks, with body weights 180-220g, were housed in standard cages under natural light conditions. They were fed with standard animal pellets and water ad libitum. The animals were allowed to acclimatise to their new environment for two (2) weeks in the Animal House of the Faculty of Basic Medical Sciences, University of Ilorin. Potassium sorbate with CAS Number (CAS No. 24634-61-5) was purchased from Sigma-Aldrich. The study was approved by the University of Ilorin Ethical Review Committee (UERC) with approval number UERC/ASN/2022/2358, and the research was carried out in compliance with the Institutional Animal Care and Use Committee (IACUC).

Experimental design

The rats were randomly divided into five groups of five rats each. These include Group NS, which received normal saline; PS25, which received 25 mg/kg body weight of Potassium sorbate; PS50, which received 50 mg/kg body weight of Potassium sorbate; PS100, which received 100 mg/kg body weight of Potassium sorbate; and PS200, which received 200 mg/kg body weight of Potassium sorbate. All treatments were orally administered. Potassium sorbate was combined with normal saline to form solutions for easy dosing and administration. The animals were weighed every three days for dosage adjustments, and the experiment lasted for 56 days.

Experimental termination and sample collection

The day after conclusion of the administrations, rats were first anaesthetised with ketamine (20 mg/kg body weight, intra-peritoneally) and then subjected to transcardial perfusion by infusion of 50 ml of 0.1M saline (pH 7.4) and 500 ml of 4% paraformaldehyde (PFA). For rats that were processed for enzymatic studies, sacrifices by cervical dislocation were carried out. The brain tissues were then excised, weighed and rinsed in 0.25 M sucrose 3 times for 5 minutes each and then post-fixed in 4% PFA for 24 hours, after which they were stored in 30% sucrose at 4°C until further processing. The relative brain weights of the animals were estimated from the brain weight of the animals and the final body weight using the formula:

Brain Weight ÷ final Body weight × 100

Histological Assessment

For histopathological examination, fixed brain tissues were dissected to reveal the hippocampus, processed through graded ethanol (increasing concentrations) and embedded in paraffin. Microtome sections at 5µm were obtained using a microtome (micron HM 315 microtome) and stained with haematoxylin and eosin. The slices were examined, and images were captured using an Olympus light microscope (Olympus BX51) and a camera (Olympus E330, Olympus Optical Co. Ltd.).

Expression of GFAP, NeuN, and Bcl-2

Immunohistochemical methods were used to demonstrate the presence and location of some specific proteins in the hippocampal sections. The immunohistochemical localisations of GFAP (Glial fibrillary acidic protein), NeuN (neuronal nuclear protein) and BCL-2 (B-cell leukaemia/lymphoma 2 Protein) were carried out. The primary antibodies used in this study were anti-GFAP, anti-NeuN and anti-Bcl-2, respectively, for immunoperoxidase. This was carried out following the method described by Goldstein and Watkins in the year 2008 (Goldstein and Watkins, 2008). The procedure is described below. Deparaffinisation was carried out.followed by antigen retrieval. This study used an enzymatic antigen retrieval method with trypsin (Abcam: catalogue ID ab970).

Endogenous peroxidase blocking was done using hydrogen peroxide (0.5-3%), while 5% bovine serum albumin (BSA) was used to reduce non-specific protein reactions. Slides were drained for a few seconds and wiped around the sections with tissue paper. Diluted primary antibody was added to each slide (500 ml) and incubated overnight at 4°C. Primary antibodies dilution was done in blocking buffer (10% calf serum with 1% BSA and 0.1% Triton X-100 in 0.1 M PBS): Anti-GFAP – (Cell Signaling, dilution 1:1000). Subsequently, slides were rinsed two times for 5 minutes in 0.1 M PBS (0.025% Triton) with gentle agitation. Slides were then treated with horseradish peroxidase (HRP) secondary antibody and incubated for 2 hours at room temperature. Slides were then rinsed for 3 times for 5 minutes in PBS. Colour intensification was done using chromogen 3.3'-Diaminobenzidine (DAB, 1:1000 dilution) for 1-3 minutes at room

temperature. Slides were then rinsed in running tap water for 5 minutes. Counterstaining was done in haematoxylin and 1% acid alcohol to reduce the counterstain; sections were dehydrated and cleared in ethanol and xylene, respectively. Mounting was done. The quantification of the levels of NeuN and Bcl-2 were done using the NeuN and Bcl-2 kits (Santa Cruz, Germany) according to the manufacturer instructions and modified method of Edelstein *et al*. (2014). Stained tissue sections were viewed under a light binocular microscope, and images were captured with an amscope camera (MD 500). Morphometric analysis of the tissue was done using Image J software and plugins to analyse the cell count of neurons on the photomicrographs.

Behavioural tests

Y-maze Test

The test was conducted as earlier described (Wright *et al.,* 2006) and slightly modified. The symmetrical Y-maze, developed by Dellu and his colleagues (Dellu *et al.,* 1992), was briefly used to assess hippocampal-dependent spatial recognition memory. The Y-maze consisted of three identical wooden arms (50 cm L, 16 cm W, 32 cm H) with multiple extra-maze cues (Conrad *et al.*, 1996) located around the perimeter of the maze. The maze was rotated between training and testing. An overhead video camera recorded the movement of the rat for later quantification, and the investigator stood in a white coat in the same position during training and testing. Rats were tested on the Y-maze with a 1-hour delay between training and testing. Y-maze navigation relies upon a rat's innate tendency to explore novel environments (Ennaceur and Delacour, 1988). In the present experiments, rats that recognised and chose the Novel arm more than the other arms were defined as having intact spatial working memory. In contrast, those that entered the Novel and other arms similarly were considered to have impaired spatial working memory.

During training, one arm designated the Novel (arm C) of the Y-maze was blocked with a shutter, allowing the rats to explore the Start (arm A) and Other arm (arm B) for 15 minutes. The shutter that blocked the novel arm was the height of the arms, preventing rats from seeing the Novel arm or inspecting the spatial cues visible only from the novel arm. Following training, rats were returned to their cages for a period of 1 hour. After the interruption, the shutter was removed, and rats were placed in the Start arm and allowed to explore the Y-maze for 5 minutes. Each rat was given one trial during training and testing. An member of the research team oblivious of the treatment groups determined the number of entries and time spent by each mouse in the Novel, Start, and other arms for five minutes. An entry was counted when the forearms of the mouse entered the arm. The number and the sequence of arms entered were also recorded. The parameters were activity, defined as the number of arms entered, and percent alternation, calculated as:

% Alternation = [(Number of alternations)/(Total number of arm entries – 2)] × 100 (Sarnyai *et al.,* 2000).

Morris Water Maze Test for Spatial Learning in the rats

The Morris water maze is widely used to study spatial memory and learning. The water maze consists of a round pool about 6 feet in diameter and about 3 feet deep. The water maze was filled with water, and an escape platform was placed in the centre of the pool. During the training, the escape platform was exposed one inch above the water (Nunez, 2008). This taught the rat that there is a platform which is the way to get out of the water. After the training, the animal was tested; the platform will be just below the surface of the water and will not be visible with powdered, non-fat milk. The animal was then placed in a pool of water that was colored opaque with powdered non-fat milk, where they may swim to a hidden escape platform (Nunez, 2008). The observer stepped back from the pool and observed from a designated spot while the animal performed the maze task. Due to the opaque water, the animal was unable to see the platform and could not rely on scent to find an escape route; instead, they relied on the maze cues. As the animals become more familiar with the task, they were able to find the platform more quickly. The animal was monitored until it reached the platform, and the time taken was recorded. The procedure is videotaped to monitor the path and other variables (Nunez, 2008).

Statistical analysis

Statistical analysis was done using GraphPad, Prism, and SPSS version 18. Values were expressed as mean ± SEM, n=5 (number of animals in each group). All statistical comparisons were performed using a one-way analysis of variance (ANOVA). Tukey's *post hoc* test was carried out. The significance level was set at $P < 0.05$.

RESULTS

Body Weight, Brain Weight and Brain Somatic Index

As seen in Table 1, there was a significant increase ($p<0.05$) in the body weight of Wistar rats in group PS50, PS100 and PS200, respectively, when compared with groups PS25 and NS. However,

there was no significant ($p<0.05$) difference in brain weights of the Wistar rats administered with different doses (PS25, PS50 PS100 and PS200 mg/kg) of potassium sorbate when compared with the Control (NS) administered with normal saline.

It can also be seen that the brain somatic index significantly decreased ($p<0.05$) in Wistar rats of group PS50, PS100 and group PS200, respectively, when compared with group PS25 and NS. There was no significant difference between the PS25 group and the NS group (see table 1).

Oxidative Stress Biomarkers

Malondialdehyde (MDA) levels increased in Wistar rats of group PS50 PS100 and group PS200 exposed to Potassium sorbate compared with the NS and PS25. There was no significant increase ($p<0.05$) in superoxide dismutase (SOD) levels in Wistar rats of groups of PS25, PS50, PS100, and PS 200 when compared

with the Control exposed to potassium sorbate. There was no significant increase ($p<0.05$) in Catalase (CAT) levels in Wistar rats of groups PS25, PS50, PS100, and PS 200 when compared with the Control (see table 2).

Table 1: Body weight, Brain weight and Brain Somatic Index across experimental groups

Group	Initial weight (g)	Final Body weight (g)	Weight gained (g)	Brain weight (g)	Organ Somatic Index
NS	90.80±1.32	142.80±3.40	52.00±2.08	1.76±0.03	1.24±0.05
PS25	97.20±0.58	177.40±13.76	80.20±13.18	1.77±0.06	1.01±0.04
PS50	107.80±3.32	218.40±15.91*	110.60±12.59	1.75±0.03	0.82±0.07*
PS100	112.20±3.87	226.00±21.65*	113.80±17.78	1.74±0.05	0.79±0.05*
PS200	115.00±4.52	226.80±23.51*	111.80±18.99	1.71±0.07	0.78±0.08*

*: Significantly different from the Control.

Table 2: Oxidative biomarkers across experimental groups

Parameters	MDA (mg/L)	SOD protein (U/mg)	CAT protein (U/ mg)
NS	1.12±0.10	249.33±80.96	578.24±101.44
PS25	1.35±0.09	444.33±137.26	945.38±157.99
PS50	1.64±0.06*	302.98±104.10	709.17±99.08
PS100	1.60±0.05*	373.36±54.00	558.02±26.90
PS200	1.56±0.06*	343.20±64.52	813.20±120.72

*: Significantly different from the Control.

Behavioral study

Morris water maze test

Escape latency time (the time it takes for the animal to find the escape platform was compared across the groups. There were significantly higher latency times in other groups than in the control, except in the PS100 group. See Figure 1(a).

Y-maze test

The level of exploration was measured using the Y-maze test, and results were compared across all groups. There were no significant differences in the percentage of correct alternation displayed among the groups. See Figure 1(b).

Histopathological Studies

Haematoxylin and eosin (H&E) stain

The H&E stain of the CA3 region of the hippocampus of Wistar rats in NS (control group) administered normal saline showed relatively normal cytoarchitecture and characteristic appearance of the pyramidal cell with well-preserved cytoplasm, prominent nuclei and nucleoli and axon radiating from the cell body and intact vasculature. The PS25 (administered potassium sorbate 25mg/kg) showed histoarchitectural distortions: Pyknotic neuron (Pk), Vacuolations (V), and Gliosis (g). The PS50 (administered potassium sorbate 50mg/kg) showed histoarchitectural distortions: Pyknotic neuron (Pk); Vacuolation (V); Gliosis (g); Cell loss (N). The PS100 (administered potassium sorbate 100mg/kg) showed histoarchitectural distortions: Pyknotic neuron (Pk), Vacuolation (V), and cell loss (N). The PS200 (administered potassium sorbate 200mg/kg) showed histoarchitectural distortions: Vacuolation (V) and cell loss (N). See Figure 3

Immunohistochemical studies

Glial Fibrillary Acidic Protein (GFAP)

The expression of GFAP in the CA3 region of the hippocampus of adult Wistar rats in NS (control group) administered normal saline showed immuno-positive astrocytes. The PS25 (administered potassium sorbate 25mg/kg) showed a normal astrocyte density. The PS50 (administered potassium sorbate 50mg/kg) showed hypertrophied astrocytes and low astrocytic densities. The PS100 (administered potassium sorbate 100mg/kg) showed low astrocytic densities and vacuolation. The PS200 (administered potassium sorbate 200mg/kg) showed very low astrocytic densities and vacuolation. See Figure 4.

GFAP expression in the dentate gyrus region of the hippocampus of adult Wistar rats. The NS group showed GFAP-positive astrocytes. The PS25 (administered potassium sorbate 25mg/kg) showed a normal astrocyte density. The PS50 (administered potassium sorbate 50mg/kg) showed hypertrophied astrocytes and low astrocytic densities. The PS100 (administered potassium sorbate 100mg/kg) showed low astrocytic densities and vacuolation. The PS200 (administered potassium sorbate 200mg/kg) showed very low astrocytic densities and vacuolation.

Immunohistochemical demonstration of Neuronal Nuclear (NeuN)

The photomicrograph from the immunohistochemical stain of the CA3 region of the hippocampus of adult Wistar rat in Figure 5 shows the expression of NeuN in NS (control group) administered normal saline, PS25 (administered potassium sorbate 25mg/kg), PS50 (administered potassium sorbate 50mg/kg) PS100 (administered potassium sorbate 100mg/kg) showed increased NeuN immunoreactivity with normal cellular architectural layout and densities. The PS200 (administered potassium sorbate

200mg/kg) showed decreased NeuN immunoreactivity, nuclear degeneration, low densities, and vacuolation.

The dentate gyrus region of the hippocampus of adult Wistar rats has a similar expression as the CA3 region where NS (control group) administered normal saline, PS25 (administered potassium sorbate 25mg/kg), showed increased NeuN immunoreactivity with normal cellular architectural layout and densities. The expression in the PS50 (administered potassium sorbate 50mg/kg), PS100 (administered potassium sorbate 100mg/kg) and PS200 (administered potassium sorbate 200mg/kg) was very significant.

Expression of Bcl-2

The photomicrograph from the immunohistochemical stain (Bcl-2) of the CA1 region and the dentate gyrus region of the hippocampus of adult Wistar rats. In the CA1 region, NS (control) group and PS100 (administered potassium sorbate 100mg/kg showed normal Bcl-2 immunoreactivity with normal cellular architectural layout and densities. The PS25 (administered potassium sorbate 25mg/kg), PS50 (administered) and PS200 (administered potassium sorbate 200mg/kg) showed significant increases in Bcl-2 immunoreactivity, nuclear degeneration, low densities and vacuolation.

The immunohistochemical stain (Bcl-2) of the dentate gyrus region revealed normal Bcl-2 immunoreactivity with normal cellular architectural layout and densities in the NS (control group). In the PS25 (administered potassium sorbate 25mg/kg), PS50 (administered) PS100 (administered potassium sorbate 100mg/kg) and PS200 (administered potassium sorbate 200mg/kg) showed significant increase in Bcl-2 immunoreactivity; nuclear degeneration; low densities and vacuolation.

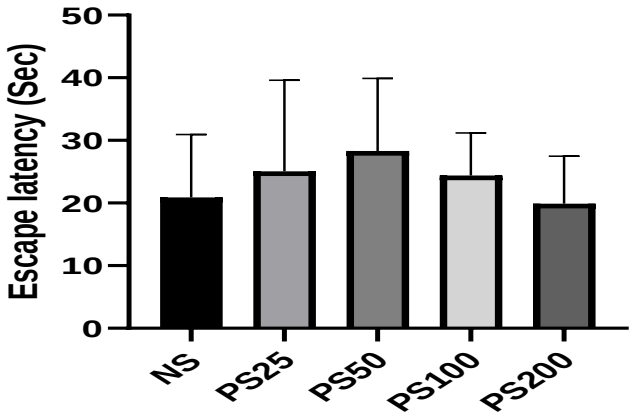

Figure 1(a): General cognitive function and spatial learning across all Potassium sorbate-treated groups. Normal saline (NS), 25 mg/kg of PS (PS25), 50 mg/kg of PS (PS50), 100 mg/kg of PS (PS100) and 200 mg/kg of PS (PS200), respectively.

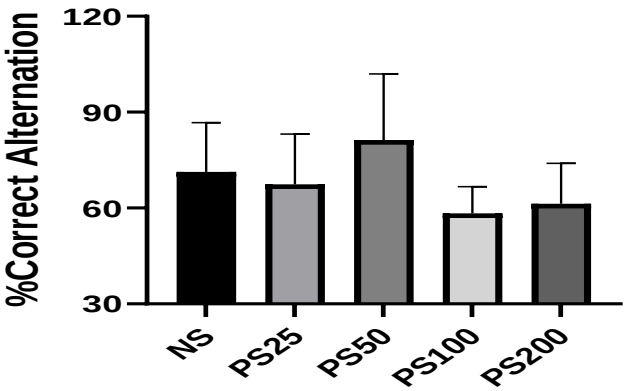

Figure 1(b): Percentage correct alternation of experimental animals in all groups. Across all groups of Potassium sorbate-treated Wistar rats. Normal saline (NS), 25 mg/kg of PS (PS25), 50 mg/kg of PS (PS50), 100 mg/kg of PS (PS100) and 200 mg/kg of PS (PS200)

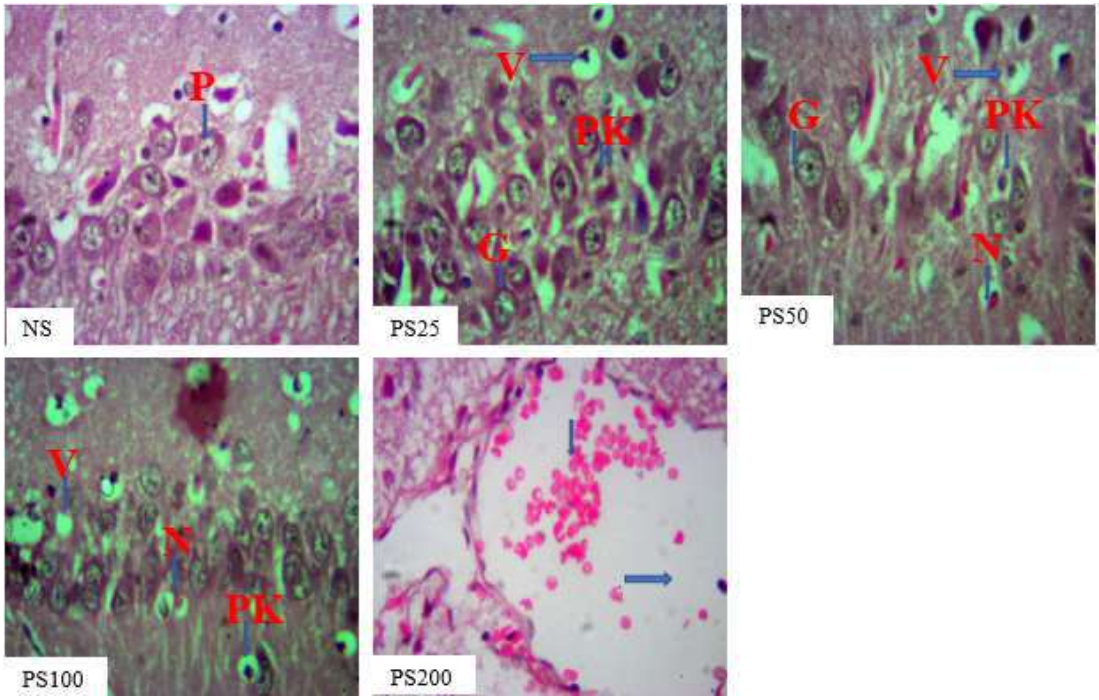

Figure 2(a): Photomicrograph of H&E-stained (x400) CA3 regions of the hippocampus of Wistar rat exposed to normal saline (NS) and different doses of potassium sorbate (PS); seen are Pyknotic neurons (Pk); Vacuolations (V); Cell loss (N). NS showed normal cytoarchitecture and characteristic appearance of the pyramidal cell with well-preserved cytoplasm, prominent nuclei and nucleoli and axon radiating from the cell body and intact vasculature. The PS25 (administered potassium sorbate 25mg/kg) showed relatively normal cytoarchitecture and characteristic appearance of the pyramidal cell; cell lose (N). The PS50 showed histoarchitectural distortions: Vacuolation (V) and cell loss (N). The PS100 showed histoarchitectural distortions: Pyknotic neuron (Pk) and vacuolation (V). The PS200 showed histoarchitectural distortions: Vacuolation (V) and cell loss (N).

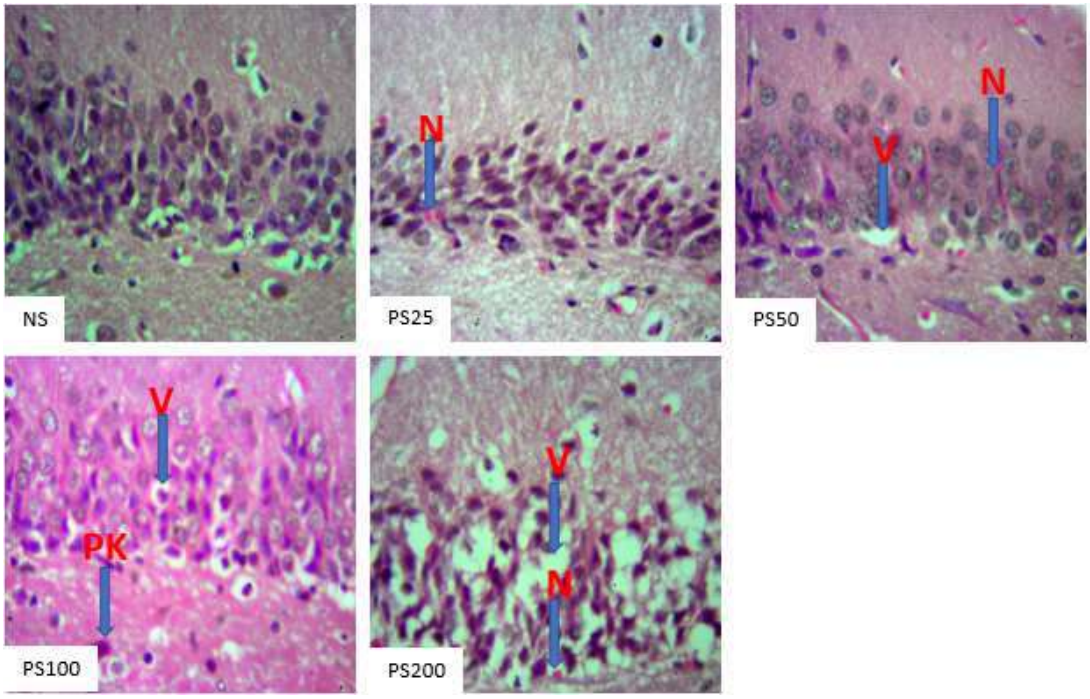

Figure 2 (b) Photomicrograph of H&E-stained (x400) Dentate gyrus of Wistar rat exposed to normal saline (NS) and different doses of potassium sorbate (PS); seen are Pyknotic neurons (Pk); Vacuolations (V); Cell loss (N). In NS, normal cytoarchitecture and intact vasculature were observed. In the PS25 (administered potassium sorbate 25mg/kg) showed relatively normal cytoarchitecture and characteristic appearance of the pyramidal cell; cell lose (N). The PS50 showed histoarchitectural distortions: Vacuolation (V) and cell loss (N). The PS100 showed histoarchitectural distortions: Pyknotic neuron (Pk) and vacuolation (V). The PS200 showed histoarchitectural distortions: Vacuolation (V) and cell loss (N).

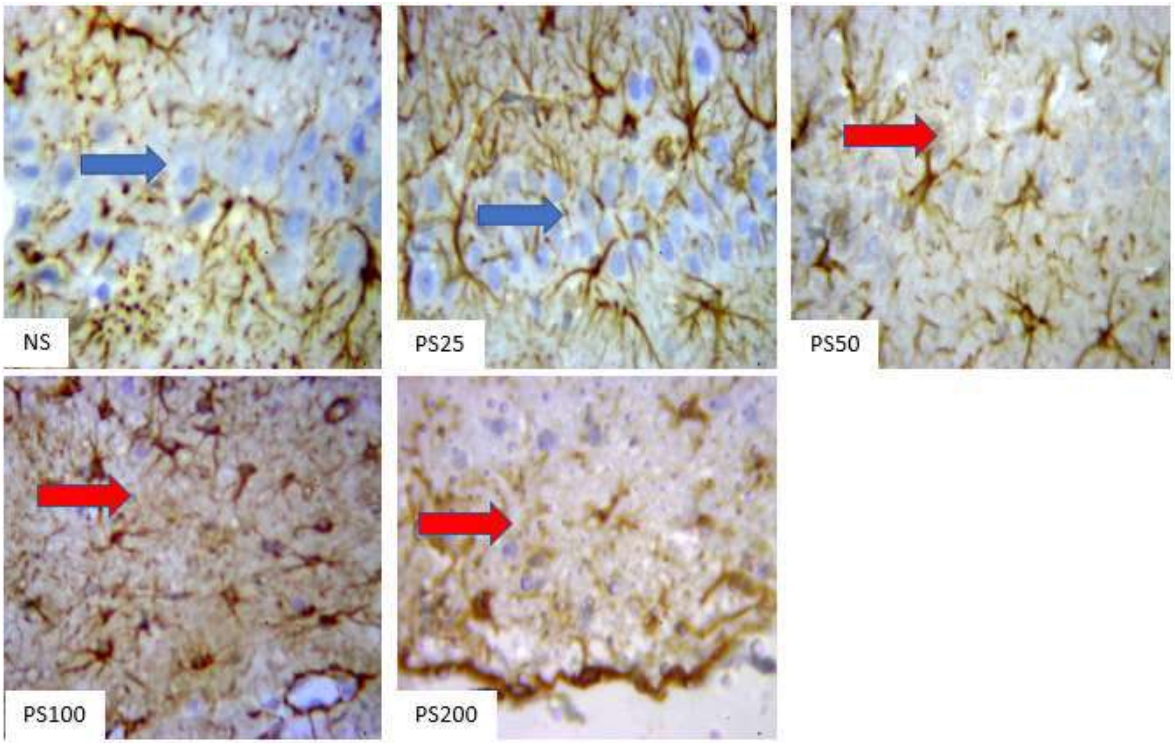

Figure 3(a): Photomicrograph of the GFAP staining of the CA3 region (x400) of the hippocampus of Wistar rat exposed to normal saline (NS) and different dose of potassium sorbate (PS); red arrows indicate decreased astroglia size and density; blue arrows indicate normal astrocytic expression with regular distribution and astrocytic densities. Staining of the dentate gyrus region of the hippocampus of Wistar rat exposed to normal saline (NS) and different doses of potassium sorbate (PS); red arrow indicates vacuolation; blue arrow indicates normal astrocytic expression with regular distribution and astrocytic densities.

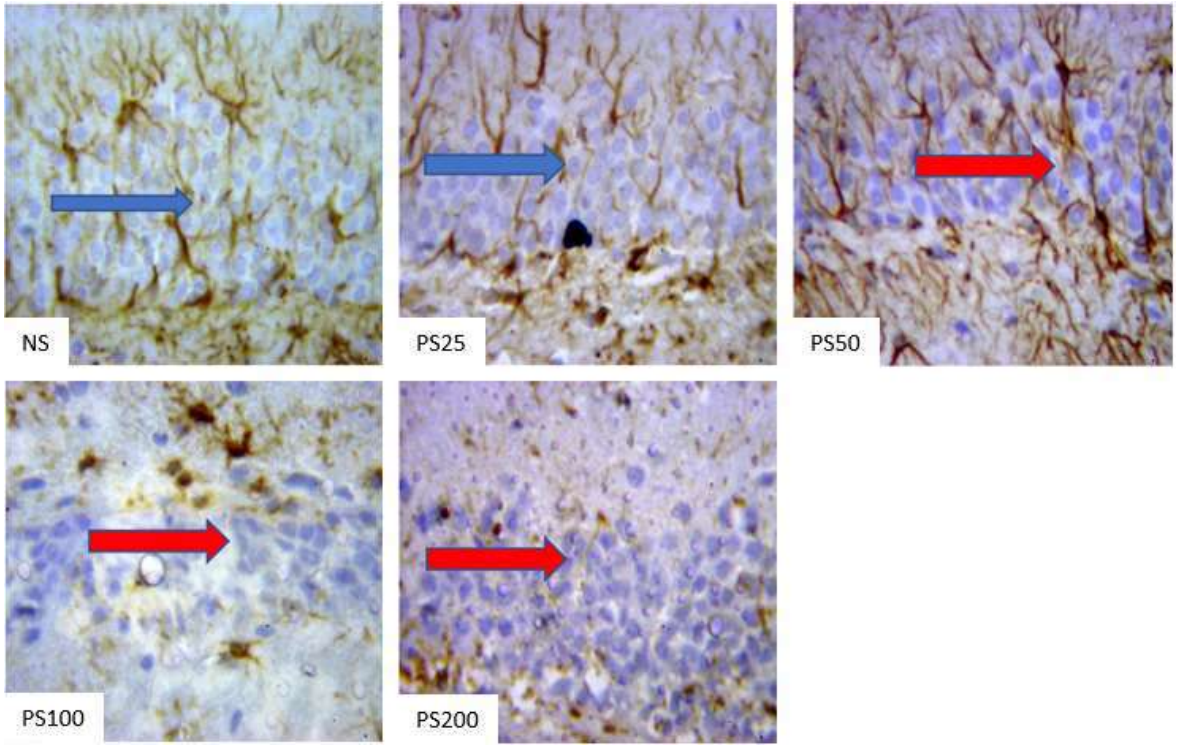

Figure 3(b): Photomicrograph of the GFAP staining of the Dentate gyrus (x400) of the hippocampus of Wistar rat exposed to normal saline (NS) and different dose of potassium sorbate (PS); red arrows indicate decreased astroglia size and density; blue arrows indicate normal astrocytic expression with regular distribution and astrocytic densities. Staining of the dentate gyrus region of the hippocampus of Wistar rat exposed to normal saline (NS) and different doses of potassium sorbate (PS); red arrow indicates vacuolation; blue arrow indicates normal astrocytic expression with regular distribution and astrocytic densities.

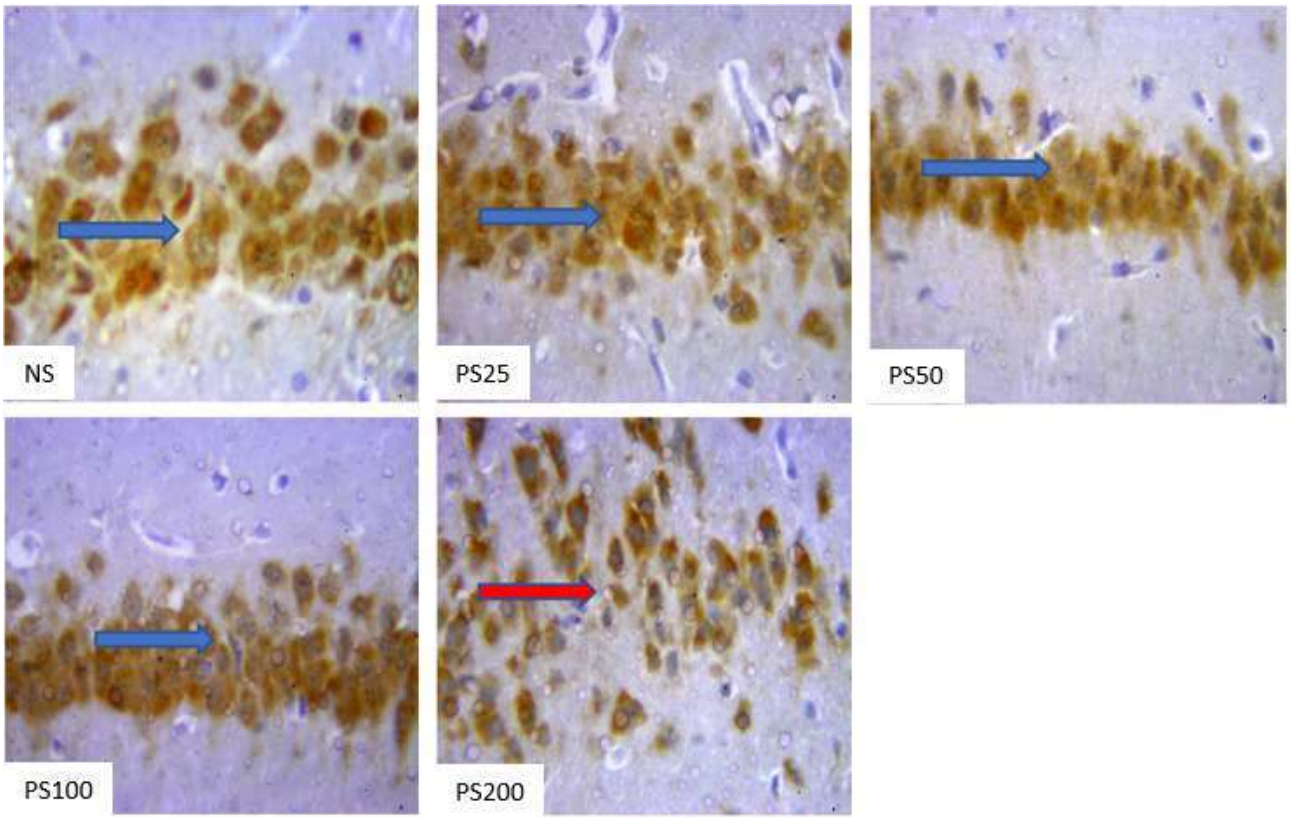

Figure 4 (a): Photomicrograph of NeuN staining of the CA3 gyrus regions (x400) of the hippocampus of Wistar rat exposed to normal saline (NS) and different dose of potassium sorbate (PS); red arrow indicates vacuolation, decrease in NeuN immunoreactivity; blue arrow indicates normal NeuN immunoreactivity expression with regular distribution and densities.

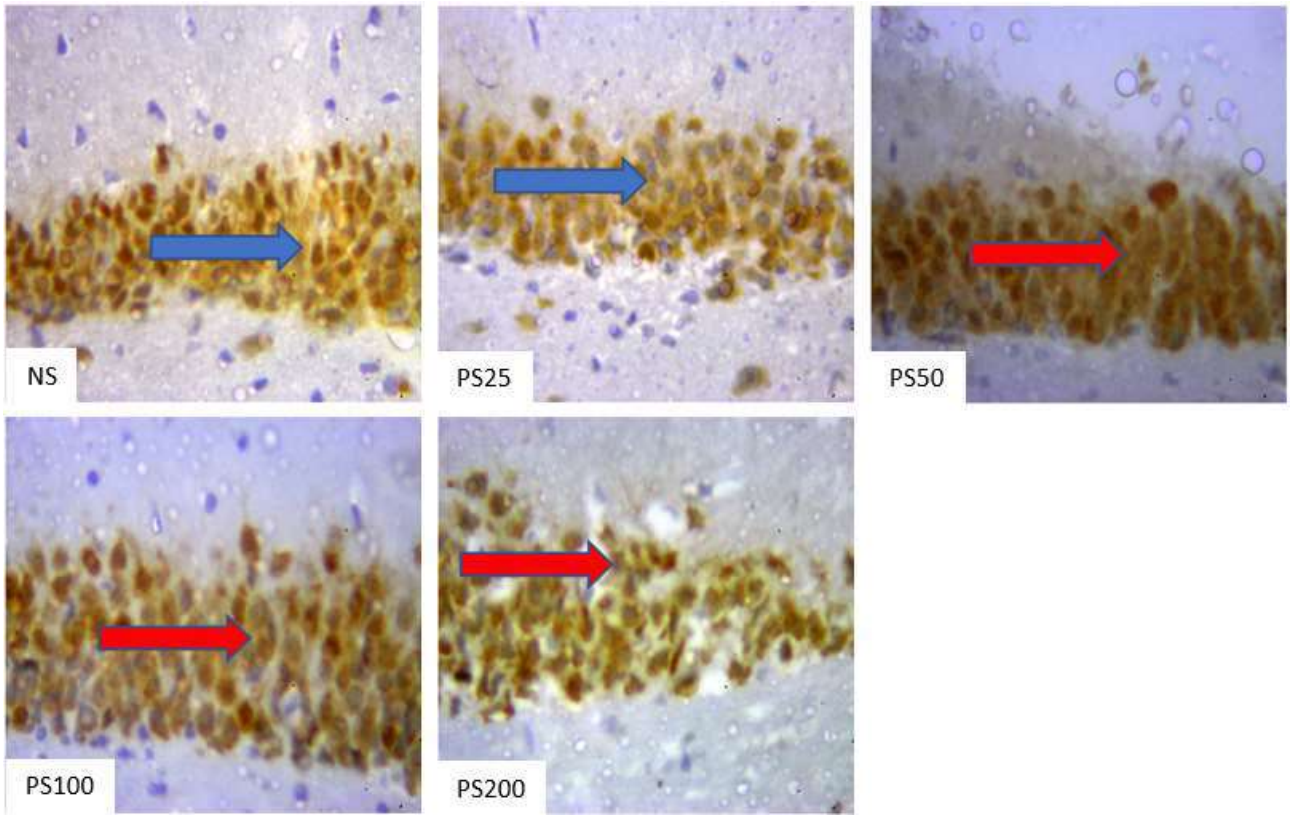

Figure 4 (b): Photomicrograph of (NeuN staining of the Dentate gyrus (x400) of the hippocampus of Wistar rat exposed to normal saline (NS) and different dose of potassium sorbate (PS); red arrow indicates vacuolation, decrease in NeuN immunoreactivity; blue arrow indicates normal NeuN immunoreactivity expression with regular distribution and densities.

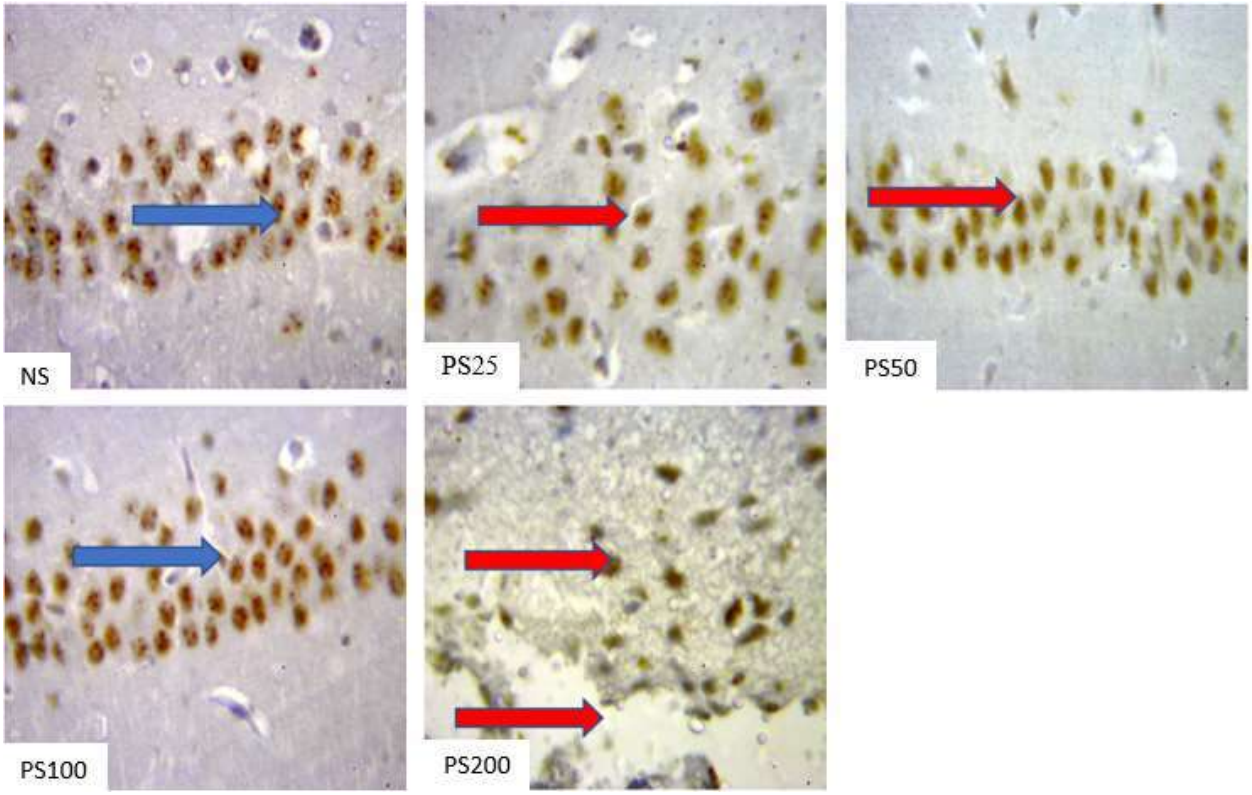

Figure 5 (a): Photomicrograph of the Bcl-2 staining of the CA1 region gyrus (x400) of the hippocampus of Wistar rat exposed to normal saline (NS) and different doses of potassium sorbate (PS); red arrow indicates increased in Bcl-2 immunoreactivity; nuclear degeneration; low densities and vacuolation.; blue arrow indicates normal Bcl-2 densities with regular distribution.

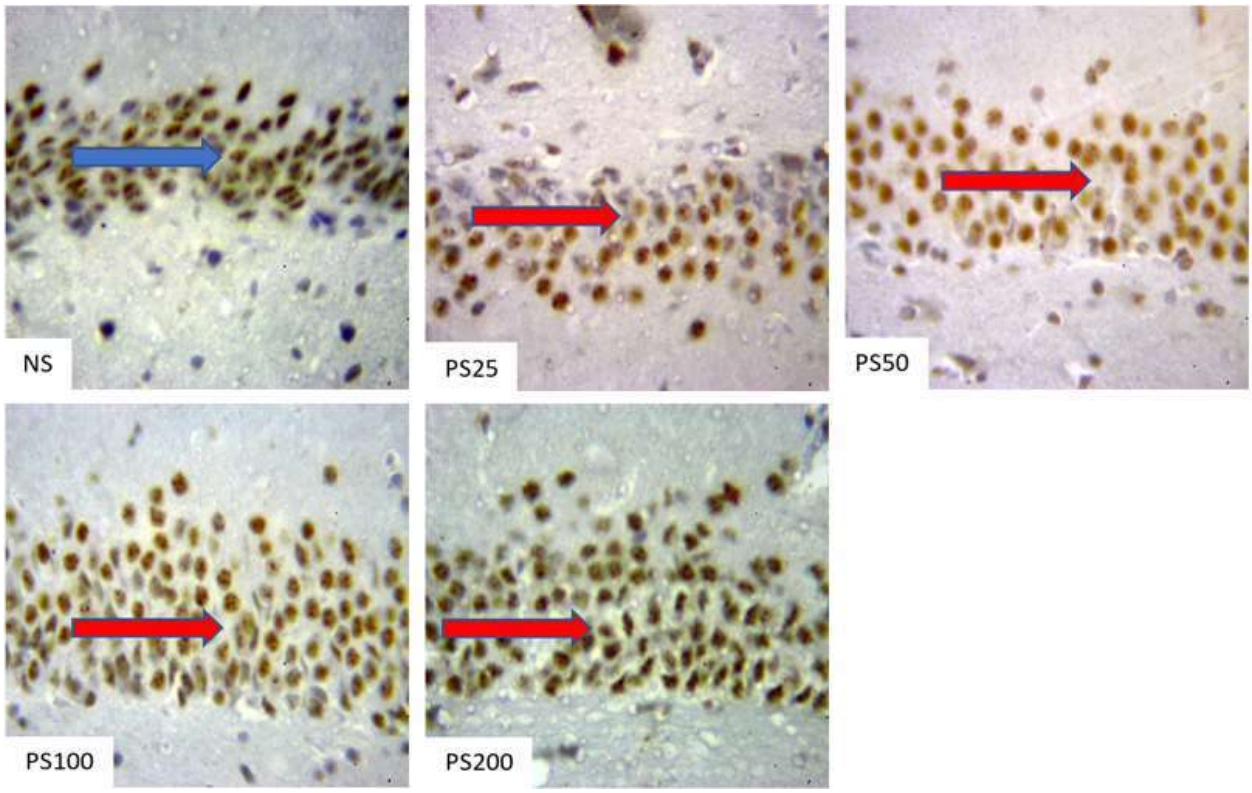

Figure 5(b): Photomicrograph of the Bcl-2 staining of the Dentate gyrus (x400) region of the hippocampus of Wistar rat exposed to normal saline (NS) and different dose of potassium sorbate (PS); red arrow indicates increased in Bcl-2 immunoreactivity and expression; nuclear degeneration; low densities and vacuolation; blue arrow indicates normal Bcl-2 expression with regular distribution and densities.

DISCUSSION

Several studies have revealed that many food additives cause neuro-toxicity in living cells either by ionic mechanism or that of oxidative stress (Jahan, 2024, Morris *et al.,* 2025). Children are observed to be more predisposed to its toxicity than adults due to the greater absorptive capacity of their gastrointestinal tracts (Morris *et al.,* 2025, Weiss, 2000). The present study was designed to assess the effects of different doses of potassium sorbate on the Hippocampus function and structure of adult male Wistar rats.

In this study, an increase in body weight was observed in the Wistar rat group of PS50, PS100 and PS200, respectively, when compared with group PS25 and NS. This suggests that exposure to a much higher concentration of potassium sorbate may cause an increase in body weight and possibly induce obesity. The increase in body weight may be a result of an increase in the consumption of food associated with the addictive-like tendencies of PS (Yoo, 2024). Another possible explanation for the rise in body weight may be increased muscle mass due to the oxidative stress (Ahn *et al.,* 2019).

The findings from this study showed a significant increase ($p<0.05$) in the brain weight of Wistar rats in groups PS25, PS50 and PS200 when compared with the NS and PS100. The elevation in brain weight in Wistar rats treated with higher doses of potassium sorbate may be due to the increase in necrosis and apoptosis, which were accompanied by the accumulation of lipids in the hippocampus.

Under physiological conditions, there is a balance between free radical production and antioxidant defence mechanisms which involves specific enzymes such as SOD, CAT, and MDA that scavenge free radicals such as vitamins and thiol groups (SH). Studies have suggested the involvement of oxidative stress in some aspects of PS toxicity. Oxidative stress occurs when the generation of free radicals exceeds the capacity of antioxidant defence mechanisms (Aruoma, 1998, Adwas *et al.,* 2019). The role of oxidative stress is key for the modulation of critical cellular functions, notably for neurons, astrocytes and microglia, such as activation of apoptosis and excitotoxicity, the two leading causes of neuronal death. Because they have a reduced capacity to detoxify ROS, neurons are particularly vulnerable to increases in ROS levels (Friedman, 2011). Oxidative stress kills neurons by stimulating the Forkhead box, class O transcription factor FOXO3, a pivotal player in cell death/life pathways (Gilley *et al.,* 2003). Neurons in the hippocampal CA1 anD dentate gyrus region are particularly susceptible to oxidative stress (Lee *et al.,* 2015, Alkadhi, 2019).

The most common group of indices used to assess oxidative stress is that of peroxidation products of lipids, usually polyunsaturated fatty acids, which are susceptible to free radical attack (Demirci-Cekic *et al.,* 2022, Dotan *et al.,* 2004). It is also known that the main toxic effects of PS are on the structure and cell membrane function (Priya *et al.,* 2021). Studies have shown that MDA, the most used end-product of lipid peroxidation, will be increased with PS treatment. This present study also indicated that lipid peroxidation, determined by measuring the MDA levels, was amplified in the brain of Wistar rats exposed to PS compared to the NS group. As a result, MDA levels increased with the increasing concentration of potassium sorbate. These suggest that the effect of PS on MDA levels is dependent on the dose of potassium sorbate or addictive exposure. The result of the study is consistent with the findings of Raposa in 2016 (Raposa et al., 2016)

Superoxide dismutase (SOD) is a metalloprotein and accomplishes its antioxidant functions by enzymatically detoxifying the superoxide radical (O2–). Different responses of SOD have been documented in experimental animals exposed to food addictive, including variations in enzymatic activity in relation to the duration of exposure and dose. Addictive blocks the sulfhydryl groups of SOD, which serve as essential cofactors for the antioxidant enzymes, thereby inactivating them (Molaei *et al.,* 2021). In the present study, SOD levels increased in all groups that were exposed to Potassium sorbate when compared with the control group. The increase in SOD level is dose-dependent, suggesting that treatment with higher doses of potassium sorbate may lead to more increase in the SOD level and the antioxidant system as a whole, hence jeopardising the health of the rat as well as increasing the production of free radicals. This was in accordance with the findings of who reported a significant increase in SOD activity in the hippocampus.

Catalase (CAT), like other antioxidant enzymes such as superoxide dismutase (SOD) and glutathione peroxidase (GPx) scavenge free radicals and lipid peroxides and detoxify them (Sivaprasad *et al.,* 2004). It is the most abundant intracellular thiol-based antioxidant, prevalent in all living aerobic cells in millimolar concentrations. It is vital in the cellular defence cascade against oxidative injury (Deisseroth and Dounce, 1970, Percy, 1984). It can act as a non-enzymatic antioxidant by direct interaction of the –SH group with ROS, or it can be involved in the enzymatic detoxification reactions for ROS as a cofactor or a coenzyme (Percy, 1984). This study showed an increase in the catalase levels in the hippocampus across all groups treated with potassium sorbate compared with the Control. The result also showed that the increase in CAT level with exposure to potassium sorbate increase antoxidant activities and hence suggests that the rat is subjected to increased oxidative stress. However, a decrease in CAT levels in the kidneys was also reported by Ponce-Canchihuamán *et al.* (2010) after intraperitoneal administration of 25 mg/0.5 mL of food addictive weekly.

Results from histopathological examination of tissues help categorise the type of lesions caused by xenobiotics and are recognised as the most sensitive endpoint for detecting organ toxicity (Miao *et al.,* 2022). These results are also valuable for providing evidence of acute or chronic effects of exposure to toxic substances that may not be detected by other biomarkers (Jadhav *et al.,* 2007).

Light microscopic examination of the potassium sorbate treated groups in this study revealed various degrees of histological

changes in the CA1 and dendate gyrus region of the hippocampus, which include the presence of necrotic pyramidal cell (with neuronal cytoplasmic shrinkage and intense eosinophilia accompanied by shrinkage and basophilia of the nucleus), cell membrane loss, perineuronal vacuolation, cytoplasmic vacuolation, presence of degenerating pyramidal cells, lesions in the vicinity of necrotic neuron, inflammatory cells, clumping of cells, and pyknotic nucleus when compared with the control group suggesting the toxic effects of potassium sorbate exposure. These changes were dose-dependent, with higher doses causing more damaging effects. The necrosis of pyramidal cells may result from oxidative stress due to the depletion of the antioxidant system by potassium sorbate exposure. Apoptotic alteration might be followed by swelling of organelle especially the mitochondria, endoplasmic reticulum and rupture of lysosomes, which might lead to amorphous eosinophilic cytoplasm as an initial sign in the sequence of necrosis of neurons before shrinking and dissolution of nuclei, also the leakage of lysosomal hydrolytic enzymes that lead to cell digestion by lytic enzymes (Xiang et al., 2024). The presence of pyknotic nuclei and the degenerating cells agreed with the findings of Mohammad *et al.* (2023) (Mohammad *et al.,* 2023), who also reported the appearance of some degenerating cells with pyknotic nuclei. This finding was also consistent with the results of some authors, who attributed these results to the direct effect of lead on the hippocampal neurons (Ben-Azu *et al.,* 2022).

Astrocytes are the main types of glial cells involved in regulating the immune response to pathological processes in the brain (Fisher and Liddelow, 2024). Functional activation of astrocytes and the resulting neuroinflammation are associated with infection, autoimmunity, and pathogenesis of neurodegenerative diseases. The increase in inflammatory cells in our result may be due to potassium sorbate exposure. An increase in these inflammatory cells can increase the production and release of inflammatory cytokines (Bhol *et al.,* 2024), enhance the generation of reactive oxygen species (ROS) (Yu *et al.,* 2022), impede antioxidant activity, and result in neuronal injury or neuronal loss in the brain or other parts of the central nervous system (Boroujeni *et al.,* 2021). These neurodegenerative changes could invariably impair the activities of the hippocampus in memory formation, learning, storage and retrieval of information. The findings lend credence to previous reports of Dara *et al.* (2023) (Dara *et al.,* 2023), who observed neuronal damage in the cerebral cortex, hippocampus and cerebellum, with neurodegeneration of CA1 and CA3 regions of Sprague Dawley rats exposed to food additives. Given the potential neurodegenerative effects of disrupted neuroimmune function, we also examined the volume of the hippocampus. Our result showed that the volume increased in the group treated with the highest dose of PS compared to the Control group, although it was not significant. We also observed a decrease in the hippocampus volume in Wistar rats treated with a lower dose of PS compared to the Control and the high-dose treated group. This decrease in hippocampal volume disagrees with the findings of Piper, 2017 (Piper and Piper, 2017).

Conclusion: The effect of adult Wistar rats' exposure to different doses of potassium sorbate orally was evaluated in this study. From this study, it can be inferred that Wistar rats' exposure to increasing doses of potassium sorbate induced an increase in body weight, the brain somatic index, and an increase in the volume of the hippocampus. Potassium sorbate exposure led to toxicity in the brain by inducing oxidative stress and causing an increase in the number of activated astrocytes, neuronal nuclear and Bcl-2 cells in the hippocampus of Wistar rats in a dose-dependent manner. This results in distortion in the cytoarchitecture of the hippocampal region and may lead to learning and memory deficits.

REFERENCES

Adwas, A. A., Elsayed, A., Azab, A. E., & Quwaydir, F. A. (2019). Oxidative stress and antioxidant mechanisms in human body. *Journal of Applied Biotechnology & Bioengineering*, 6(1), 43-47.

Ahn, B., Ranjit, R., Premkumar, P., Pharaoh, G., Piekarz, K. M., Matsuzaki, S., Claflin, D. R., Riddle, K., Judge, J., & Bhaskaran, S. (2019). Mitochondrial oxidative stress impairs contractile function but paradoxically increases muscle mass via fibre branching. *Journal of Cachexia, Sarcopenia and Muscle*, 10(2), 411-428.

Alkadhi, K. A. (2019). Cellular and molecular differences between area CA1 and the dentate gyrus of the hippocampus. *Molecular Neurobiology*, 56(9), 6566-6580.

Anand, S., & Sati, N. (2013). Artificial preservatives and their harmful effects: looking toward nature for safer alternatives. *International Journal of Pharmaceutical Sciences and Research*, 4(7), 2496-2501.

Aruoma, O. I. (1998). Free radicals, oxidative stress, and antioxidants in human health and disease. *Journal of the American Oil Chemists' Society*, 75(2), 199-212.

Ben-Azu, B., Adebayo, O. G., Wopara, I., Aduema, W., Onyeleonu, I., Umoren, E. B., Kolawole, T. A., Ebo, O. T., Akpotu, A. E., & Ajibo, D. N. (2022). Lead acetate induces hippocampal pyramidal neuron degeneration in mice via up-regulation of executioner caspase-3, oxido-inflammatory stress expression and decreased BDNF and cholinergic activity: Reversal effects of Gingko biloba supplement. *Journal of Trace Elements in Medicine and Biology*, 71, 126919.

Bhol, N. K., Bhanjadeo, M. M., Singh, A. K., Dash, U. C., Ojha, R. R., Majhi, S., Duttaroy, A. K., & Jena, A. B. (2024). The interplay between cytokines, inflammation, and antioxidants: Mechanistic insights and therapeutic potentials of various antioxidants and anti-cytokine compounds. *Biomedicine & Pharmacotherapy*, 178, 117177.

Boroujeni, M. E., Simani, L., Bluyssen, H. A., Samadikhah, H. R., Zamanlui Benisi, S., Hassani, S., Akbari Dilmaghani, N., Fathi, M., Vakili, K., & Mahmoudiasl, G.-R. (2021). Inflammatory response leads to neuronal death in human post-mortem cerebral cortex

in patients with COVID-19. *ACS Chemical Neuroscience*, 12(12), 2143-2150.

Burdock, G. A., & Carabin, I. G. (2004). Generally recognized as safe (GRAS): history and description. TOXICOLOGY LETTERS, 150(1), 3-18.

Conrad, C. D., Galea, L. A., Kuroda, Y., & McEwen, B. S. (1996). Chronic stress impairs rat spatial memory on the Y maze, and this effect is blocked by tianeptine treatment. *Behavioral Neuroscience*, 110(6), 1321.

Dara, O. A., Lopez-Guede, J. M., Raheem, H. I., Rahebi, J., Zulueta, E., & Fernandez-Gamiz, U. (2023). Alzheimer's disease diagnosis using machine learning: a survey. *Applied Sciences*, 13(14), 8298.

Deisseroth, A., & Dounce, A. L. (1970). Catalase: Physical and chemical properties, mechanism of catalysis, and physiological role. *Physiological Reviews*, 50(3), 319-375.

Dellu, F., Mayo, W., Cherkaoui, J., Le Moal, M., & Simon, H. (1992). A two-trial memory task with automated recording: study in young and aged rats. *Brain Research*, 588(1), 132-139.

Demirci-Cekic, S., Özkan, G., Avan, A. N., Uzunboy, S., Çapanoğlu, E., & Apak, R. (2022). Biomarkers of oxidative stress and antioxidant defense. *Journal of Pharmaceutical and Biomedical Analysis*, 209, 114477.

Dotan, Y., Lichtenberg, D., & Pinchuk, I. (2004). Lipid peroxidation cannot be used as a universal criterion of oxidative stress. *Progress in Lipid Research*, 43(3), 200-227.

EFSA Panel on Food Additives and Nutrient Sources added to Food (ANS), 2015. Scientific Opinion on the re-evaluation of sorbic acid (E 200), potassium sorbate (E 202) and calcium sorbate (E 203) as food additives. *EFSA Journal*, 13(6), p.4144.

Ennaceur, A., & Delacour, J. (1988). A new one-trial test for neurobiological studies of memory in rats. 1: Behavioral data. *Behavioural Brain Research*, 31(1), 47-59.

Fisher, T. M., & Liddelow, S. A. (2024). Emerging roles of astrocytes as immune effectors in the central nervous system. TRENDS IN IMMUNOLOGY, Volume 45, Issue 10, 824 - 836

Friedman, J. (2011). Why is the nervous system vulnerable to oxidative stress? *Oxidative Stress and Free Radical Damage in Neurology*, 19-27.

Goldstein, M., & Watkins, S. (2008). Immunohistochemistry. CURRENT PROTOCOLS IN MOLECULAR BIOLOGY, 81(1), 14.16. 11-14.16. 23.

Jahan, S. (2024). Food additives and brain complications: A risk to public health. JOURNAL OF APPLIED AND NATURAL SCIENCE, 16(1), 146-157.

Lee, S. G., Yoo, D. Y., Jung, H. Y., Nam, S. M., Kim, J. W., Choi, J. H., Yi, S. S., Won, M.-H., Yoon, Y. S., & Hwang, I. K. (2015). Neurons in the hippocampal CA1 region, but not the dentate gyrus, are susceptible to oxidative stress in rats with streptozotocin-induced type 1 diabetes. *Neural Regeneration Research*, 10(3), 451-456.

Miao, Y., Wang, D., Chen, Y., Zhu, X., Tang, X., Zhang, J., Zhang, L., & Chen, J. (2022). General toxicity and genotoxicity of alternariol: A novel 28-day multi-endpoint assessment in male Sprague–Dawley rats. MYCOTOXIN RESEARCH, 38(4), 231-241.

Mohammad, H. M., El-Baz, A. A., Mahmoud, O. M., Khalil, S., Atta, R., & Imbaby, S. (2023). Protective effects of evening primrose oil on behavioral activities, nigral microglia and histopathological changes in a rat model of rotenone-induced Parkinsonism. *Journal of Chemical Neuroanatomy*, 127, 102206.

Molaei, S., Soleimani, A., Rabiei, V., & Razavi, F. (2021). Impact of chitosan in combination with potassium sorbate treatment on chilling injury and quality attributes of pomegranate fruit during cold storage. *Journal of Food Biochemistry*, 45(4), e13633.

Morris, C. M., Büttner, A., & Weis, S. (2025). Nutritional and toxic disorders. *In Greenfield's Neuropathology* 10e Set (pp. 1407-1444). CRC Press.

Nagasinduja, V., & Shahitha, S. (2019). Food preservatives-types, uses and side effects. *International Journal of Basic and Applied Research*, 9(4), 632-637.

Nunez, J. (2008). Morris water maze experiment. *Journal of Visualized Experiments*: JoVE(19), 897.

Percy, M. E. (1984). Catalase: an old enzyme with a new role? *Canadian Journal of Biochemistry and Cell Biology*, 62(10), 1006-1014.

Piper, J. D., & Piper, P. W. (2017). Benzoate and sorbate salts: a systematic review of the potential hazards of these invaluable preservatives and the expanding spectrum of clinical uses for sodium benzoate. *Comprehensive Reviews in Food Science and Food Safety*, 16(5), 868-880.

Piper, P. W. (2018). Potential safety issues surrounding the use of benzoate preservatives. Beverages, 4(2), 33.

Pressman, P., Clemens, R., Hayes, W., & Reddy, C. (2017). Food additive safety: A review of toxicologic and regulatory issues. *Toxicology Research and Application*, 1, 2397847317723572.

Priya, K. S., Rani, V. P., & Nancy, A. A. (2021). Predictive Toxicology and Toxicogenomics of Potassium Sorbate-Gene-Diseases Association. JOURNAL OF CHEMICAL HEALTH RISKS, 5, 197.

Raposa, B., Pónusz, R., Gerencsér, G., Budán, F., Gyöngyi, Z., Tibold, A., Hegyi, D., Kiss, I., Koller, Á., & Varjas, T. (2016). Food additives: Sodium benzoate, potassium sorbate, azorubine, and tartrazine modify the expression of NFκB, GADD45α, and MAPK8 genes. *Physiology International (Acta Physiologica Hungarica),* 103(3), 334-343.

Roberts, A. (2016). The safety and regulatory process for amino acids in Europe and the United States. *The Journal of Nutrition*, 146(12), 2635S-2642S.

Sahu, F. M. (2016). Food Additives: making food taste better and safer. *Beverages & Food World*, 43(6), 21-28.

Sarnyai, Z., Sibille, E. L., Pavlides, C., Fenster, R. J., McEwen, B. S., & Tóth, M. (2000). Impaired hippocampal-dependent learning and functional abnormalities in the hippocampus in mice lacking serotonin1A receptors. *Proceedings of the National Academy of Sciences*, 97(26), 14731-14736.

Sharma, H., & Rajput, R. (2023). The science of food preservation: A comprehensive review of synthetic preservatives. *Journal of Current Research in Food Science*, 4(2), 25-29.

Sivaprasad, R., Nagaraj, M., & Varalakshmi, P. (2004). Combined efficacies of lipoic acid and 2, 3-dimercaptosuccinic acid against lead-induced lipid peroxidation in rat liver. THE JOURNAL OF NUTRITIONAL BIOCHEMISTRY, 15(1), 18-23.

Sparks, T. C., Hahn, D. R., & Garizi, N. V. (2017). Natural products, their derivatives, mimics and synthetic equivalents: role in agrochemical discovery. *Pest Management Science*, 73(4), 700-715.

Trasande, L., Shaffer, R. M., Sathyanarayana, S., Council on Environmental Health, Lowry, J. A., Ahdoot, S., Baum, C. R., Bernstein, A. S., Bole, A., Campbell, C. C., Landrigan, P. J., Pacheco, S.E., Spanier, A. J. & Woolf, A. D. (2018). Food additives and child health. *Pediatrics*, 142(2), e20181410.

Weiss, B. (2000). Vulnerability of children and the developing brain to neurotoxic hazards. *Environmental Health Perspectives*, 108(suppl 3), 375-381.

Wright, J. W., Davies, K. F., Lau, J. A., McCall, A. C., & McKay, J. K. (2006). Experimental verification of ecological niche modeling in a heterogeneous environment. *Ecology*, 87(10), 2433-2439.

Xiang, L., Lou, J., Zhao, J., Geng, Y., Zhang, J., Wu, Y., Zhao, Y., Tao, Z., Li, Y., & Qi, J. (2024). Underlying Mechanism of Lysosomal Membrane Permeabilization in CNS Injury: A Literature Review. *Molecular Neurobiology*, 1-17.

Xiao, N., Ruan, S., Mo, Q., Zhao, M., Liu, T., & Feng, F. (2024). Effects of potassium sorbate on systemic inflammation and gut microbiota in normal mice: A comparison of continuous intake and washout period. *Food and Chemical Toxicology*, 184, 114443.

Yoo, J.-K. (2024). Neurological Reaction to Food Additives: Neurotoxic Effects of Food Additives. IntechOpen. doi: 10.5772/intechopen.114358

Yu, W., Tu, Y., Long, Z., Liu, J., Kong, D., Peng, J., Wu, H., Zheng, G., Zhao, J., & Chen, Y. (2022). Reactive oxygen species bridge the gap between chronic inflammation and tumor development. *Oxidative Medicine and Cellular Longevity*, 2022(1), 2606928.