ISSN : 0300-1652

Indexed and archived with PubMed/MEDLINE

nmj

NIGERIAN MEDICAL JOURNAL

Vol. 54, Number 2, March - April 2013

Phosphatase and tensin homologue deleted on chromosome 10
Imran Haruna Abdulkareem, Maria Blair 79-86

Household cost of antenatal care and delivery services in a rural community of Kaduna state, northwestern Nigeria
Mohd Nasiq Sambo, Gobir A. Abdulrazaq, Anthony F. Shamang, Ahmad A. Ibrahim 87-91

Beneficial effects of low dose *Musa paradisiaca* on the semen quality of male Wistar rats
A. S. Alabi, Gabriel O. Omotoso, B. U. Enaibe, O. B. Akinola, C. N. B. Tagoe 92-95

Anti-malaria prescription in pregnancy among general practitioners in Enugu state, south east Nigeria
Emmanuel Onyebuchi Ugwu, E. S. Iferikigwe, S. N. Obi, A. O. Ugwu, P. U. Agu, O. A. Okezie 96-99

Effects of indomethacin on expression of PTEN tumour suppressor in human cancers
Imran Haruna Abdulkareem, Maria Blair 100-106

Teething myths among nursing mothers in a Nigerian community
Opeodu Olanrewaju Ige, Popoola Bamidele Olubukola 107-110

Indications and findings at colonoscopy in Ilorin, Nigeria
Abdulfatai Bamidele Olokoba, Olusegun Ayodeji Obateru, Mathew Olumuyiwa Bojuwoye, Samuel Adegboyega Olatoke, Oladimeji Akeem Bolarinwa, Lateefat Bukola Olokoba 111-114

Impact of health education intervention on malaria prevention practices among nursing mothers in rural communities in Nigeria
Olorunfemi Emmanuel Amoran 115-122

A PUBLICATION OF NIGERIA MEDICAL ASSOCIATION

Currently listed in Index Copernicus, African Index Medicus, AJOL and Bioline

Online full text @ www.nigeriamedj.com

PubMed

Wolters Kluwer Health | Medknow

ORIGINAL ARTICLE

Beneficial effects of low dose *Musa paradisiaca* on the semen quality of male Wistar rats

A. S. Alabi, Gabriel O. Omotoso, B. U. Enaibe, O. B. Akinola, C. N. B. Tagoe

Department of Anatomy, College of Health Sciences, University of Ilorin, Ilorin, Nigeria

ABSTRACT

Background: This study aimed at determining the effects of administration of mature green fruits of *Musa paradisiaca* on the semen quality of adult male Wistar rats. **Materials and Methods:** The animals used for the study were grouped into three: the control group, given 2 ml of double distilled water, a low dose group given 500 mg/kg/day and a high dose group given 1000 mg/kg/day of the plantain fruits, which was made into flour, and dissolved in 2 ml of double distilled water for easy oral administration. **Results:** Significant increment in the semen parameters was noticed in animals that received a lower dose of the plantain flour, but those animals who received the high dose had marked and very significant reduction in sperm cell concentration and percentage of morphologically normal spermatozoa. **Conclusion:** *Musa paradisiaca* should be consumed in moderate quantities in order to derive its beneficial effects of enhancing male reproductive functions.

Key words: *Musa paradisiaca*, rats, semen parameters

Address for correspondence:
Dr. Gabriel O. Omotoso,
Department of Anatomy,
Faculty of Basic Medical Sciences,
College of Health Sciences,
University of Ilorin,
P.M.B. 1515, Ilorin, Nigeria.
E-mail: gabrielolaiya@yahoo.com

INTRODUCTION

Musa paradisiaca (plantain) is a crop in the genus *Musa* and all members of the genus are indigenous to the tropical and subtropical countries.[1,2] It has been cultivated for more than 4000 years, and its several varieties are staple food in the tropical regions of the world.[3] *Musa paradisiaca* promotes healthy digestion, improves affective state, helps in the retention of and serves as good sources of potassium, calcium, phosphorus and nitrogen, which build and regenerate tissues in the body, and is also a rich source of iron and vitamins, especially Vitamins C and E.[1-3] Green plantain is also high in total dietary fibre content, especially hemicelluloses, which is higher than in most fruits and vegetables.[4] The high fibre contents, particularly insoluble fibre, can lower glycaemic response by forming a physical barrier to enzymatic hydrolysis of starch. The leaves, roots and fruits of plantain have been a revolutionary breakthrough in the management of male sexual inadequacies.[5,6]

Infertility is a public health concern in many developing nations of the world due to its high prevalence and especially because of its serious social implications.[7] Infertility has social, economic and personal effects, which go beyond childlessness, and women bear the major brunt of the burden.[8] It is a major cause of marital disharmony and separation, and personal misery in some other population groups.[9] The highest prevalence is in low resource countries, particularly in sub-Saharan Africa.[8] Male infertility can be caused by poor penile erection, abnormal sperm quality and volume, abnormal ejaculation, among other causes. Researches into natural diets like plantain showed that its consumption by men could enhance some reproductive functions, and also alleviate certain reproductive dysfunctions.[6,10] The aim of the current study, therefore, is to determine the effects of consumption of mature green plantain fruits on semen quality in normal adult Wistar rats.

Access this article online	
Quick Response Code:	Website: www.nigeriamedj.com
	DOI: 10.4103/0300-1652.110035

MATERIALS AND METHODS

The study was carried out in conformity with the rules and guidelines of the Animal Ethics Committee of the University of Ilorin. Eighteen (18) adult male Wistar rats of average weight of 200 g were obtained and maintained in the Animal House of the College of Health Sciences, University of Ilorin. The animals were kept at normal room temperature and food and water made available *ad libitum*. They were grouped into three, each group having six Wistar rats.

Preparation of the plantain flour

Green plantain fruits were obtained from a market in Ilorin, Nigeria. The fruits were cut longitudinally into chips

of about 5 mm thickness and air-dried for 4 days after which they were grinded and made into flour. Two doses of the plantain flour were prepared: 500 mg/kg/day and 1000 mg/kg/day. The flour was dissolved in 2 ml of double distilled water, for easy administration.

Animal grouping

The animals were divided into three groups:

Group A: Control (2 ml double distilled water, p.o.)
Group B: Given low dose *Musa paradisiaca* (500 mg/kg/day, p.o.)
Group C: Given high dose *Musa paradisiaca* (1000 mg/kg/day, p.o.).

The treatment lasted for a period of 28 days.[10,11]

Animal sacrifice

Twenty-four (24) hours after the 28th day of treatment, the rats were sacrificed by cervical dislocation, and the testes and epididymis excised using a midline abdominal incision. The testes were immediately weighed and the left caudal epididymis transferred into sterile bottles containing 2 ml of normal saline for semen analysis.

Semen analysis: Sperm concentration

A modified method of Yokoi and Mayi[12] was adopted in counting the spermatozoa, with the aid of the new improved Neuber's Counting Chamber (haemocytometer). About 10 µl of the diluted sperm suspension was transferred to each counting chamber of the haemocytometer and was allowed to stand for 5 min, and thereafter observed under a binocular light microscope.[12,13]

Sperm motility

The fluid from the caudal epididymis was diluted with Tris buffer solution[14] to 0.5 ml. An aliquot of this solution was observed under the light microscope. The mean motility estimation was reported as the final motility score for each sample, and presented in percentages.

Sperm morphology

The morphology of the spermatozoa was determined using the original dilution for motility, diluted 1:20 with 10% neutral buffered formalin. The sperm cells were categorized based on the presence of one or more abnormal features, such as tail defects (short, irregular coiled or multiple tails); neck and middle piece defects (distended, irregular, bent middle piece, abnormally thin middle piece); and head defects (round head, small or large size, double or detached head). Findings were expressed as percentage of morphologically normal sperm.[15]

Life–death ratio

Life–Death ratio was taken as, number of spermatozoa alive divided by total number of spermatozoa multiplied by 100.

(No. of spermatozoa alive ÷ Total No. of spermatozoa) × 100

Statistical analysis

Data were analyzed statistically by application of Student's *t*-test, using the SPSS version 15.0 software and presented as mean and standard error mean (SEM). Values of $P < 0.05$ were considered to be statistically significant.

RESULTS

The plantain flour was well tolerated, with no signs suggestive of regurgitations after oral administration. There was a relative gain in weight in the treated groups, and the weight gain was more in the group given the low dose *Musa paradisiaca* (Group B) with statistically significant difference ($P < 0.05$), while the weight gain recorded in the high dose group (Group C) was lower than in Group B ($P > 0.05$) [Table 1].

The semen parameters obtained in the treated groups showed statistically significant differences between the two groups given *Musa paradisiaca* ($P < 0.05$) [Table 2 and Figure 1]. The animals administered with low dose of *Musa paradisiaca* had a slight increase in sperm count, which was not statistically significant ($P > 0.05$), whereas a high dose of *Musa paradisiaca* resulted in a significantly decreased sperm concentration ($P < 0.05$) compared with the control group.

The percentage motility increased in Wistar rats given low dose of *Musa paradisiaca*, but decreased slightly in the high dose group ($P > 0.05$) compared with the control [Table 2]. Administration of *Musa paradisiaca* caused reduction in the number of morphologically normal sperm, with a very marked reduction noticed in the high dose group ($P < 0.05$) compared with the control animals [Table 2 and Figure 1].

There was no significant difference in the Life–Death ratio between the control animals and the high dose group ($P > 0.05$), but in the low dose group, whereas there was a significant increase compared with the control ($P < 0.05$) [Table 2 and Figure 1]. Sperm progressivity

Table 1: Weights of rats and testes following administration of *Musa paradisiaca*

Treatment groups	Final body weight[a] (g)	Initial body weight[a] (g)	Body weight difference[a] (g)	Testis weight[a] (g)	Testis-body weight ratio
A: Control	226.67±13.08	228.33±12.22	1.66	1.23±0.048	0.0054
B: 500 mg/kg/day	187.50±2.14	170.00±2.58	17.5*	0.93±0.111	0.0050
C: 1000 mg/kg/day	285.00±6.32	270.00±6.32	15.0	1.18±0.085	0.0041

[a]Mean (SEM), *Statistically significant difference ($P<0.05$)

Table 2: Results of semen analysis

Parameters	A: Control	B: 500 mg/kg/day	C: 1000 mg/kg/day
Sperm count (×106)[a]	60.15±1.73	61.30±2.27[†]	51.30±0.58[*†]
Motility (%)[a]	85.88±1.80	90.53±0.49[†]	84.58±0.95[†]
Morphology (×106)[a]	77.25±2.78	76.00±3.39[†]	58.00±2.48[*†]
Life/death ratio (%)[a]	88.48±1.69	95.68±0.94[*†]	88.28±0.92[†]
Progressivity	A	A/B	B

[a]mean (SEM), *Significant statistical difference with the control group (P<0.05), [†]Significant statistical difference between treatment groups (P<0.05), A – Excellent forward directional movement; B – Good forward directional movement

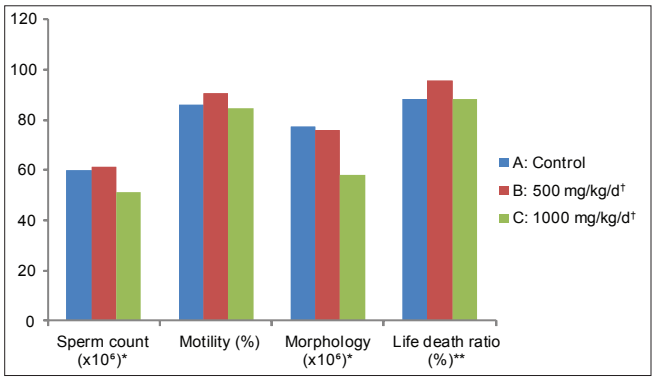

Figure 1: Semen parameters following administration of *Musa paradisiaca* to Wistar rats. [†]Significant statistical difference between the low dose and high dose groups (P < 0.05) of all the parameters. *Significant statistical difference between the high dose groups and the Control Group (P < 0.05). **Significant statistical difference between the low dose group and the Control Group (P< 0.05)

was reduced in the high dose group, but the low dose group had forward directional movement almost similar to those of the control group [Table 2].

DISCUSSION

Musa paradisiaca has been documented to have many beneficial effects in the management of several diseased conditions, including atherosclerosis, diabetes mellitus, hypertension, hyperlipidaemia and thyroid dysfunctions[16-21] and also offers protective effects on organs of the body, such as the kidneys, in certain clinical conditions.[22] Yakubu *et al.*[6] reported that plantain fruits can be used in the management of sexual dysfunctions, though the exact mechanism of action or how it enhances this is not known. Similarly, studies conducted on methanolic extract of *Musa paradisiaca* (MEMP) fruit[10] revealed that animal models with diabetic-induced testicular disorders can have the testicular damage reversed, when given MEMP. The precise mechanism of action by which MEMP does this is still unclear. *Musa paradisiaca* has hypoglycaemic effects in both normal and diabetic animal models, and this might be a reason for its ability to facilitate improvement in male sexual functions in diabetic animals.[10,20,23,24] This is true when the mature green fruit of plantain is consumed at a moderate dose, as revealed in the current study, where consumption of *Musa paradisiaca* at a low dose led to improvement in the quantity and quality of spermatozoa in adult Wistar rats. Specifically, sperm motility was improved, with a very significant increase in life/death ratio of spermatozoa, and a progressivity very similar to that of the control.

In animals given a higher (double) dose of *Musa paradisiaca,* all the semen parameters investigated were adversely affected. Both the sperm count and percentage of morphologically normal sperm cells were significantly reduced (P < 0.05) compared with the control animals. A good percentage of spermatozoa observed had some of the abnormal morphological features listed below: Tail defects (short, irregular coiled or multiple tails); neck and middle piece defects (distended, irregular, bent middle piece, abnormally thin middle piece); and head defects (round head, small or large size, double or detached head). These findings would definitely negatively impart the normal sexual functions of the animals, thereby reducing their ability to fertilise an ovum successfully.

At a higher dose of plantain fruit, the percentage motility and Life/Death ratio did not significantly alter, but the forward directional movement was reduced when compared with the control. Nevertheless, motile abnormal sperm cells are not expected to perform the functions of successful fertilization, as do motile and morphologically normal sperm cells.

Conclusively, the mature green fruit of *Musa paradisiaca* improves semen parameters of Wistar rats at a moderate dose, making it a possible remedy for male reproductive dysfunctions in which sperm cells have been adversely impaired.

REFERENCES

1. Khare CP. Indian Medicinal Plants. New York: Springer Science Business Media; 2007.
2. Ghani A. Medicinal plants of Bangladesh: Chemical constituents and uses. 2nd ed. Dhaka, Bangladesh: The Asiatic Society of Bangladesh; 2003.
3. Imam MZ, Akter S. *Musa paradisiaca* L. and *Musa sapientum* L.: A phytochemical and pharmacological review. J Appl Pharma Sci 2011;1:14-20.
4. Kirtikar KR, Basu BD. *Musa paradisiaca* in Indian medicinal plant. vol 4. Delhi: Rexiodical Experts Book Agency; 1991.
5. Grill LS. Ethnomedical use of plants in Nigeria. Benin, Nigeria: UniBen Press; 1992.
6. Yakubu MT, Akanji M, Oladiji AT. Male sexual dysfunction and methods used in assessing medicinal plants with Aphrodisiac potentials. Pharmacog Rev 2007;1:1.
7. Araoye MO. Epidemiology of infertility: Social problems of the infertile couples. West Afr J Med 2003;22:190-6.
8. Sharma S, Mittal S, Aggarwal P. Management of infertility in low resource countries. BJOG 2009;116:77-83.
9. Ola TM. The socio-cultural perception and implications of

childlessness among men and women in an urban area, Southwest, Nigeria. J Soc Sci 2009;21:205-9.
10. Ojewole J, Adewumi C. Hypoglycemic effect of methanolic extract of *Musa paradisiaca* green fruits in normal and diabetic mice. Met Findings Exp Clin Pharmacol 2003;25:453-6.
11. Omotoso GO, Oyewopo AO, Kadir RE, Olawuyi ST, Jimoh AA. Effects of Aqueous Extract of *Allium sativum* (Garlic) on semen parameters in Wistar Rats. Internet J Urol 2010;7:2.
12. Yokoi K, Mayi ZK. Organ apoptosis with cytotoxic drugs. Toxicology 2004;290:78-85.
13. Omotoso GO, Onanuga IO, Jimoh AA. Effects of ascorbic acid on garlic-induced alterations in semen parameters of wistar rats. Trop J Health Sci 2011;18:55-8.
14. Sonmez M, Turk G, Yuce A. The effects of as ascorbic supplementation on sperm quality, lipid peroxidation and testosterone levels of male Wister rats. Theriogenology 2005;63:2063-72.
15. Saalu LC, Osinubi AA, Jewo PI, Oyewopo AO, Ajayi GO. An evaluation of influence of *citrus paradise* seed extract on doxorubicin-induced testicular oxidative stress and impaired spermatogenesis. Asian J Sci Res 2010;3:51-61.
16. Mallick C, Maiti R, Ghosh D. Comparative Study on Antihyperglycemic and Antihyperlipidemic Effects of Separate and Composite Extract of Seed of *Eugenia jambolana* and Root of *Musa paradisiaca* in Streptozotocin-induced Diabetic Male Albino Rat. Iranian J Pharmacol Ther 2006;5:27-33.
17. Mallick C, Chatterjee K, GuhaBiswas M, Ghosh D. Antihyperglycemic Effects of Separate and Composite Extract of Root of *Musa paradisiaca* and Leaf of Coccinia indica In Streptozotocin-Induced Diabetic Male Albino Rat. Afr J Trad Compl Med 2007;4:362-71.
18. Su-min W, Geng-liang Y, Hong-yan D, Ting-mei P, Yang-li W. Effect of plantain seed on the lipid peroxidation in rats with hyperlipidemia. Chinese J Clin Rehabil 2006;10:19.
19. Parmar HS, Kar A. Protective role of Citrus sinensis, *Musa paradisiaca*, and *Punica granatum* peels against diet-induced atherosclerosis and thyroid dysfunctions in rats. Nutr Res 2007;27:710-8.
20. Singh SK, Kesari AN, Rai PK, Watal G. Assessment of Glycemic Potential of *Musa paradisiaca* Stem Juice. Indian J Clin Biochem 2007;22:48-52.
21. Orie N. Direct Vascular Effects of Plantain extract in rats. Exp Physiol 1997;82:501-6.
22. Vinaykumar T, Sunath MG, Suman L, Vijayan V, Sriniva-Sarao D, Sharmila AM, *et al*. Renoprotective and testicular protective effect of *Musa paradisiaca* flower extract in streptozotocin-induced diabetic rats. JITPS 2010;1:106-14.
23. Mallick C, Bera TK, Ali KM, Chatter JK. Diabetes-induced testicular disorders, vis-a-viz germ cell apoptosis in albino rat: Remedial effect of hexane fraction of root of *Musa paradisiaca* and leaf of Coccinia indica. J Health Sci 2010;56:641-54.
24. Pari L, Maneswani JU. Hypoglycemic effect of *Musa paradisiaca* in alloxan-induced diabetic rats. J Ethnopharmacol 1999;68:321-5.

How to cite this article: Alabi AS, Omotoso GO, Enaibe BU, Akinola OB, Tagoe C. Beneficial effects of low dose *Musa paradisiaca* on the semen quality of male Wistar rats. Niger Med J 2013;54:92-5.

Source of Support: Nil, **Conflict of Interest:** None declared.