

Kikelomo T. Adesina, Olumuyiwa A. Ogunlaja, Adebunmi O. Olarinoye*, Abiodun P. Aboyeji, Halimat J. Akande, Adegboyega A. Fawole and Abiodun S. Adeniran

An observation of umbilical coiling index in a low risk population in Nigeria

<https://doi.org/10.1515/jpm-2017-0170>

Received January 26, 2016. Accepted August 17, 2017.

Abstract

Objectives: The umbilical coiling index (UCI) is one of cord parameters for foetal assessment with limited studies in our environment. With recent advances in its evaluation, its significance, pattern, abnormalities and correlates need to be defined in our parturients.

Methods: The umbilical cords of 436 neonates were examined. Gross examination was done within 5 min of delivery. The UCI was defined as the number of complete coils per centimetre of cord. Normal UCI was defined as values between the 10th and 90th percentiles of the study population.

Results: The mean umbilical cord length was 52.7 ± 11.5 cm, mean number of coils was 10.8 ± 5.1 and mean UCI was 0.21 ± 0.099 . The range was between 0.0 and 1.0. UCI values of 0.13 and 0.30 were 10th and 90th percentiles, respectively. Normal UCI was observed in 351 (80.5%) neonates, 44 (10.4%) and 41 (9.1%) had hypo- and hypercoiled cords, respectively. Congenital abnormalities occurred in the normocoiled and hypercoiled groups but was not demonstrated in the hypocoiled group. The mean value of UCI in neonates with congenital abnormalities was 0.29 ± 0.12 ($P=0.011$). There was no significant statistical relationship between foetal outcome and degree of UCI.

Conclusion: The UCI was not associated with adverse perinatal outcome in this study.

Keywords: Congenital; foetal outcome; hypercoiled cord; perinatal assessment; umbilical coiling index.

Introduction

Postpartum examination of the neonate, placenta and umbilical cord form an integral part of clinical evaluation after deliveries in an ideal setting. Findings from such examinations may suggest the need for further evaluation and management of the babies and mothers. Studies have shown that perinatal assessment of the umbilical cord may prognosticate foetal outcome [1, 2] especially when done immediately after delivery. More recently, it has become possible to determine the characteristics of the umbilical cord sonographically *in utero* [3].

Umbilical cord can be examined for cord length, diameters and cord vessels. Another parameter used in assessing the umbilical cord is the coil index, it is defined as total number of complete vascular coiling divided by the total length of the umbilical cord in centimetres [4]. The helical course of the umbilical vessels can be observed as early as 28 days' post-conception, and is clearly visible from 7 weeks' post-conception in 95% of all fetuses [1]. The origin of coiling of umbilical cords is not known but it confers turgor, strength and resilience against compression on it [5, 6]. This is very important to the vascular structures contained in the cord and has been found to correlate with perinatal outcome [7]. Probable postulates to explain the coiling are foetal movements, torsion of the embryo, differential growth of the umbilical vessels and effect of the muscular arterial wall [1, 5]. Normal umbilical cord coil index (UCI) is one coil/5 cm, i.e. 0.2 ± 0.1 coils completed per cm [1, 4, 8]. Van Dijk and others found that the mean [standard deviation (SD)] UCI was 0.17 (0.009) coils/cm in singleton uncomplicated pregnancies, and that the UCI was not influenced by gestational age at delivery, maternal age and parity, foetal sex, birth weight or mode of delivery [4].

Undercoiled/hypocoiled cords are defined as those with UCI <10th percentile, whereas overcoiled/hypercoiled cords are those with UCI >90th percentile [9, 10]. Hypercoiling and hypocoiling have been linked with various abnormalities such as foetal chromosomal abnormalities, growth restriction, death, preterm delivery, abnormal foetal heart rate tracing, low cord blood pH, meconium staining, interventional delivery for foetal distress and

*Corresponding author: Adebunmi O. Olarinoye, Department of Obstetrics and Gynaecology, University of Ilorin, Ilorin, Kwara State, Nigeria, Tel.: +2348033975764, E-mail: adebunmiolarinoye@yahoo.com

Kikelomo T. Adesina, Abiodun P. Aboyeji, Adegboyega A.

Fawole and Abiodun S. Adeniran: Department of Obstetrics and Gynaecology, University of Ilorin, Ilorin, Kwara State, Nigeria

Olumuyiwa A. Ogunlaja: Department of Obstetrics and Gynaecology, Bowen University, Iwo, Osun state, Nigeria

Halimat J. Akande: Department of Radiology, University of Ilorin, Ilorin, Kwara State, Nigeria

chorioamnionitis [8, 9], and studies differ in correlates and definitions [1].

The significance, pattern, abnormalities and correlates of coil index have not been defined in our parturient. While recent advances in fetomaternal medicine suggest a place for *in-utero* evaluation of the cord as part of perinatal care in the future [1], we do not have documentations of findings of gross parameters of umbilical cord coil during postnatal examination of the placenta in our environment, not to mention its description *in utero*. A sonographic evaluation of umbilical cord coiling in the second trimester correlates with the true UCI at birth [10]. The antenatal UCI in the form of either hypo- or hypercoiling has been associated with adverse perinatal outcomes in both antenatal and neonatal periods [11].

It is therefore important to describe the umbilical cord coil index in a cohort of Nigerian neonates and its correlates and to suggest a reference range for definition and comparison. Abnormalities of the cord coiling occur in maternal and perinatal conditions. The occurrence of such abnormalities in low risk pregnancies has not been investigated. It is hoped that findings from this study will pave way for antenatal evaluation of foetuses for umbilical cord abnormalities, thereby improving perinatal outcome in our environment, especially in high-risk pregnancies. It would therefore mean that identifications of such anomalies may predict foetal outcome in early pregnancy, even in the so-called low-risk pregnancies. Therefore, any observation of such abnormalities in utero may further heighten the index of suspicion of an adverse foetal outcome. Whether this will be useful or not, summarizes the justification for this study.

Materials and methods

The study population were apparently healthy parturients that presented in the active phase of labour. Inclusion criteria were, low-risk pregnancies, delivery at or after 28 weeks. The exclusion criteria were multiple pregnancies, mal-presentations and previously diagnosed intrauterine foetal death.

Gross examination of the umbilical cord was done within 5 min of delivery of the placenta. The umbilical cord was clamped at the foetal end and cut 5 cm from the foetal insertion with a pair of sterile scissors taking care not to milk the cord. The remaining length of the cord from the cut end to the placental insertion was then measured in centimetres (Figure 1). Five centimeter was added to the length of the measured cord. There were two observers present at each delivery. They were researcher or research assistants (investigators) and the attending midwife or doctor depending on mode of delivery. The study protocol was strictly adhered to and all measurements were taken with the same tape measure. In view of this, the expected inter/intra observer variability was negligible.

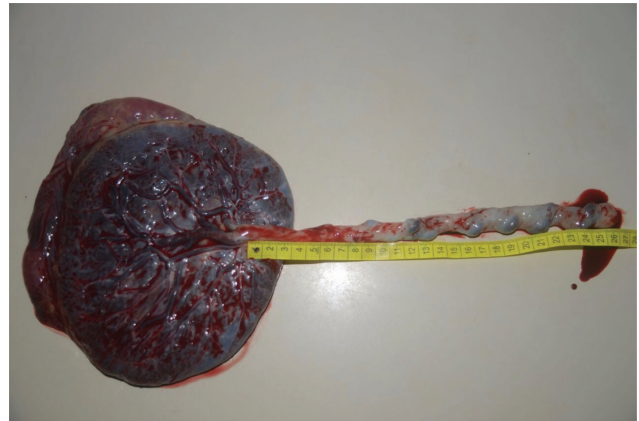

Figure 1: Measurement of cord length.

Next, the number of coils/helices of the entire cord were counted and a coil was taken as one complete 360-degree spiral course of the umbilical vessels (Figure 2). Other features such as vasculature, knotting, cord round the neck, thickness of the umbilical cord, width and circumference were examined. The placental examination also included weight and site of cord insertion into the placenta. The degree of the umbilical cord coiling was determined by the UCI, defined as the number of complete coils/helices per centimetre length of cord [12]. Normal umbilical coiling index was defined as values between the 10th and 90th percentiles of the study population. Undercoiled/hypocoiled cords were defined as those with an UCI <10th percentile, whereas overcoiled/hypercoiled cords as those with an UCI >90th percentile. The outcome measures were essentially the foetal outcome and statistical significance of available maternal parameters in relation to UCI was done. The foetal outcomes were assessed by APGAR scores, birth weight, and gestational age at delivery, congenital abnormalities and admission to neonatal intensive care unit (NICU). Congenital anomalies were grossly observed at delivery by researchers without prenatal ultrasonography. Such babies were finally evaluated by neonatologists and paediatric surgeons for further management. An APGAR score of <7 at the 5th min was considered low. Using Ballard's chart, birth weights <10th and >90th percentiles for gestational age were taken as small and large for gestational age, respectively, and any delivery before 37 weeks as premature delivery.

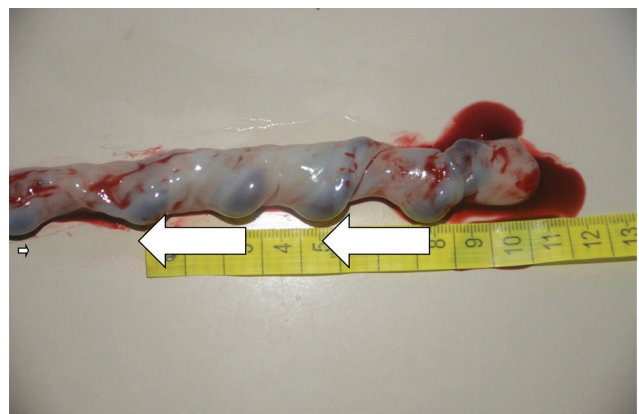


Figure 2: Umbilical coils.

Data were analysed using χ^2 test, Fisher's exact test, and the t -test where applicable. Statistical significance was defined as $P \leq 0.05$.

Results

The umbilical cords of 436 singleton neonates were examined. The mean umbilical cord length was 52.7 ± 11.5 cm while the mean number of coils was 10.8 ± 5.1 . The mean UCI was 0.21 ± 0.099 and ranged between 0.0 and 1.0. The mean birth weight was 3.1 ± 0.4 kg, 16 term neonates had birth weight of 2.5 kg or less.

Normal UCI was observed in 351 (80.5%) neonates, 44 (10.4%) and 41 (9.1%) neonates had hypo- and hypercoiled cords, respectively. There was no statistically significant difference when maternal age, parity and gestational age were compared in the hypocoiled, normocoiled and hypercoiled groups (Table 1). Similarly, birth weight per gestational age, APGAR scores at 5th min and NICU admission did not show any statistically significant difference when compared with the degree of UCI. Congenital abnormalities were not demonstrated in the hypocoiled group, whereas they occurred in both the normocoiled

and hypercoiled groups with statistically significant difference ($P = 0.009$). However, the mean value of UCI in neonates with congenital abnormalities, 0.29 ± 0.12 was not statistically significant ($P = 0.088$) as seen in (Table 2). There were five babies with congenital abnormalities as depicted in Table 3. Congenital anomalies encountered were, anencephaly, talipes equino-varum, congenital hydrocele, choanal atresia and a baby had multiple anomalies (hydraencephaly, spina bifida and achondroplasia).

Table 2: Mean UCI of some measures of foetal outcome.

Outcome	UCI Mean \pm SD	P-value
Congenital abnormalities		
Yes	0.286 ± 0.115	0.088
No	0.210 ± 0.099	
Sex of infant		
Male	0.214 ± 0.106	0.419
Female	0.206 ± 0.093	
NICU admission		
Yes	0.217 ± 0.085	0.611
No	0.210 ± 0.101	

UCI = Umbilical coiling index, P-value = significant ≤ 0.05 , SD = standard deviation.

Table 1: Comparison between maternal parameters, foetal outcome and UCI.

Feto-maternal parameters	Umbilical cord index (n=436)			Total n=436	P-value
	Low (UCI < p10) n=44 (%)	Normal (UCI p10–p90) n=351 (%)	High (UCI > p90) n=41 (%)		
Parity					
Median (IQR)	2 (1–3)	2 (1–3)	2 (1–4)	2 (1–3)	0.444
Age (years)					
Mean \pm SD	30.09 ± 5.20	29.19 ± 4.76	29.17 ± 5.77	29.28 ± 4.91	0.516
Gestational age (weeks)					
Mean \pm SD	38.75 ± 2.15	38.81 ± 1.91	38.28 ± 2.25	38.75 ± 1.97	0.265
Apgar score (at 5 min)					
<7	3 (6.8)	40 (11.2)	7 (19.4)	50 (11.5)	0.201
≥ 7	41 (93.2)	316 (88.8)	29 (80.6)	386 (88.5)	
Birth weight					
SGA	1 (2.3)	36 (10.3)	1 (2.4)	38 (8.7)	0.352
AGA	30 (68.2)	237 (67.5)	28 (68.3)	295 (67.7)	
LGA	13 (29.5)	78 (22.2)	12 (29.3)	103 (23.6)	
Mean \pm SD	3.24 ± 0.37	3.12 ± 0.45	3.15 ± 0.44	3.13 ± 0.14	0.235
NICU admission					
Yes	4 (9.1)	40 (11.4)	5 (12.2)	49 (11.2)	0.976
No	40 (90.9)	311 (88.6)	36 (87.8)	387 (88.8)	
Congenital abnormalities					
Yes	0 (0.0)	2 (0.57)	3 (7.31)	5 (1.1)	0.009
No	44 (100.0)	349 (99.4)	38 (92.7)	431 (98.9)	

IQR = Inter-quartile range, p10 = 10th percentile, p90 = 90th percentile, SGA = small for gestational age, AGA = average for gestational age, LGA = large for gestational age.

Bold value indicates statistical significance ($P \leq 0.05$).

Table 3: Showing types of congenital anomalies and foetal characteristics.

Congenital anomaly	UCI	Gestational age (weeks)	Birth weight (kg)	Apgar score 5'	UC length (mm)	UC width (mm)
Anencephaly	0.350	35	2.00	0	400.00	12.00
Choanal atresia	0.174	37	3.50	0	690.00	14.00
Hydrocele	0.148	38	3.20	5	540.00	22.00
Multiple anomalies	0.366	32	3.10	6	410.00	15.00
Talipes equino-varum	0.392	43	3.00	9	510.00	5.00

UCI = Umbilical coiling index, UC = umbilical cord, 5' = 5th min.

Discussion

The mean UCI of 0.21 ± 0.099 reported in this study was comparable to findings of others including findings from a study of uncomplicated pregnancies in the Netherlands [4, 12, 13]. Gupta et al. [14] reported a lower value of 0.13 ± 0.08 which could not be explained by other findings in their study. UCI may be an index with minimal variations across different populations and our reported mean UCI may be a reference value in low-risk pregnancies in our environment.

There was no significant statistical difference when the degree of umbilical cord coiling was compared with maternal age, parity and gestational age. This agreed with the study of uncomplicated singleton pregnancies by Van Dijk et al. [4]. The similarity in the characteristics of the study populations of our study and theirs, in spite of the geographical and racial variations probably excludes the effects of age and parity on UCI. The contributions of maternal characteristics to UCI in the presence of foetal or maternal disorders may be different and requires further investigations.

While most studies reported on the association between abnormal coiling index and perinatal outcome [8, 9, 12, 15], our study was contrary except for the occurrence of congenital abnormalities. There was no statistically significant association between umbilical coiling and foetal outcome as shown in this study. This is similar to the findings of Jessop et al. in an unselected population of low risk pregnancies. Even though, their study was conducted in a larger population, both studies are comparable on the basis of low-risk setting. Conflicting results from earlier studies were probably due to selection, size and methods of review [16].

Hypercoiling of the umbilical cord was observed in 9.1% of the neonates in this study and in three out of five reported cases of congenital abnormalities. Chitra et al. [15] in their analysis of 1000 women, found an association between hypercoiled cord and congenital anomalies. Possibly, the hypercoiling may be a compensatory mechanism of the cord to confer more strength and therefore protect the cord from further vascular damage as some

form of compromise has occurred already in the foetus. It may also be that hypercoiling of the cord is part of the maldevelopment of the cord that occurred concurrently during the embryological development of the fetuses with congenital abnormalities. Although, it is not clear whether abnormal coiling is actually a cause of pathology, or merely one of the sequelae, or both [1]. The presence of cord hypercoiling in only three babies with congenital anomalies needs further evaluation.

A limitation of our study is that karyotype studies were not conducted on the neonates and our observation of gross anomalies was used. An identification of hypercoiling in a neonate may warrant further evaluation to support or refute an initial suspicion nevertheless; normocoiling may not exclude the possibility of congenital abnormalities. Also routine prenatal diagnosis to exclude congenital or genetic disorders was not done except for occasional obstetric ultrasound scan in which no anomalies were reported prior to delivery. Prenatal screening is required for diagnosis of congenital abnormalities and is indeed not exclusive of low-risk pregnancies.

This is a report of umbilical coiling index in neonates of singleton pregnancies of apparently healthy mothers in labour without routine or adequate prenatal diagnosis in a low resource setting. It suggests a mean UCI value of 0.21 ± 0.099 . Hypercoiling and normocoiling were found in neonates with congenital abnormalities. Abnormal coiling index was not associated with another adverse perinatal outcome.

Author's statement

Conflict of interest: The authors have no conflict of interest to declare. There was no involvement of any company in this study.

Material and methods: Informed consent: Informed consent has been obtained from all individuals included in this study.

Ethical approval: The research related to human subject use has complied with all the relevant national regulations, and institutional policies, and is in accordance with the tenets of the Helsinki Declaration, and has been

approved by the authors' institutional review board or equivalent committee.

References

- [1] Laat M, Franx A, Alderen E, Nikkels P, Visser G. The umbilical coiling index, a review of the literature. *J Matern Fetal Neonat Med*. 2005;17:93–100.
- [2] Ezimokhai M, Rizk DEE, Thomas L. Abnormal vascular coiling of the umbilical cord in gestational diabetes mellitus. *Arch Physiol Biochem*. 2001;109:209–14.
- [3] Predanic M. Sonographic assessment of the umbilical cord. *Ultrasound Rev Obstet Gynecol*. 2005;5:105–10.
- [4] van Dijk CC, Franx A, de Laat MWM, Bruinse HW, Visser GHA, Nikkels PGJ. Umbilical coiling index in normal pregnancy. *J Mat Fetal Neonat Med*. 2002;11:280–3.
- [5] Malpas P, Symonds EM. Observations on the structure of the human umbilical cord. *Surg Gynecol Obstet*. 1966;123:746–50.
- [6] Strong TH, Elliot JP, Radin TG. Non-coiled umbilical vessels: a new marker for the fetus at risk. *Obstet Gynecol*. 1993;81:409–11.
- [7] Penq HQ, Levitin-Smith M, Rochelson B, Kohn E. Umbilical cord structure and over coiling are common causes of fetal demise. *Pediatr Dev Pathol*. 2006;9(1):14–9.
- [8] Machin GA, Ackerman J, Gilbert-Barness E. Abnormal umbilical cord coiling is associated with adverse perinatal outcomes. *Pediatr Dev Pathol*. 2000;3:462–71.
- [9] Ezimokhai M, Rizk DEE, Thomas L. Maternal risk factors for abnormal vascular coiling of the umbilical cord. *Am J Perinat*. 2000;17:441–5.
- [10] Predanic M, Perni SC, Chasen ST, Baergen RN, Chervenak FA. Assessment of umbilical cord coiling during the routine fetal sonographic anatomic survey in the second trimester. *J Ultrasound Med*. 2005;24:185–91.
- [11] Mittal A, Nanda S, Sen J. Antenatal umbilical coiling index as a predictor of perinatal outcome. *Arch Gynecol Obstet*. 2015;291:763–8.
- [12] Strong TH, Jarles DL, Vega JS, Feldman DB. The umbilical coiling index. *Am J Obstet Gynecol*. 1994;170:29–32.
- [13] Ercal T, Lacin S, Altunyurt S, Saygili U, Cinar O, Mumcu A. Umbilical coiling index: is it a marker for the foetus at risk? *Br J Clin Pract*. 1996;50:254–6.
- [14] Gupta S, Faridi MMA, Krishnan J. Umbilical coiling index. *J Obstet Gynecol India*. 2006;56:315–9.
- [15] Chitra T, Sushanth YS, Raghavan S. Umbilical index as a marker of perinatal outcome: an analytical study. *Obstet Gynecol Int*. 2012;2012:1–6.
- [16] Jessop FA, Lees CC, Pathak S, Hook CE, Sibire NJ. Umbilical cord coiling: clinical outcomes in an unselected population and systematic review. *Virchows Arch*. 2014;464:105–12.