ISSN: Print: 2811-1672
Online: 2811-1680

www.njbams.asmeda.org

NJBAMS

Nigerian Journal of Basic and Applied Medical Sciences

An official publication of the National
ASSOCIATION OF SPECIALIST MEDICAL DOCTORS IN ACADEMICS (ASMeDA aka MEDSABAMS)

Nigella Sativa Attenuates Trimethyltin-induced Histopathological Changes in Mice Hippocampi

Adana M.Y., Imam A., Kareem S.B., Ajao M.S.

Department of Anatomy, College of Health Sciences, University of Ilorin, Ilorin Nigeria

ABSTRACT

Background: The organotins particularly Trimethyltin (TMT) are very popular in agriculture and industry. Exposure to the compound is associated with several neurological symptoms which suggest neurotoxicity. The study was designed to investigate the antidotal effects of Nigella sativa (NS) on TMT-induced neurotoxicity on mice hippocampi.

Materials and Methods: Seventy adult male mice weighing an average of 25g were randomly assigned into seven groups of ten animals each (Groups A- G). Animals in group A were administered single dose TMT (3mg/kg) and euthanized after 48 hours. Groups B, C, and D were given a single dose of TMT (3mg/kg), followed by a single weekly dose of NS (28ml/kg) for 1, 2, and 3 weeks respectively. Groups E, F, and G served as controls for trimethyltin (3mg/kg), Nigella sativa (28ml/kg), and saline (28ml/kg) respectively. NS.

Results: The mice demonstrated tremors, aggressiveness and subtle seizures at the initial state in TMT administered groups with exophthalmos and pedal edema that subsides in the mice administered with TMT-NS. There were exudes of neuritic plaques, neurofibrillary tangles, and apoptotic cells on TMT-administered brains on histology. These observations were markedly reduced in the TMT-NS administered groups.

Conclusion: The study concludes that the neurodestructive effects of TMT on the hippocampal neurons and its ability to negatively affect the neurobehavioral attitudes of the mice could be reversible following the administration of NS.

Keywords: Nigella Sativa; trimethyltin; hippocampus, neurotoxicity

Corresponding Author:

Name: Misturah Yetunde Adana
Address: Department of Anatomy, College of Health Sciences
University of Ilorin, Ilorin, Nigeria
Email: misturahadana@gmail.com, adana.my@unilorin.edu.ng
Contact: 08033727625

INTRODUCTION

Oxidative stressors are involved in the aetiopathogenesis of most neurological disorders (1-3), and the available evidence suggests rising incidences of these disorders worldwide despite huge investments in research and therapeutic agents. Brain cells are amenable to injuries when exposed to free radicals that are mostly generated in the body (4, 5) by stress, exercise, oxidation of food, and in some cases chemical reactions that are aftermath of cellular reactions in the body (6).

Trimethyltin (TMT) chloride is an organotin white solid compound present in most pesticides and other chemical agents have been shown to have deleterious effects with selective damage to hippocampal cells (7, 8) and lesions mimicking those that are similar to the ones caused by convulsants in which the brain excitatory amino acid transmission is involved (9, 10). The neuronal subpopulations in the hippocampus have exhibited certain selective vulnerability to the effects of Trimethyltin. This leads to the observed hippocampal neurodegeneration (11).

The role of phytochemicals in neurotoxicological studies has been increasing in the last decade (12). Nigella sativa (NS) commonly referred to as black seed oil is an annual flowering plant that is mostly found in southern Asia and has been used for decades among the Arabs in the treatment of many disorders because of its free radical scavenging activities (13, 14). Due to the continued widespread use of TMT, it is imperative to study possible ways of reversing or protecting against its toxicity. Despite all the acclaimed therapeutic potentials of NS, there is a need to test the antioxidative potentials in the protection of the hippocampal cells against TMT-induced neurotoxicity using an animal model.

Cite this article as: Adana M.Y., Imam A., Kareem S.B., Ajao M.S. *Nigella sativa* attenuates trimethyltin-induced histopathological changes in mice hippocampi. Nig. J. Basic & Applied Med. Sci. 2022;1(1);57-62.

MATERIALS AND METHODS

Animals Procurement

Seventy (70) adult male BALB/c mice weighing between 25-35g were obtained from the biological garden of the University of Ilorin, Ilorin. The mice were randomly assigned into seven groups of ten (10) mice each (Groups A-G). Animals were housed in mesh cages under natural light and dark cycles at room temperature. Animals in all groups were fed normal mice laboratory chow and water ad libitum. They were kept for seven (7) days for acclimatization to the new environment. The study was approved by the University Ethical Clearance Committee with the approval number UIL/UERC/12/47AA.

Weight Taking

The initial weights of the animals were taken before the commencement of the experiment and recorded. Thereafter, the weights were taken weekly for three weeks of treatment. This was done in the mornings before administration. Recorded weights include the first (1st) day, seventh (7th) day, fourteenth (14th) day, and twenty-first (21st) day of the treatment

Preparation of TMT solution and NS oil

The TMT chloride preparation was purchased from Sigma Aldrich, Avengerlee in the USA. The working solution of trimethyltin chloride was prepared by diluting 0.04ml of trimethyltin chloride in 500ml of normal saline. The black seed oil from Al-Iman stores, Saudi Arabia was procured from a local store in Ilorin.

Administration of TMT and NS oil

Mice in group A were administered single dose of intraperitoneal TMT (3mg/kg) and euthanized 48hours after the administration. Groups B, C, and D were given single dose TMT (3mg/kg), followed by a single weekly oral dose of NS (28ml/kg) for 1, 2, and 3 weeks respectively, and euthanized on days 9, 16, and 23 of

experiment respectively. Group E had single-dose of intraperitoneal TMT (3mg/kg) and was euthanized on day 21. Group F had a single weekly oral dose of NS (28ml/kg) for 3 weeks and was euthanized on day 21 while group G animals had a single weekly oral dose of normal saline (28ml/kg) and were euthanized on day 21 of the experiment. All treatments were given intraperitoneally (table 1).

Tissue Processing for Histological Analysis

Animals were anesthetized with ketamine. They were then transcardially perfused with 4% paraformaldehyde. The brains were harvested and weighed using a sensitive weighing balance to the nearest 0.1g and processed for histological staining. Coronal sectioning of the hippocampi were carried out using a Rotatory Microtome (Leica 2125RT) into sections of 3 microns thick and then stained in Hematoxylin and Eosin (H&E) – to show basic morphology, Giemsa for apoptotic cells, Bielschowsky's Silver Stain for nerve fiber, axon, neurofibrillary tangles, and senile plaques, Cresyl violet stain for nissl substance in the cytoplasm of neurons, and Luxol fast blue for myelin and nerve cells .Data Analysis

Data among the groups were analyzed by one-way analysis of variance (ANOVA). Data were presented as means (n=10) ± standard error of mean (SEM). P-value less than 0.05 was considered to be statistically significant.

RESULTS

General observations

A few minutes following the administration of TMT, the mice demonstrated sluggishness and trembling. This was followed by aggressiveness and tremors about 12 hours post-administration. This continued till the expiration of the experimental period. However, mice co-treated with NS displayed increasing calmness and a great reduction in aggressiveness about a week into the treatments. Complete resolution was observed in mice that had more weekly doses of NS. Some animals did not show any of the aforementioned symptoms.

Morphological Findings

Most of the animals developed exophthalmos and pedal swelling approximately 24 hours following intraperitoneal administration of TMT. The exophthalmos resolved within 14 days of TMT administration while the pedal edema was present in all groups that had TMT till the end of the research. Varying weight changes were observed amongst the groups. Group A animals (3mg/kg TMT single dose in 48 hours followed by euthanasia) showed a marginal weight loss of about 0.5-1g before euthanasia. Weekly weight-record of animals revealed nearly a constancy in Group B (3mg/kg of TMT followed by 28ml/kg Nigella sativa after 48 hours and sacrificed after 1 week). A progressive weight gain of about 1-2g was observed in Groups C and D (Single dose TMT followed by a weekly dose Nigella sativa for 2 and 3 weeks respectively). Group E (3mg/kg TMT single dose) experienced greater weight loss of about 1.5g in the first week after TMT administration, followed by a fairly constant weight in the subsequent weeks. Groups F and G, which served as the control for the experiment, exhibited weight gain. The weight changes are shown in table 2.

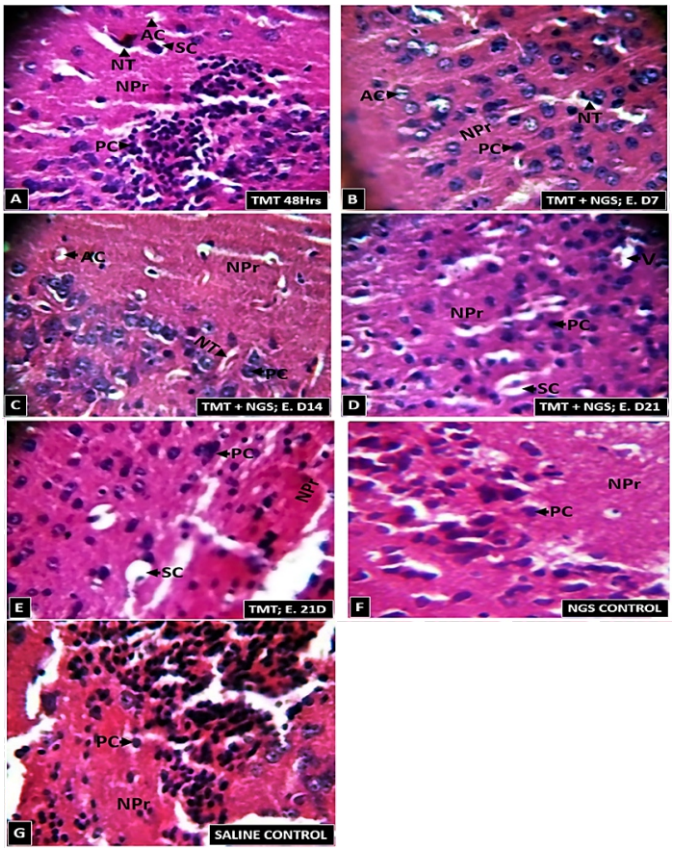

Figure 1: Representative Photomicrographs of Haematoxylin and Eosin (H&E) Stained Hippocampal region (X400) of groups (A) Pyramidal Neurons of the Ammon's horn appearing shrunken and other neuronal bodies' shows severe hyperchromic fragmentedchromatin, (B) shows the presence of Neuronal bodies with severe Hyperchromic Granulated Chromatins. (C)showing Subiculum section displaying Neuronal bodies with moderately Hyperchromic and Granulated Chromatins. (D)shows Ammon's horn section displaying a few darkly stained Neuronal bodies and shrunken Pyramidal Neurons. (E) showing moderately normal Subiculum section displaying very few Neuronal bodies with Hyperchromic and Granulated Chromatins. (F)shows the Subiculum section displaying normal Neuronal bodies, the Pyramidal Neurons do not shrink and the cells take up stains normally. (G) shows Ammon's horn and Dentate gyrus section displaying normal Neuronal bodies, the Pyramidal Neurons not shrunken and the cells take up stains normally.

Table 1: Drug Administration

Group	Treatment (Route)	Dose (weekly)	Duration
A	TMT (Subcutaneously)	3 mg/kg	48hrs
B	TMT (Subcutaneously) + NS (oral)	3 mg/kg (single dose) 28 ml/kg	7 days
C	TMT (Subcutaneously) + NS (oral)	3 mg/kg (single dose) 28 ml/kg	14 days
D	TMT (Subcutaneously) + NS	3 mg/kg (single dose) 28 ml/kg	21 days
E	TMT	3mg/kg	21 days
F	NS	28ml/kg	21 days
G	Normal saline	28ml/kg	21 days

Relative brain weight (RBW)

The Relative Brain Weight (RBW = Brain weight/ total body weight× 100) of the animals varied slightly across the groups. Animals treated with TMT displayed significantly higher RBW when compared to other groups. Those co-treated with NS had similar but slightly lower RBW than those treated with TMT alone (Table 2).

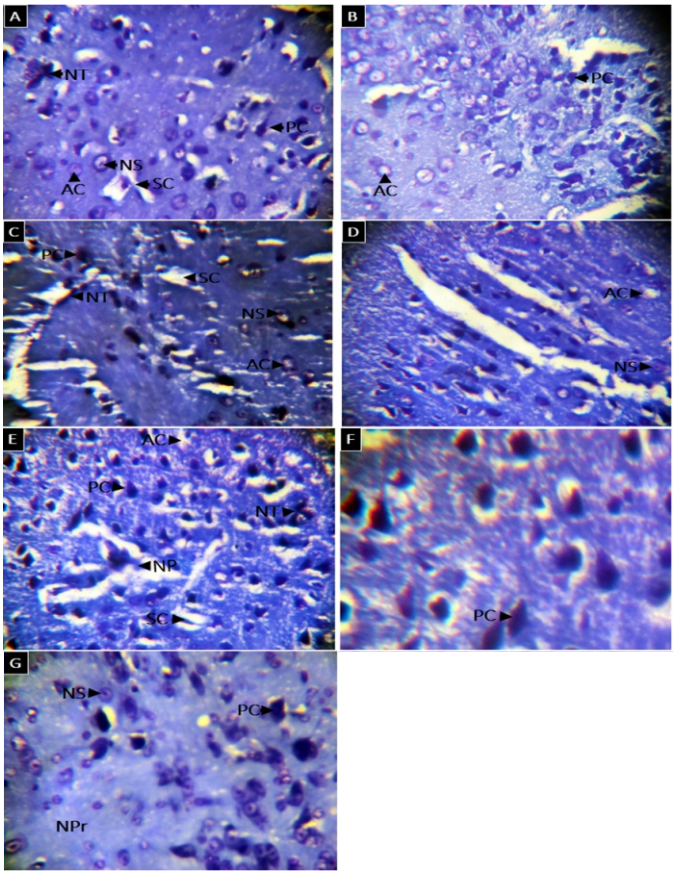

Figure 2: Representative Photomicrographs of LFB Stained Hippocampal Region (X400). Groups (A) show the presence of few Nissl Substances (NS) and massive Apoptotic Cells (AC).(B)(C) shows an absence of Nissl Substances (NS). Apoptotic Cells (AP) were observed. (D)shows few Apoptotic Cells (AP) and Neuritic Plaque (NP) with numerous Nissl Substances (NS). (E) shows numerous Apoptotic Cells (AP) and Neuritic Plaque (NP) with few Nissl Substances (NS) whiles (F), and (G) shows the presence of numerous Nissl Substances (NS), normal morphology of Pyramidal Cells (PC) with no Apoptotic Cells (AC).

Histological Observations

Animals exposed to NS only and saline control showed a high population of pyramidal cells (figure 1) and nissl substances with few (figure 2) or no apoptotic cells (figure 3) in slide sections. Mice treated with TMT, displayed degenerative changes in the histological architecture of the hippocampus as evidenced by the presence of neurofibrillary tangles, neuritic plaques, and apoptotic cells when compared to mice treated with Nigella sativa (NS) after TMT exposure. The degree of apoptosis was observed to be highest in animals that were euthanized on day 7 after treatment with a single dose of TMT and NS compared to animals in other groups. This is further described in figures1-3.

DISCUSSION

Trimethyltin is neurotoxic

Organotin compounds such as trimethyltin chloride (TMT) have been shown to have strong neurotoxic properties that cause selective neuronal death, in specific regions of the brain such as the hippocampus (16, 17). They have been widely used in the industrial and agricultural allied sectors as insecticides and pesticides (18, 19) and equally as a constituent of plastics and fungicide respectively.

TMT, a neurotoxic compound induces morphological changes in mice brain. The neurotoxicant properties have beenidentified since the 19th century (20) and this often made TMT to be used in an experiment that involves the inducement of neurotoxicity in experimental neurobiology.The result from the present study shows that mice exposed to TMT express symptoms highly suggestive of a multisystem injury with more noticeable changes in the central nervous system. Observations include neuropsychiatric behaviors such as aggressiveness, tremors, and increased relative brain weight. These are indicative of brain inflammation and edema resulting from acute TMT poisoning (18). A release of excitatory amino acids from astrocytic edema has been suggested (21), this explains the tremors and aggressive behaviors observed in the animals.

The increase in the relative brain weight of the animals may be contributed by the overall decline in body weight. This may be explained by the loss of coordination and poor feeding observed in the animals. Yousef et al., 2010 reported in their study, similar findings of weight loss following administration of TMT (22). The notable TMT syndrome is often used to describe the neuropsychiatric behaviors of animals exposed to TMT, such as

Table 2. Quantitative Body Weight Changes in Mice Administered with Trimethyltin and *Nigella sativa* Seed Oil

Groups	Treatment	Initial b.w (g)	After 48hrs (g)	7 Days (g)	14 Days (g)	21 Days (g)
A	TMT 48hrs	26.60±0.371	24.70±0.448			
B	TMT + NS D7	25.90±0.433	-	25.70±0.517 *		
C	TMT + NS D14	26.10±0.586	-	24.70±0.396 *	27.80±0.327	
D	TMT + NS D21	26.00±0.537	-	24.26±0.512 *	25.40±0.371 *	28.90±0.277
E	TMT D21	26.10±0.458	-	24.30±0.448 *	25.10±0.379 a*	25.90±0.314 *
F	NS	26.10±0.379	-	27.10±0.314	24.20±0.442 *	24.60±0.476 *
G	Saline	26.30±0.300	26.40±0.3 80	27.10±0.348	28.30±0.442	30.20±0.467

Data were mean of ten determinations ± standard errors of mean. Values carrying superscripts * indicates significant difference between the group and group G ($p<0.05$).
TMT 48 hrs - Group administered Trimethyltin (TMT) and observed for 48hours;
TMT + NS D7- Group administered single dose of TMT followed by Nigella sativa seed oil (NS) and observed for 7 days before euthanization.
TMT + NS D14- Group administered single dose of TMT followed by Nigella sativa seed oil (NS) once every 7 days for 14 days before euthanization.
TMT + NS D21- Group administered single dose of TMT followed by Nigella sativa seed oil (NS) once every 7 days for 21 days before euthanization.
TMT D21- Group administered Trimethyltin (TMT) and observed for 21 days;
NS- Group administered Nigella sativa seed oil (NS) once every 7 days for 21 days before euthanization.
Saline- Group administered saline once every 7 days for 21 days before euthanization.

transient gait abnormalities, tremors, aggressiveness. Mice exposed to TMT demonstrated hyperactivity and the behavioralsigns observed in these experimental animals after 48 hours of administration of TMT.

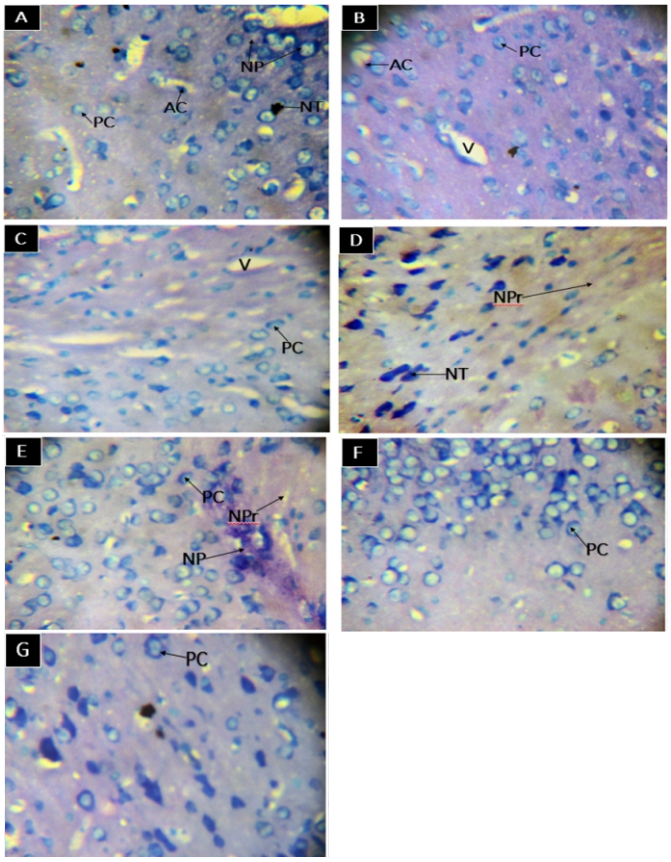

Figure 3: Representative photomicrographs of Giemsa stained Hippocampal region (X400) showing the presence of Apoptotic Cells (AC), Vacuoles (V), and Pyramidal Cells (PC). (A) shows the presence of a few Pyramidal Cells (PC), Apoptotic Cells (AP), Neurofibritic Tangle (NT), and Neuronal Plague (NP). (B) shows the presence of fewer Apoptotic Cells (AP) with Pyramidal Cells (PC) and Vacuoles (V). (C) shows fewer Vacuoles (V) and more Pyramidal Cells (PC). (D) and(E) Given stat dose TMT, shows the presence of Neuronal Projection (NPr) while (F) and (G) Saline single-dose/week, has normal Pyramidal Cells (PC) distribution.

TMT-induced injuries are dose and time-dependent

Earlier researchers found a dose-related decrease in brain weight across different age groups (23). In this study as well, the observed signs resolved in animals that were left for a longer period (21days) suggesting that the damages caused by TMT were temporary (24). This can be explained by hippocampal neurogenesis that occurs in the adult brain (Altman, 1963). Research has suggested that new neurons are continuously added to the dentate gyrus as well as the subventricular zone well into the postnatal and adult period in rats and mice (25). In contrast, Rose and Aldrigein 1968 reported that the effect of TMT is sustained for a longer period due to the high affinity of rat hemoglobin for TMT thereby acting as a reservoir for the slow and continuous release of the toxic agent into the plasma and from which it enters the brain (26).

TMT induces notable histological changes in the hippocampus

Histological changes in the cytoarchitecture of the brain observable were thought to be due to the ability of TMT to cause brain inflammation and subsequent brain edema which will result from neuronal injuries. The histological tissue sections indicated severe degenerative changes such as shrunken cytoplasm and extensively dark pyknotic nuclei in neurons of the hippocampi tissues of animals treated with TMT alone. Histological findings also revealed neuronal degeneration evidenced by the presence of neurofibrillary tangles, apoptotic cells, and neuritic plaques as early as 48hours following a single dose of intraperitoneal TMT. Shrunken pyramidal cells and neuronal bodies as well as hyperchromasia and fragmentation of cells were also observed. This finding is similar to the neurodegenerative changes observed by earlier researchers (27-29). It is therefore suggested that TMT exerts its toxic effects majorly on pyramidal neurons (30, 31). Some other researchers however did not find any degenerative changes in the cells (32). This outcome may explain the variation in the behavioral and histomorphological signs observed. The presence of some protective biological factors in some of the animals may have a shielding effect against neurotoxins such as TMT while the others are more susceptible. Toggers and his colleagues used molecular coupling techniques to isolate complementary DNA which was specifically localized in TMT-sensitive cells (33).

Ishida and his colleagues showed the functional significance of hippocampal neurodegeneration by TMT in his work on TMT syndrome (34). The whole of the hippocampus appears to be susceptible to these neurodegenerative changes as was observed in the slide sections from the Ammon's horn as well as the dentate gyrus. This conforms with previous studies where TMT administration caused selective neuronal death involving either the granular neurons of the dentate gyrus or the pyramidal cells of the Cornu Ammonis.

Table 3. Relative Brain Weight of Mice Administered with Trimethyltin and *Nigella sativa* Seed Oil

Groups	Treatment	Relative Brain Weight (g)
A	TMT 48hrs	$0.0123 \pm 0.000213^{*\infty}$
B	TMT + NS D7	$0.0119 \pm 0.000277^{*\infty\mu}$
C	TMT + D14	$0.0121 \pm 0.000180^{*\infty\mu}$
D	TMT + NS D21	$0.0118 \pm 0.000200^{*\infty\mu}$
E	TMT D21	$0.0125 \pm 0.000269^{*\infty}$
F	NS	0.0099 ± 0.000163
G	Saline	0.0104 ± 0.000136

Data were mean of ten determinations ± standard errors of mean. Values carrying superscripts * indicates significant difference between the group and group G ($p<0.05$), $^{\infty}$ indicates difference between the group and group F and $^{\mu}$ indicates difference between the group and group E.

TMT 48 hrs - Group administered Trimethyltin (TMT) and observed for 48hours;

TMT + NS D7- Group administered single dose of TMT followed by *Nigella sativa* seed oil (NS) and observed for 7 days before euthanization.

TMT + NS D14- Group administered single dose of TMT followed by *Nigella sativa* seed oil (NS) once every 7 days for 14 days before euthanization.

TMT + NS D21- Group administered single dose of TMT followed by *Nigella sativa* seed oil (NS) once every 7 days for 21 days before euthanization.

TMT D21- Group administered Trimethyltin (TMT) and observed for 21 days;

NS- Group administered *Nigella sativa* seed oil (NS) once every 7 days for 21 days before euthanization.

Saline- Group administered saline once every 7 days for 21 days before euthanization.

TMT acts via excitototxicity

Several mechanisms have been proposed for the mechanism of TMT-induced neurotoxicity. None has been conclusive; however, experimental evidence indicates that TMT-induced neurodegeneration is a complex event involving different pathogenetic mechanisms, probably acting differently in animal and cell models, which include neuroinflammation, intracellular calcium overload, and oxidative stress. A prior study proposed that the toxic effects of TMT were due to the disturbance of brain glutamate and GABAergic metabolism (35, 36). The study

explained a disruption of the neuronal glutamate metabolism, and this may account for the motor abnormalities observed in the animals. Woodruff and Baisden in 1990 provided evidence for the involvement of cholinergic mechanisms in TMT- induced cognitive deficits via an enhanced activity of cholinergic marker-acetylcholinesterase (37). TMT exposure was also observed to reduce the concentration of GABA within the hippocampus (38, 39) or loss of GABAergic receptors (40), thereby reducing inhibition within the dentate gyrus. This contributes to excitotoxicity.

Neuroprotective effects of *Nigella sativa*

Animals treated with NS did not exhibit any behavioral or neuropathological signs. The histological findings were also in conformity with this. Cells exhibited normal neuronal bodies and no toxic effect was observed. The pyramidal neurons were not shrunken and they took up dyes normally when compared with animals in the saline control group. There was no hyperchromasia as observed in the TMT- treated groups. This conforms with earlier studies in mice and rats which show that NS has a very low toxicity level as evidenced by its high LD50 values, key hepatic enzyme stability, and organ integrity. This suggests a wide safety margin for therapeutic doses (41) (42, 43). As in other herbal preparations, safety is among the most important factors to be considered before use.

NS has also been found to have immunomodulating properties as it was observed that organisms given NS exhibited reduced immunoreactivity to toxins. According to a study, caspase-3, (a main effector caspase strongly implicated in neuronal apoptosis) immunopositivity was increased in degenerating neurons of the frontal cortex tissues following formaldehyde exposure. Treatment with NS markedly reduced the expression of caspase-3 in degenerating neurons after exposure to formaldehyde (44) and other toxins (45, 46).

In this study, *Nigella sativa* was able to ameliorate the neurotoxic effects of TMT as evidenced by the fewer hyperchromatic neuronal bodies and fewer shrunken pyramidal neurons in the hippocampal slide sections obtained from animals that had NS following TMT administration. Similarly in the work of Kamasak (2021) and Butt (2018), NS oil was found to significantly reduce toxicity and oxidative stress in the rat brain regions via a free radical scavenging mechanism (47, 48). Some researchers also revealed that the ameliorative and antiepileptic properties of NS were able to alleviate ciprofloxacin-induced neurotoxicity via an imbalance between the excitatory and the inhibitory amino acids reflecting its potent antiepileptic activity (49). Also, the antioxidant properties of thymoquinone, the major constituent of NS oil have been demonstrated to prevent oxidative injury during anischemia-reperfusion injury in different organs in the rat (50, 51) These properties of NS explain its antidotal, ameliorative, and antioxidant effects following exposure to many toxins including TMT.

CONCLUSION

Nigella sativa, an ancient and widely used herbal medicine, ameliorated the neurotoxic effects of trimethyltin chloride in mice hippocampi via its probable free radical scavenging properties. Further studies are needed to achieve a convincing functional validation of the specific role Nigella sativa plays in neuroprotection. With more extended research, NS promises a safe and effective regimen in the management and prevention of neuropsychiatric conditions.

In vitro and *in vivo* studies of the neuroprotective effects of Nigella sativa, focusing on the hypotheses regarding the mechanisms leading to early hippocampal neurogenesis and hence amelioration of neuronal injury induced by the toxin is highly suggested. This will help in determining the neuropsychiatric conditions that Nigella sativa will have a meaningful contribution.

Conflict of interest

Authors declare that no conflict of interest could be perceived as prejudicing the impartiality of the research reported.

Authors' contributions

The research protocol was designed by M.Y.A., with assistance from M.S.A. Benchwork, and data collection was done by M.Y.A. Analysis and interpretation of data were done by M.Y.A and A.I. Manuscript was drafted and edited by M.Y.A., A.I., and M.S.A. All authors read and approved the submission of the manuscript.

REFERENCES

1. Bjørklund G, Meguid NA, El-Bana MA, Tinkov AA, Saad K, Dadar M, et al. Oxidative stress in autism spectrum disorder. Molecular neurobiology. 2020;57(5):2314-32.
2. Nandi A, Yan L-J, Jana CK, Das N. Role of catalase in oxidative stress-and age-associated degenerative diseases. Oxidative medicine and cellular longevity. 2019;2019.
3. Al Shahrani M, Heales S, Hargreaves I, Orford M. Oxidative stress: mechanistic insights into inherited mitochondrial disorders and Parkinson's disease. Journal of Clinical Medicine. 2017;6(11):100.
4. Daniele SG, Trummer G, Hossmann KA, Vrselja Z, Benk C, Gobeske KT, et al. Brain vulnerability and viability after ischaemia. Nature Reviews Neuroscience. 2021:1-20.
5. Sharma GN, Gupta G, Sharma P. A comprehensive review of free radicals, antioxidants, and their relationship with human ailments. Critical Reviews™ in Eukaryotic Gene Expression. 2018;28(2).
6. Banerjee A, Das D, Paul R, Roy S, Bhattacharjee A, Prasad SK, et al. Altered composition of high-lipid diet may generate reactive oxygen species by disturbing the balance of antioxidant and free radicals. Journal of basic and clinical physiology and pharmacology. 2020;31(3).
7. Hou J, Xue J, Wang Z, Li W. Ginsenoside Rg3 and Rh2 protect trimethyltin-induced neurotoxicity via prevention on neuronal apoptosis and neuroinflammation. Phytotherapy Research. 2018;32(12):2531-40.
8. Ghezelbash M, Edalatmanesh MA, Dehghan S. Histopathological and Stereological Study of the Effects of Gallic Acid Administration on Hippocampal Neuronal Density after Trimethyltin Toxication. Report of Health Care. 2018;4(2):22-7.
9. Cremer JE. Possible mechanisms for the selective neurotoxicity. Biological effects of organolead compounds: CRC Press; 2020. p. 207-18.
10. McIntosh LJ. An examination of the differential susceptibility of neurons to trimethyltin toxicity: The Johns Hopkins University; 1993.
11. Corvino V, Marchese E, Michetti F, Geloso MC. Neuroprotective strategies in hippocampal neurodegeneration induced by the neurotoxicant trimethyltin. Neurochemical research. 2013;38(2):240-53.
12. Afshari AR, Fanoudi S, Rajabian A, Sadeghnia HR, Mollazadeh H, Hosseini A. Potential protective roles of phytochemicals on glutamate-induced neurotoxicity: A review. Iran J Basic Med Sci. 2020;23(9):1113-23.
13. Liang L, Yang T, Easa A, Zzaman W. Effect of conventional and superheated steam roasting on the total phenolic content, total flavonoid content and DPPH radical scavenging activities of black cumin seeds. Pertanika Journal of Tropical Agricultural Science. 2018;41(2).
14. Eid AM, Jaradat NA, Elmarzugi NA, Alkowni R, Hussen F, Ayyash LA, et al. Anti-microbial and free radical scavenging activities of nigella sativa colloidal-emulgel. Letters in Drug Design & Discovery. 2019;16(4):408-16.
15. Ali R. Special Stains: Important & Application.
16. Kaur S, Sharma N, Nehru B. Anti-inflammatory effects of Ginkgo biloba extract against trimethyltin-induced hippocampal neuronal injury. Inflammopharmacology. 2018;26(1):87-104.
17. Mitrović N, Dragić M, Zarić M, Nedeljković N, Grković I. Flaxseed Oil Attenuates Trimethyltin-induced Neurodegeneration via Down-regulation of Inflammatory Activity of Astrocytes. 2021.
18. Du Y. Acute Trimethyltin Poisoning Caused by Exposure to Polyvinyl Chloride Production: 8 Cases. The American Journal of the Medical Sciences. 2021.
19. Boyer IJ. Toxicity of dibutyltin, tributyltin and other organotin compounds to humans and to experimental animals. Toxicology. 1989;55(3):253-98.
20. Reiter L, Ruppert P. Behavioral toxicity of trialkyltin compounds: a review. Neurotoxicology. 1984;5(2):177-86.
21. Kimelberg HK. Current concepts of brain edema: review of laboratory investigations. Journal of neurosurgery. 1995;83(6):1051-9.

22. Yousef MI, Kamel KI, Hassan MS, El-Morsy AM. Protective role of propolis against reproductive toxicity of triphenyltin in male rabbits. Food and Chemical Toxicology. 2010;48(7):1846-52.
23. Miller DB, O'Callaghan JP. Biochemical, functional and morphological indicators of neurotoxicity: effects of acute administration of trimethyltin to the developing rat. Journal of Pharmacology and Experimental Therapeutics. 1984;231(3):744-51.
24. MacPhail R, O'Callaghan J, Cohn J. Acquisition, steady-state performance, and the effects of trimethyltin on the operant behavior and hippocampal GFAP of Long–Evans and Fischer 344 rats. Neurotoxicology and teratology. 2003;25(4):481-90.
25. Tuncdemir SN, Lacefield CO, Hen R. Contributions of adult neurogenesis to dentate gyrus network activity and computations. Behavioural brain research. 2019;374:112112.
26. Rose M, Aldridge W. The interaction of triethyltin with components of animal tissues. Biochemical Journal. 1968;106(4):821-8.
27. Lee S, Yang M, Kim J, Kang S, Kim J, Kim J-C, et al. Trimethyltin-induced hippocampal neurodegeneration: A mechanism-based review. Brain research bulletin. 2016;125:187-99.
28. Sadoughi D. The effect of crocin on apoptotic, inflammatory, BDNF, Pt, and Aβ40 indicators and neuronal density of CA1, CA2, and CA3 regions of hippocampus in the model of Alzheimer suffering rats induced with trimethyltin chloride. Comparative Clinical Pathology. 2019;28(5):1403-13.
29. Kwon OY, Lee SH. Ishige okamurae Suppresses Trimethyltin-Induced Neurodegeneration and Glutamate-Mediated Excitotoxicity by Regulating MAPKs/Nrf2/HO-1 Antioxidant Pathways. Antioxidants. 2021;10(3):440.
30. Corvino V, Marchese E, Giannetti S, Lattanzi W, Bonvissuto D, Biamonte F, et al. The neuroprotective and neurogenic effects of neuropeptide Y administration in an animal model of hippocampal neurodegeneration and temporal lobe epilepsy induced by trimethyltin. Journal of neurochemistry. 2012;122(2):415-26.
31. Srivastava A, Liachenko S, Sarkar S, Paule M, Sadovova N, Hanig JP. Global Neurotoxicity: Quantitative Analysis of Rat Brain Toxicity Following Exposure to Trimethyltin. International Journal of Toxicology. 2021:10915818211009193.
32. O'Callaghan JP, Miller DB. Neuron-specific phosphoproteins as biochemical indicators of neurotoxicity: effects of acute administration of trimethyltin to the adult rat. Journal of Pharmacology and Experimental Therapeutics. 1984;231(3):736-43.
33. Toggas SM, Krady JK, Billingsley ML. Molecular neurotoxicology of trimethyltin: identification of stannin, a novel protein expressed in trimethyltin-sensitive cells. Molecular pharmacology. 1992;42(1):44-56.
34. Ishida N, Akaike M, Tsutsumi S, Kanai H, Masui A, Sadamatsu M, et al. Trimethyltin syndrome as a hippocampal degeneration model: temporal changes and neurochemical features of seizure susceptibility and learning impairment. Neuroscience. 1997;81(4):1183-91.
35. Chang L, Dyer R. A time-course study of trimethyltin induced neuropathology in rats. Neurobehavioral Toxicology and Teratology. 1983;5(4):443-59.
36. Chang LW, Dyer RS. Early effects of trimethyltin on the dentate gyrus basket cells: a morphological study. Journal of Toxicology and Environmental Health, Part A Current Issues. 1985;16(3-4):641-53.
37. Woodruff ML, Baisden RH. Exposure to trimethyltin significantly enhances acetylcholinesterase staining in the rat dentate gyrus. Neurotoxicology and teratology. 1990;12(1):33-9.
38. Mailman RB, Krigman MR, Frye GD, Hanin I. Effects of postnatal trimethyltin or triethyltin treatment on CNS catecholamine, GABA, and acetylcholine systems in the rat. Journal of neurochemistry. 1983;40(5):1423-9.
39. Earley B, Burke M, Leonard BE. Behavioural, biochemical and histological effects of trimethyltin (TMT) induced brain damage in the rat. Neurochemistry international. 1992;21(3):351-66.
40. Nishimura T, Schwarzer C, Furtinger S, Imai H, Kato N, Sperk G. Changes in the GABA-ergic system induced by trimethyltin application in the rat. Molecular brain research. 2001;97(1):1-6.
41. Islam M, Guha B, Hosen S, Riaz T, Shahadat S, Da Rocha Sousa L, et al. Nigellalogy: a review on Nigella sativa. MOJ Bioequiv Availab. 2017;3(6):00056.
42. Khan S, Ali M, Albratty MM, Najmi AY, Azeem U, Khan SA, et al. Nigella sativa: From chemistry to medicine. Black Seeds (Nigella Sativa): Elsevier; 2022. p. 29-62.
43. Mashayekhi-Sardoo H, Rezaee R, Karimi G. Nigella sativa (black seed) safety: an overview. Asian Biomedicine. 2020;14(4):127-37.
44. Mohamad AE-RE-S, Essa TM, Ata HS. Nigella sativa protects against formaldehyde-induced neurotoxicity in the rat frontal cortex. Anatomy. 2015;9(3).
45. Tavakkoli A, Ahmadi A, Razavi BM, Hosseinzadeh H. Black seed (Nigella sativa) and its constituent thymoquinone as an antidote or a protective agent against natural or chemical toxicities. Iranian journal of pharmaceutical research: IJPR. 2017;16(Suppl):2.
46. Kanter M. Protective effects of thymoquinone on the neuronal injury in frontal cortex after chronic toluene exposure. Journal of molecular histology. 2011;42(1):39-46.
47. Butt UJ, Shah SAA, Ahmed T, Zahid S. Protective effects of Nigella sativa L. seed extract on lead induced neurotoxicity during development and early life in mouse models. Toxicology research. 2018;7(1):32-40.
48. Kamasak K, Basarslan K, Dagli AT, Ogden M, Alabalik U, Ekinci A, et al. Effects of nimodipine and Nigella sativa on oxidative stress and apoptosis in serum and brain tissue of rats with experimental head trauma. Turkish neurosurgery. 2021;31(1):8-17.
49. Abdel-Rahman M, Arafa NM, El-khadragy MF, Kassab RB. The neuroprotective role of Nigella sativa extract on ciprofloxacin and pentylenetetrazole treated rats. African Journal of Pharmacy and Pharmacology. 2013;7(24):1660-70.
50. Atasever M, Bakacak Z. Nigella Sativa oil protects the rat ovary from oxidative injury due to ischemia-reperfusion. Medical science monitor: international medical journal of experimental and clinical research. 2017;23:5027.
51. Forouzanfar F, Hosseinzadeh H. Protective Role of Nigella sativa and Thymoquinone in Oxidative Stress: A Review. Nuts and Seeds in Health and Disease Prevention. 2020:127-46.