Research Article

Olalere Shittu*, Olufunke Adenike Opeyemi, Muritala Kayode Salawu, Abeeb Adio Ashiru, Shadrach Ayodeji Medaiyese, Nnaemeka Asogwa, Kehinde Funmilola Sheba, Rafiu Adebisi Kadir, Olusola Isaac Aremu and Olusola Ajibaye

Alterations in histological, biochemical and hematological parameters in *Plasmodium berghei* NK-65 infected balb/c mice treated with *Bridelia ferruginea* stem bark extract

https://doi.org/10.1515/jcim-2018-0219
Received November 23, 2018; accepted February 19, 2020; published online May 19, 2020

Abstract

Background: Recent ethnomedicinal studies on *Bridelia ferruginea* Benth (family Phyllanthaceae) as an antiplasmodial remedy have established its potency as a strong prophylactic and chemosuppressive agent. Human consumption of medicinal herbs without adequate evaluation of its efficacy and safety can result in grave physiological and pathological consequences. Therefore, this study assessed the antiplasmodial bioactivity, biochemical, hematological, histopathological and toxicity profile of the ethanolic stem bark extract of *B. ferruginea* in mice.
Methods: Ethanolic stem bark extract of *B. ferruginea* (200, 400 and 800 mg/kg) were orally administered to *Plasmodium berghei*-infected mice in models and were subsequently observed for mortality, behavioral changes and signs of toxicity. Acute evaluation was experimented at 1,000 mg/kg for 28 days. Occult blood obtained from the euthanized mice were subjected to biochemical and hematological assays. A comprehensive assessment of the histology of the liver and kidney was also ascertained. The median lethal dose (LD_{50}) was determined and extrapolated using the regression equation obtained from the plot of the probits of mortalities (y) and the log of doses ($\log_{10}C$).
Results: Different concentrations of the phytochemical secondary metabolites were revealed. Antiplasmodial bioactivity was established at the 200, 400 and 800 mg/kg of the herbal extract with a dearth in parasitemia at different days post-treatment. The 800 mg/kg group responded by exhibiting a dose-dependent decrease in parasitemia comparable with the chloroquine bi-phosphate group. Significant alterations in the histology of the liver and kidney of the 1,000 mg/kg group was documented. There was a reduction in the titers of LDH, ALT, AST, and urea in the treated group when compared with the control ($p < 0.05$). Antioxidant profiles were also highly significant with elevation in SOD, GPx, and CAT, but a reduction in MDA. LD_{50} was established at 424 mg/kg.
Conclusion: *B. ferruginea* Benth (family Phyllanthaceae) is a potent antiplasmodial, antioxidant, regenerative and ameliorative herbal remedy if administered in controlled dosage.

Keywords: antioxidants; *Bridelia ferruginea*; median lethal dose; *Plasmodium berghei*; toxicity.

***Corresponding author: Olalere Shittu**, Parasitology Unit, Department of Zoology, University of Ilorin, Ilorin, Nigeria, Phone: +234 8033819041, +234 8084717654, E-mail: eternity403@yahoo.com. https://orcid.org/0000-0003-4656-6109
Olufunke Adenike Opeyemi, Abeeb Adio Ashiru, Shadrach Ayodeji Medaiyese and Kehinde Funmilola Sheba: Parasitology Unit, Department of Zoology, University of Ilorin, Ilorin, Nigeria
Muritala Kayode Salawu: Department of Pharmacognosy and Drug Development, University of Ilorin, Ilorin, Nigeria
Nnaemeka Asogwa: Department of Biochemistry, University of Ilorin, Ilorin, Nigeria
Rafiu Adebisi Kadir: Department of Veterinary Medicine, Faculty of Veterinary Medicine, University of Ilorin, Ilorin, Nigeria
Olusola Isaac Aremu: Department of Pharmaceutics and Industrial Pharmacy, Faculty of Pharmaceutical Sciences, University of Ilorin, Ilorin, Nigeria
Olusola Ajibaye: Biochemistry Division, Nigerian Institute of Medical Research, Lagos, Nigeria

Introduction

Plants are important components of mankind's healthcare system, either directly or indirectly. The use of medicinal plant extracts have long been in existence, as they habour an inexhaustible source of biologically active

chemicals which singly or in combination inhibit greatly the life processes of disease causing microorganisms [1]. A high proportion of people in both developed and developing countries use medicinal plants for therapeutic purposes [2]. *Bridelia ferruginea* Benth (Phyllantaceae) is a woody shrub commonly found in the Savannah region of Africa, growing up to 15 m high and 1.5 m wide with branches occurring at the lower region [3, 4]. In Nigeria, it is variously called Kizni (Hausa); Marehi (Fulani); Iralodan (Yoruba); Ola (Igbo); and Kensange abia (Boki) [5]. The presence of phytochemicals such as alkaloids, tannins, saponins, quinones, polyterpenes, polyphenols, flavonoids, phlobatanins, steroids, and cardiac glycosides, supports its traditional use in the treatment of various ailments [6–8]. In Africa, the leaves and bark extracts are notable for their use as purgative and vermifuge while the root bark is efficacious against intestinal, bladder and skin diseases [9–11]. The stem bark extract has been reported to demonstrate anti -inflammatory, antipyretic and analgesic activities *in vivo* and *in vitro*, coupled with significant anti-plasmodial activity against *Plasmodium berghei* in mice [12, 13]. Its ability to protect the body against damage caused by free radicals regularly produced during oxidative stress validates its antioxidant activities [14]. Several works have established its anti-trypanosoma activities [15, 16], as well as its ability to prevent metabolic syndrome in type 2 diabetes [17], however, in recent times, *B. ferruginea* has gained prominence due to its anti-plasmodial potentials [13] . The increased reliance on medicinal plants is largely due to the assumption that they are easily accessible, safe and relatively free of side effects [18, 19]. However, lack of standardized chemical characterization, dosage regimen, and substantial toxicity profile to ascertain their safety are some of the limitations on their general acceptability [20]. Assessment of hematological parameters is often employed as useful indices to determine the toxicity profile and blood related functions of plant extracts [21]. Furthermore, analysis of serum enzyme activity serves as biomarkers for appraising the effect and nature of pathological damage to tissues is an invaluable tool in clinical diagnosis [22]. So far, few *in vivo* hematological studies on *B. ferruginea* stem bark extract have been conducted, with findings suggestive of either a deleterious or ameliorative potential of the extract on blood parameters [23–25]. A decrease in mean hemoglobin (Hb) concentration and packed cell volume (PCV) with a resultant dose-dependent increase in lymphocyte, neutrophil and eosinophil count was observed following a 2 week administration of aqueous stem bark extract in albino rats [25]. Also, a more recent study suggests a significant increase in the liver and serum levels of aspartate aminotransferase (AST) and alanine aminotransferase (ALT) [26]. Their presence in the serum is indicative of hepatocellular injury, organ dysfunction, inflammation or necrosis of the liver [27–29]. Awodele et al. [24], however, observed a significant decline in the activities of these transaminase enzymes and attributed it to the ability of *B. ferruginea* stem bark extract to stabilize the plasma membrane, hence, reducing vascular permeability; a finding earlier asserted by Olajide et al. [12] in an *in vitro* assessment of the effect of aqueous stem bark extract of *B. ferruginea* on human red blood cell (HRBC) membrane. In spite of its antioxidant activities [14], body of evidence revealed a significant reduction in antioxidant levels such as superoxide dismutase (SOD) and glutathione peroxidase (GTPx), with a resultant increase in malondialdehyde (MDA); an index of lipid peroxidation, due to an overwhelming generation of free radicals which suppresses the antioxidant system with effects culminating in oxidative damage of host cells [24, 30]. Very few studies have addressed the histological, biochemical and hematological alterations emanating from the use of *B. ferruginea* stem bark extract. This research, therefore, seeks to bridge the knowledge gap as well as establish the point toxicity that could result from excessive intake in *P. berghei* NK-65 infected balb/c mice.

Materials and methods

Plant collection

Fresh stem bark of *B. ferruginea* was obtained from the botanical garden of Department of Pharmacognosy, University of Ilorin between January and February 2018, during the Harmattan season. Identification and authentication was carried out by a taxonomist at the herbarium of the Department of Plant Biology, University of Ilorin.

Preparation of stem bark extract

B. ferruginea stem bark was cleaned, cut into pieces and air dried at room temperature for 14 days after which it was grinded into powder using a specialized grinding machine at the Department of Pharmacognosy and drug development, Faculty of Pharmaceutical sciences, University of Ilorin and stored as stock in air tight containers, after the methods of Mbah et al. [13]. 1,000 g was weighed with a top loader weighing balance and thereafter soaked in 2 L of 70% ethanol in an air-tight container for 72 h. The mixture was stirred intermittently using a wooden spatula. The filtrate was carefully decanted, filtered and subsequently subjected to a rotary evaporator. The concentrate obtained was placed in a water bath of 35 °C and left to dry overnight. Afterward, a crystalline solid of extract was obtained and stored.

Experimental animals

A total of 105 Swiss Albino adult mice of both sexes, weighing between 15 and 25 g were obtained from the Central Research Laboratory, University of Ilorin and maintained at the Zoology department animal house. The animals were housed in sawdust-bedded plastic cages with net roofing and allowed free access to standard diet and water ad libitum. They were allowed to acclimatize for 2 weeks before commencement of the experiment. The mice were strictly used in accordance with NIH Guide for the care and use of laboratory Animals [31].

Parasite strain and inoculation

A chloroquine-sensitive *P. berghei* NK-65 strain was obtained from the animal facility center, Department of Biochemistry, University of Ilorin. The donor mouse was screened to establish infection using thick blood smear. Thereafter, the parasites were kept alive by continuous intraperitoneal passage every 4 days. Subsequently, inoculums were prepared according to the methods of Akuodor et al. [32]. Briefly, 1 ml of blood was obtained from donor mouse and diluted with normal saline; such that 0.2 ml of the infected-blood contained 1×10^7 infected red blood cells. All mice were inoculated intraperitoneally with 0.2 ml of infected blood except for the control group. Parasites were allowed to incubate for 72 h after which Giemsa-stained thin smear was prepared from blood obtained from the caudal tip and viewed at ×100 magnification (oil immersion) of the light microscope. Estimation of parasitemia was according to the World Health Organization [33].

Animal groupings

Six animal groups (A-F) were established (each containing five mice) after being intraperitoneally inoculated. Groups A-E had three subgroups each, and were orally administered 0.2 ml stem bark extract of concentrations 200, 400, and 800 mg per kg body weight following the methods of Mbah et al. [13] after 72 h post inoculation. Treatment persisted at 12 h interval daily for 5 days consecutively. Group E (control group) had two sub-groups viz; the positive and negative control groups. The positive control group was treated daily with 4 mg/kg of chloroquine (Drugfield, Nigeria), while the negative control group was given an equivalent volume of 5%/kg of ethanol following the same regimen. On the seventh day, peripheral blood was excised from the tail of each mouse, thick and thin films were made and fixed with methanol (Fluka), stained with Giemsa (Sigma) for 30 min and parasitemia densities was examined microscopically by counting the parasitized red blood cells on at least 1,000 red blood cells. The mean survival time for each mice group were observed and recorded for 28 days.

Ethical clearance

The protocol for this study was submitted for ethical consideration, and approval was given by the University of Ilorin Ethical Review and Consideration Committee after agreeing to standard animal practice procedure as outlined in the America Veterinary Medicine Association (AVMA) Guidelines for the Euthanasia of Animals: 2013 Edition.

Acute toxicity test/LD_{50} determination

The biological safety of the ethanolic stem bark extract of *B. ferruginea* was ascertained using the method of Lorke [34]. Group F (acute toxicity group) was subdivided into treatment and control groups. The treatment group was administered 0.2 ml *B ferruginea* stem bark extract at 1,000 mg per kg body weight while the latter received an equal volume of 5% ethanol for 28 days.

Biochemical studies

Liver enzymes parameters were carried out after the methods of Awodele et al. [24]. A fully automated clinical chemistry analyzer (Hitachi 912, Boehringer Mannheim, Germany), was used to determine the concentration of aspartate aminotransferase (AST), alanine aminotransferase, lactate dehydrogenase (LDH), urea and creatinine.

Serum antioxidant enzymes and malondialdehyde (MDA) assays

The determination of serum superoxide dismutase titer was carried out after the methods of Misra and Fridovich [35]. The ability of SOD to inhibit the auto-oxidation of epinephrine at pH 10.2 enabled it determination and was monitored by the increase in absorbance at 480 nm. A single unit of SOD activity was defined as the amount of enzyme required for 50% inhibition of the oxidation of epinephrine to adrenochrome at 480 nm min^{-1} for 5 min. The role of superoxide anion in the autoxidation of epinephrine and a simple assay for superoxide dismutase Glutathione peroxidase level was measured as an indicator of serum thiol using 5,5′–dithiobis(2-nitrobenzoic acid) according to the spectrophotometric method reported by Ellman [36] . Briefly, 100 µl serum was mixed with 0.5 ml of 10 % TCA to precipitate the proteins. The sample was centrifuged at 15,000 rpm for 5 min. About 0.01 ml of the supernatant was diluted with 2 ml of phosphate buffer (pH 7.4) and then mixed with 0.5 ml of 5, 5′–dithiobis (2-nitrobenzoic acid) and 0.4 ml of double distilled water. The mixture was vortexed and absorbance was measured at 412 nm to detect the glutathione content.

Catalase (CAT) activity was determined following the method of Sinha [37]. Briefly, 0.1 ml of sample was mixed with 4.9 ml of distilled water containing 4 ml of 0.2 M H2 buffer in a 10 ml flat bottom flask. 1 ml of properly diluted enzyme preparation (test sample) was rapidly mixed with the reaction mixture by gentle swirling motion at room temperature. A 1 ml portion of the reaction mixture was withdrawn and blown into a test tube containing 2 ml of dichromate/acetic acid reagent at 60 s intervals for 3 min and heated for 10 min in a boiling water. Mixture was allowed to cool and the absorbance measured with a spectrophotometer at 570 nm.

Plasma MDA is produced during lipid peroxidation. It is usually measured as thiobarbituric acid reactive substances (TBARS) or lipid peroxides. This assay was carried out after the methods of Adisa and Sulaimon [38]. A 100 µL of serum was mixed with 900 µL of 0.9 % saline solution, 2 ml of freshly prepared thiobarbituric acid (TBA) reagent and 30 µL of 50 mM butylated hydroxyl toluene (BHT). The mixture was allowed to incubate at 60 °C for 15 min. The resulting sample was kept in ice for another 5 min and then the samples were centrifuged at 5,000 rpm for 10 min. The absorbance of the supernatant was measured spectrophotometrically at 535 nm using 1, 1, 3, 3-tetraethoxy-propane as standard.

Hematological assays

Blood parameters such as Red Blood Cell (RBC) count, Hemoglobin (Hb), Mean CellVolume (MCV), Mean Corpuscular Hemoglobin (MCH), Pack Cell Volume (PCV), White Blood Cell (WBC) count, Neutrophil, Lymphocyte, Granulocyte, and Platelet counts were determined using standard methods and a fully automated hematology analyzer (pentra-XL 80, Horiba ABX, USA).

Histopathological sectioning

All animals were euthanized and their liver and kidney were removed and processed immediately for histological preparations. Between 3 and 5 μm thin sections of the liver and kidney of the control and extract treated mice were made on glass slides and stained with Hematoxylin and Eosin solution. Photomicrographs of the tissues were taken and studied for possible significant alterations in the architecture of the tissues when compared with the control.

Statistical analysis

All statistical analysis were performed with the use of Instat statistical package (Graph Pad Software Inc., USA). The results obtained were expressed as mean ± standard error of the mean (SEM). Differences between the groups were determined using one-way analysis of variance (ANOVA), followed by Dunnett's multiple comparison tests to evaluate significant differences between the groups. The P-value level of significance was assigned at $P < 0.05$. The median lethal dose (LD_{50}) was determined using the regression equation obtained from the plot of the probits of mortalities (y) and the log of doses ($\log_{10}C$).

Results

The phytochemical constituents of stem bark extract of *B. ferruginea* revealed the presence of a number of secondary metabolites in varying concentrations, these includes alkaloids, tannins, phenolics, glycosides, saponins etc. However, the volume varies with the phenolics (43.50 ± 1.72) and anthraquinones (27.47 ± 2.52) in small quantities (Figure 1).

The antiplasmodial activity of ethanolic stem bark extract of *B. ferruginea* was evaluated in this study as depicted in Figure 2. Mice passaged with *P. berghei* (NK 65) were placed in different animal grouping with respect to the different extract concentrations to establish the therapeutic dose contents. It was observed that the treatment groups (Curative) all began to respond to the doses administered in terms of falling parasitemia counts beginning with the 800 mg/kg group responding at day 12 and by day 18, this group recorded no parasitemia count while the 400 mg/kg group had no parasites after day 22.

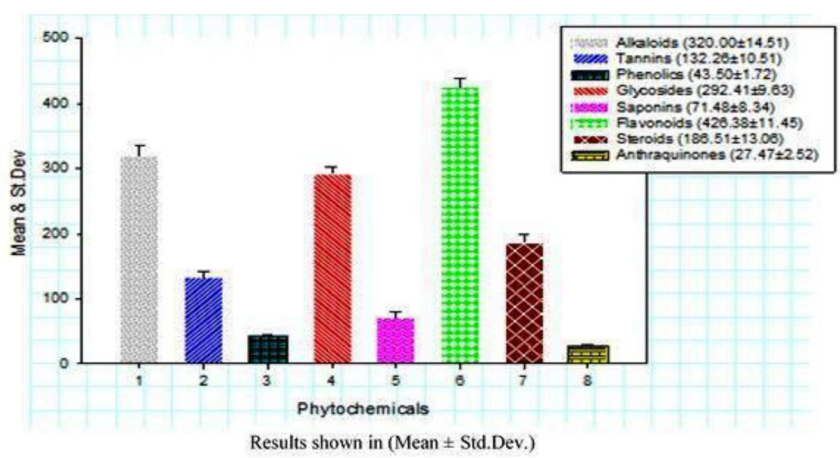

Figure 1: Composition of phytochemicals contained in the ethanolic stembark extract of *B. ferruginea*.

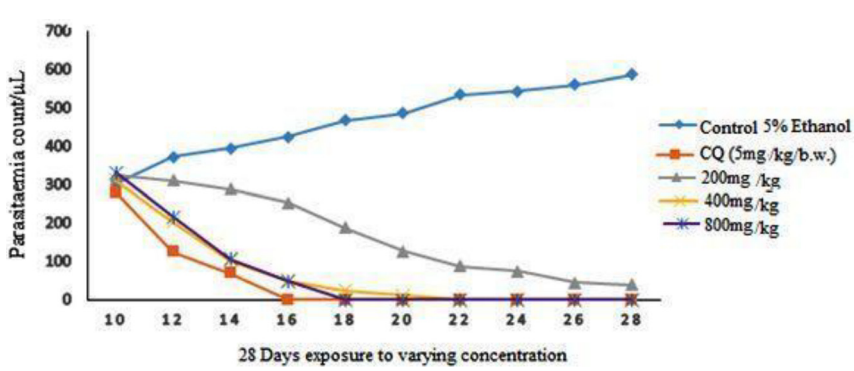

Figure 2: Curative group balb/c mice exposed to *Plasmodium berghei* (NK65) and treated with ethanolic stembark extract of *B. ferruginea* over 28 days.

However, the 200 mg/kg dose group had a steady decline in parasitemia but still carried on with the infection till the end of the 28 day study period. The CQ (5%mg/kg) group responded to treatment within the first two days (48 h) after CQ introduction and the parasitemia was completely cleared 16 days post infection. The dose-dependent decrease in parasitemia between the 800 mg/kg group and the CQ (5% mg/kg) showed significant correlation ($p < 0.05$). The control group administered with 5% mg/kg ethanol had rising parasitemia all through the study period with records of mortality within the group on day 22 and 24 respectively (one each).

The effect of weight gain/loss on exposure to varying concentration of the ethanolic stem bark extract of *B. ferruginea* showed that weight gain was statistically significant across the groups ($p < 0.05$) (Table 1).

The estimation of the median lethal dose (LD_{50}) was established using varying concentration of the ethanolic stem bark extract of *B. ferruginea* (Figure 3) with the sole aim of determining the point of toxicity where 50% of the mice will be dead. It was discovered that mortality occurred with the 200 and 400 mg respectively on the last day of exposure (one each), by day 16 all the mice in the 1,000 mg/kg group had died. No mortality was recorded for the control group throughout the study as they were administered with 5% alcohol daily. The 1,000 mg/kg exposure group exhibited overt sign of toxicity (salivation, diarrhea, yellowing of fur, loss of fur, postural abnormalities, and behavioral change), stress (fur erection and exophthalmos), and aversive behavior (biting and scratching behavior, licking of tail, paw and penis, intense grooming behavior, and vocalization) before death (Table 2).

The mortalities of the mice within 28 days on exposure of chronic dose of the ethanolic stem bark extract of *B. ferruginea* was calculated from the regression equation derived from the plot of the probits of mortalities (y) and the log of doses ($\log_{10}C$) as $y = 4.7112\ln(x) - 1.2529$. The antilog of this value returned 21.2443 indicating that the optimum dose that will not cause mortality is about 424 mg/kg (Figure 3).

Liver and kidney histology

Curative group

The histopathological evaluation of the liver obtained from the curative group after exposure to different concentrations of the ethanolic stem bark extract of *B. ferruginea* for

Table 1: Initial and final body weight of the mice used for the study after 28 days treatment at varying concentration.

Body weight in grams	Experimental Groupings (Mean ± Std. dev.)				
	Control	200 mg	400 mg	800 mg	p-value
Initial weight	16.09 ± 2.26	18.01 ± 0.58	17.66 ± 0.61	19.25 ± 3.58	ns
Final weight	14.52 ± 2.66	20.56 ± 0.35	19.98 ± 0.40	20.34 ± 3.40	<0.05
Difference	1.56 ± 0.51	2.55 ± 0.42	2.32 ± 0.40	1.09 ± 0.44	–
% Difference	−10.19 ± 4.86	12.41 ± 2.06	11.62 ± 2.02	5.61 ± 3.02	–

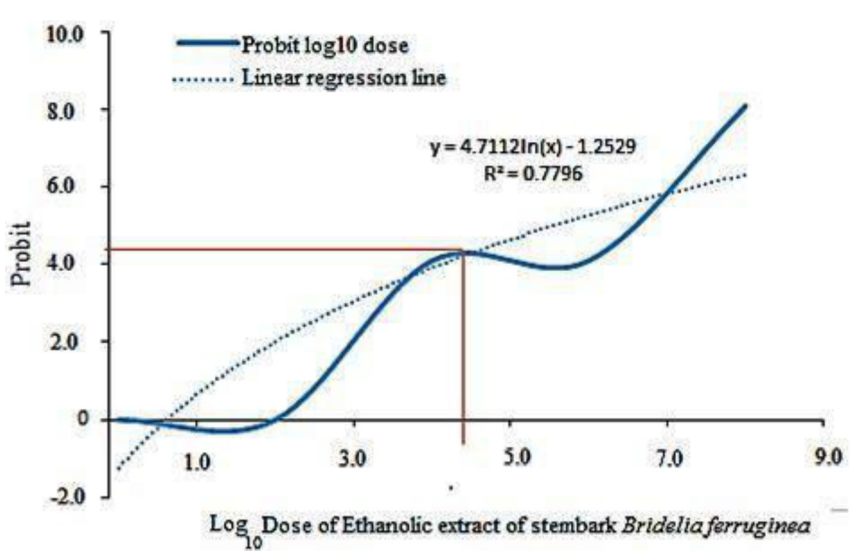

Figure 3: Point of toxicity, LC_{50} and LD_{50} in balb/c mice.

28 days revealed that the 200, 400 and 800 mg treated groups had no alterations in the histology of the liver when compared with the control group. All the treated groups showed customary distribution and typical density of the hepatocytes, the central vein (cv), hepatic cells (hc), portal vein (pv), endothelial cells (ec) and sinusoids (si) were intact (Figure 4).

Toxicity test group

Exposure of the groups that were not infected with *P. berghei* but treated with 1,000 mg/kg of the ethanolic extract induced significant alterations in the histology of the liver (Figure 5). These alterations revealed perturbations in the form of hepatoporosis creating tiny pores on the sinusoids and there were compromised cyto-architectural assortments. Alterations occurred in the staining patterns as shown by the yellow marks on the slides. The central veins and portal tracks (pt) were severely congested. Pyknosis, karyopyknosis and gradual onset of necrosis were also observed (Figure 4c) suggestive of irreversible condensation of chromatin in the nucleus. The tissues were dotted with increases in Kupffer cells (kc) leading to fragmentation and karyorrhexis.

Table 2: Determination of the LD_{50} value after exposure of mice to varying concentration of ethanolic stem bark extract of *Bridelia ferruginea*.

Dose (mg/kg)	Total mortality	Days after administration of varying concentration						
		4	8	12	16	20	24	28
200	0	0	0	0	0	0	0	0
400	1	0	0	0	0	0	0	1
800	1	0	0	0	0	0	0	1
1,000	5	0	1	2	2	0	0	0
Control	0	0	0	0	0	0	0	0

Toxicity test analysis (kidney)

Histopathological changes in kidney of mice exposed to the 1,000 mg/kg ethanolic stem bark extract of *B. ferruginea* for 28 days revealed mild pathological alterations. Only the glomerulus appear edematous and swollen within the Bowman's capsule (yellow dotted circle, Figure 6).

Hematological alterations

The results for the evaluation of hematological parameters on exposure to varying concentration of the ethanolic stem bark extract of *B. ferruginea* for 28 days as shown in Table 3 indicated that the mice treated group at 200 mg had values of hematocrit that were not significantly different from the control ($p > 0.05$), however the 400 and 800 mg had hematocrit values that were significantly different from the control ($p < 0.05$). Hemoglobin values for the control group was significantly lower (8.91 ± 0.87) when compared with all the treated groups. WBC, MCH, MCHC, MCV, and Granulocyte (%) count for all the treated groups were higher than that of the control. Granulocyte (109/L), platelets and Lymphocytes (%) counts were higher with the control and the 200 mg/kg treated groups, but lower in the 400 and 800 mg/kg treated groups.

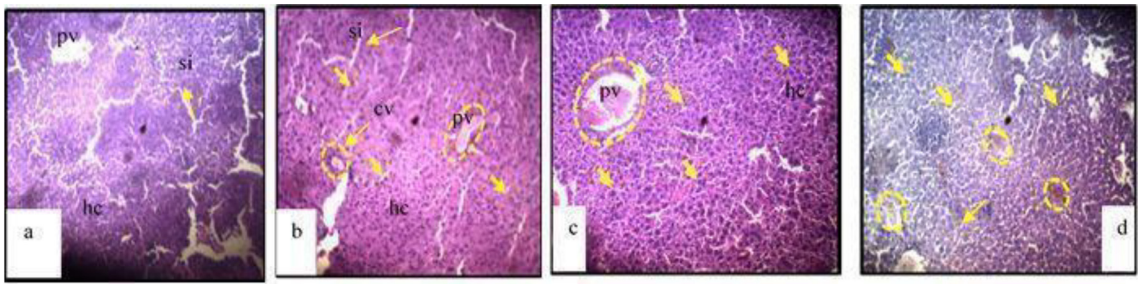

Figure 4: (a) Photomicrograph (Pmg) (control) showing normal distribution and typical density of hepatocytes. There are no pathological alterations apart from the poorly stained cytoplasmic content. The nuclei of the hepatocytes appear properly stained. (b) Pmg @ 200 mg *Bf*sbe showing customary distribution and typical density of hepatocytes (yellow arrows) surrounding the central vein (yellow circle). There are no pathological alterations apart. (c) Pmg @ 400 mg *Bf*sbe showing customary distribution and typical density of hepatocytes (yellow arrows) surrounding the central vein (yellow circle). There are no pathological alterations apart. (d) Pmg @ 800 mg *Bf*sbe showing normal distribution and typical density of hepatocytes (yellow arrows) radiating around the enlarged central vein (yellow circle). There are no pathological alterations apart from the poorly stained cytoplasm (Magnification ×400; Hematoxylin & Eosin stained). N.B. The cracks in the slides are mere tissue tearing that must have occurred during processing of thing sections of the liver.

Biochemical alterations

Biochemical parameters in both the control and treated group are as depicted in Table 3. It was observed that LDH, ALT, AST and urea titers were very high in the control group when compared with the treated test groups. However, the titers across the treated groups of varying concentrations showed a gradual decline, especially between the 200 and 400 mg/kg with AST and the values, were significant with the control ($p < 0.05$). The antioxidant activities of the ethanolic stem bark extracts of *B. ferruginea* at varying concentrations in the study revealed that SOD, GPx and CAT showed significant variation as compared to the control. Higher values were observed in the treated groups, except for MDA in the control which was higher than the treated groups, but was comparable with the 200 mg/kg treated group.

Discussion

Our study revealed varying concentrations of secondary metabolites as phytochemical constituents of the ethanolic stem bark extract of *B. ferruginea* which may be a reason for its antiplasmodial activity. Several authors have before now reported the potent antiplasmodial activity of these compounds in many medicinal plants [13, 13, 39–43]. It was observed that dose dependency determine total clearance of the parasite in the curative group. This in itself may probably be the reason for its use in traditional folkloric medicine [44–46]. The potent antiplasmodial activities observed in this study points to the chemotherapeutic potential of the ethanolic stem bark extract of *B. ferruginea* as an antimalarial agent and this assertion greatly conforms with the report by Mbah et al. [13] and Kolawole et al. [41]. Mbah et al. [13] placed their maximum extract

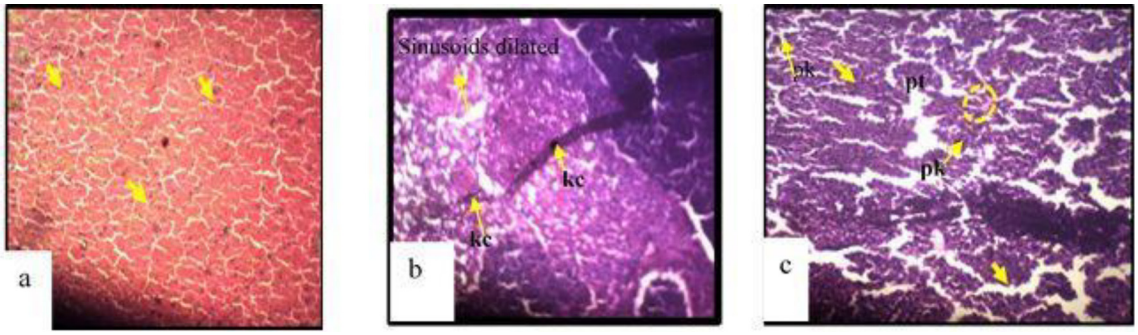

Figure 5: (a) Pmg @ 1,000 mg *Bf*sbe showing the poorly stained and reduced cellular density of hepatocytes (yellow arrows) suggesting mild pathological alteration in the histochemical composition of the liver. The cytoplasm appears well stained but the nuclei are poorly captured. Pmg @ 1,000 mg *Bf*sbe (day 10) showing perturbation in form of hepatoporosis and compromised cyto-architectural assortment. The nuclei and cytoplasm of the hepatocytes are poorly stained. (c) Pmg @ 1,000 mg *Bf*sbe showing pathological alterations staining pattern of the hepatocytes (yellow arrows). There are pyknotic changes in the liver morphology as marked by the staining mannerism. The nuclei and cytoplasm of the hepatocytes are darkly stained (Magnification ×400; Hematoxylin & Eosin stained).

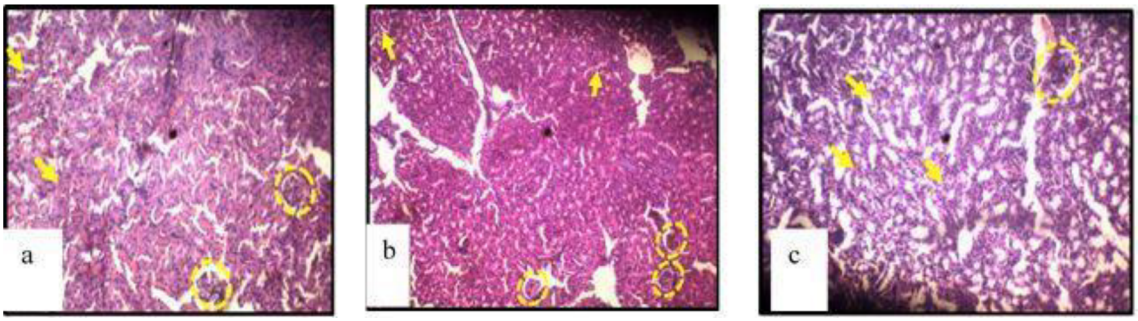

Figure 6: (a, b, c) Pmg @ 1,000 mg *Bf*sbe showing the renal cortex and renal medulla. The renal corpuscle appear characteristically normal with intact glomerulus sitting within the Bowman's capsule (yellow dotted circle). The other renal corpuscle (red dotted circle) appear with mild pathological alteration as the glomerulus appear edematous and swollen within the Bowman's capsule. The convoluted tubules (yellow arrow) appear with typically normal histomorphological presentation. ((Magnification ×400; Hematoxylin & Eosin stained).

Table 3: Effect of oral administration of *Bridelia ferruginea* stem bark extract on platelets, serum and organ parameters on the curative mice group after 28 days treatment.

Parameters	Treatment groups (Mean ± Std. dev.)			
	Control	200 mg/kg	400 mg/kg	800 mg/kg
Hematology				
PCV	44.84 ± 0.59[a]	47.10 ± 1.14[a]	51.36 ± 0.36[b]	52.85 ± 0.35[b]
Hemoglobin	8.91 ± 0.87	14.31 ± 0.27[b]	17.28 ± 0.26[b]	17.50 ± 0.45[b]
Red blood cell	17.07 ± 0.56	3.41 ± 0.23[b]	2.55 ± 0.14[b]	2.55 ± 0.34[b]
White blood cell	5.05 ± 0.57	10.24 ± 0.17[b]	9.17 ± 0.14[b]	8.16 ± 0.08[b]
MCH (pg)	10.29 ± 1.21	42.08 ± 3.40[b]	68.02 ± 4.41[b]	69.76 ± 11.19[b]
MCHC (%)	0.82 ± 0.19[a]	0.30 ± 0.01[a]	0.39 ± 0.08[a]	0.43 ± 0.01[a]
MCV (FL)	30.38 ± 0.81	138.44 ± 9.43[b]	174.48 ± 8.51[b]	162.61 ± 23.87[b]
Granulocyte(109/L)	29.10 ± 0.40	22.90 ± 0.26	19.00 ± 0.19[b]	15.05 ± 0.18[b]
Platelet	14.55 ± 0.56	6.12 ± 0.16[b]	4.97 ± 0.07[b]	3.98 ± 0.05[b]
Lymphocyte(109/L)	6.12 ± 0.16	17.85 ± 0.38[b]	18.51 ± 0.32[b]	19.22 ± 0.22[b]
Lymphocyte (%)	23.00 ± 0.71	17.85 ± 0.38[b]	11.80 ± 0.20[b]	11.08 ± 0.09[b]
Granulocyte (%)	13.39 ± 0.42	48.33 ± 0.36[b]	38.60 ± 0.79[b]	29.67 ± 0.32
Serum Enzymes				
LDH U/l	73.23 ± 0.35[a]	98.15 ± 0.33[a]	63.16 ± 0.26[a]	28.49 ± 0.26
ALT U/l	269.83 ± 0.54	110.51 ± 0.62[b]	115.4 ± 0.52[b]	119.18 ± 0.25[b]
AST U/l	43.62 ± 0.56[a]	33.56 ± 0.43[b]	34.56 ± 2.51[b]	44.00 ± 0.15[a]
Urea mmol/l	272.44 ± 3.33	243.96 ± 0.88	285.69 ± 0.98	326.07 ± 0.20
Organ				
SOD U/l	1.58 ± 0.18	2.61 ± 0.13[b]	5.17 ± 0.55[b]	4.90 ± 0.12[b]
GPx U/l	0.84 ± 0.02	1.26 ± 0.02[b]	2.60 ± 0.13[b]	2.75 ± 0.14[b]
CAT U/l	0.75 ± 0.02[a]	0.65 ± 0.03[a]	0.42 ± 0.02[a]	0.42 ± 0.02[a]
MDA U/l	4.62 ± 0.17	3.18 ± 0.13[b]	2.51 ± 0.08[b]	1.88 ± 0.24[b]

Superscripts with the same alphabet are not significant with the control @ $p < 0.005$.
Keys: PCV = Packed Cell Volume; MCH = Mean Corpuscular Hemoglobin; MCV = Mean Corpuscular Volume; LDH = Lactate Dehydrogenase; ALT = Alanine aminotransferase; AST = Aspartate aminotransferase. SOD = Superoxide dismutase; GPx = Glutathione peroxidase; CAT = Catalase; MDA = Malondialdehyde

administration at 400 mg/kg body weight. Quite parallel to Kolawole and Adesoye [41]; the 800 and 200 mg/kg doses failed to achieve considerable parasite clearance even when compared to chloroquine. The reason for the fluctuating decrease in 5% ethanol parasitemia is not known. The control group, however, maintained a steady rise in parasitemia throughout the study period with record of mortality occurring before the end of the drug trials which is consistent with several early reports [13, 41, 47]. However, the appropriate dose of the extract of *B. ferruginea* as an antiplasmodial drug may depend on several modified and non-modified risk factors such as age, sex, weight, other underlying health conditions and nutritional competence of the animal during the course of treatment. Up until now, there has not been enough scientific information to determine an appropriate range of doses or standard dose requirements to effect biocidal activity on the plasmodium parasites.

Body weight gain or loss are important factors to observe after administration of herbal extracts to ailing experimental animals, this is because they serve as an indication of toxicity and the effect are often detrimental to the overall wellbeing of the individual [48]. A loss in bodyweight is fundamental and often essential to toxicological evaluation where it serves as the first indicator of the adverse effect of drug reaction [24, 38]. The present study observed a slight increase in bodyweight of the experimental test animals when compared with the negative control which is an indication of the positive ameliorative potentials of the ethanolic stem bark extract of *B. ferruginea*. However, this result is contrary to early report by Awodele et al. [24], Bakoma et al. [49] and Taiwo et al. [50] but in consonance with the report by Odunlade et al. [51].

The therapeutic index (TI) is the range of doses at which a medication is effective without unaceptable adverse events. Drugs with a narrow TI have a narrow window between their effective doses and those at which they produce adverse effects [52]. The present study identified 424 mg/kg of the ethanolic stem bark extract of *B. ferruginea* as the minimal oral safe dosage that will not produce any lethal effect on the treated mice, while at 1,000 mg/kg there were significant overt signs of lethality

in the treated mice. Some the overt signs of toxicity manifested in the following consequences and lead to the subsequent death of all the mice after 28 days of exposure, these include; salivation, diarrhea, yellowing and loss of fur, postural abnoramlities, etc. Our findings negates with the observations of the following authors [13, 24, 26, 49 ,53]. Although Olarewaju et al. [26], reported sub-chronic weight loss at dosage of 400 mg/kg of the extract on albino rats. The probable explanation for the observable differences may be due to the extraction method, body ratio to mass index of the mice used for the study and the environmental settings, etc.

The assessment of the histological evaluation of the liver obtained from the curative group after exposure to different concentrations of the ethanolic stem bark extract of *B. ferruginea* revealed no significant alterations in the liver histological constitution of the experimental mice when compared to the control. Awodele et al. [24] and Bakoma et al. [49] reported in the same vein, that there was no hepatotoxicity effect on the liver at certain dose concentrations of the extract, but contrary to the studies by Odunlade et al. [51] and Olarewaju et al. [26]. These authors stressed that the toxic phytochemical componenets of *B. ferruginea* probably had a direct inhibitory effect on liver microsomal enzymes. Histology of the kidney for the curative group were not comparable so it is not reported for this study. However, on exposure of the experimental mice to 1,000 mg/kg of the aqueous extract, a number of significant alterations were observed ranging from hepatosporosis, cyto-architectural assortments, pyknosis, karyopyknosis and necrosis of the liver marked by increase in kupffer cells suggesting an irreversible damage to the liver. This is contrary to the studies by Awodele et al. [24] Bakoma et al. [49] and Olarewaju et al. [26]. For instance, Awodele et al. [24] reported that the liver on exposure to 1,000 mg/kg; 2,000 mg/kg and 4,000 mg/kg of the aqueous stem bark extract of *B. ferruginea* showed heavy lymphocytic infiltrates, congested sinuses and hemosiderin pigments. These alterations were a little bit different from the ones observed in our study probably because we used albino mice. Our study revealed a somewhat similar observation with the report by Odunlade et al. [51] where the experimental rats showed disintegration of the hepartic cells with karyolitic nuclei, extensive area of patchy and confluent hepatocyte necrosis and lobular inflammation, but Olarewaju et al. [26] observed that the aqueous extract of *B. ferruginea* stem bark may possibly confer protection on the liver tissues against injury, damage or disease, and the extract may not be toxic at the doses investigated. The kidney of the mice exposed to 1,000 mg/kg revealed mild pathological alterations. The glomerulus were edematous within the bowman's capsule which probably may lead to pyelonephritis [54], glomerulonephritis [55] and IgA nephropathy [56] A probable reason for the impending damage to the kidneys may be because of the presence of excessive tannins in the herbal extract as was earlier reported by Munuswarny et al. [57].

The experimental mice haemopoetic system were altered at higher dose (400 and 800 mg/kg respectively) concentration of the ethanolic stem bark extract of *B. ferruginea* after 28 days exposure, indicating the ameliorative potentials of the extract. Hematocrit is said to be a major determinant of blood viscosity, a lower than normal hematocrit is representative of anemia like the aplastic and thalassemia syndromes [58, 59]. An abnormally high hematocrit may be representative of polycythemia [60, 61]. For instance, the hematocrit values in the 400 and 800 mg/kg group were significantly different from the negative control. This result is a far cry from what was observed in early studies by Olarewaju et al. [25] but similar to the results reported by Awodele et al. [24]. However, granulocyte, platelets and lymphocytes counts reduced in the treatment groups when compared with the control signifying a further assertion of the amielorative activity of the herbal extract, similar reports were published by early authors although with different herbal coctions [62–65]. Thrombocytopenia is a condition of abnormally low number of platelets in blood circulation, this may result from decreased production or increased destruction of platelets occurring in some drugs that provoke platelet antibodies and lead to platelet destructions [59]. Our results suggest that the change in platelets counts in the treatment group count as compared with the control is significant, further giving credence to the herbal extract inability to induce thrombocytopenia at the dosage administered to the mice [24, 60, 66, 67]. Our findings also validate that the herbal extract at the administered dosages lack the ability to stimulate erythropoietin release by the kidney, which primarily is the site for humoral regulator of RBC production [68].

The presence of flavonoids in the preliminary phytochemical screening of ethanolic stem bark extract of *B. ferruginea* is an indication of its hepatoprotective and antioxidant activity on certain liver enzymes [13, 69, 70]. For instance, Osman and Ismail [71], reported that the phytochemical region of their extract yielded many antiplasmodial compounds with anthraquinone moiety. The presence of high concentrations of polyphenolic constituent including flavonoids and tannins in *Datura alba* showed strong antioxidant activity [72]. Certain non-enzymatic plant phytochemicals such as glutathione, polyphenols, bioflavonoids, carotenoids, hydroxycinnamates as well as some vitamins have shown to possess antioxidant

properties *in vitro* and *in vivo* [73]. Serum LDH, ALT, AST, ALP, total and direct bilirubin in plasma have been reported to be a sensitive indicator in liver injury [561, 61]. The observed decrease in the titer of some of the above mentioned enzymes in our study may point to the regenerative and repair of hepatic tissue damage occassioned by the *P. berghei berghei* adminitstration on the experimental mice as earlier reported and it is contrary to the study by Odunlade et al. [51]. This result corroborates the findings by [24, 38, 49, 74]. These authors observed that serum transaminase activities were restored with the healing of hepatic parenchyma and regeneration of hepatocytes at the dosage administered to the mice. Therefore, the hepatic physiological mechanisms which was earlier altered by the parasite were ameliorated by the ethanolic stem bark extract of *B. ferruginea* and this may serve as the index of its protective potentials [74].

Normal cellular metabolism and certain environmental factors stimulates the production of reactive oxygen species (ROS). ROS are highly reactive molecules and can damage cell structures such as carbohydrates, nucleic acids, lipids, and proteins and alter their functions [30]. Therefore, a shift in the balance between oxidants and antioxidants in favor of oxidants leads to oxidative stress. In our study, ROS detoxifying enzymes (superoxide dismutase (SOD), catalase, glutathione peroxidase) activities were significantly ($p < .05$) induced by the ethanolic stem bark extract of *B. ferruginea*. While MDA were significantly higher in the treatment group than the control. Our findings were in tandem with studies carried out by other authors describing the detoxification potentials of the herbal extract [24, 49, 75].

Conclusion

This study carried out a comprehensive analysis of the biological activities of the oral administration of the ethanolic stem bark extract of *B. ferruginea* on balb C albino mice and identified the therapeutic potentials of the extract for treatment of *P. berghei* (NK 65) infections. The ingestion of the extract produced slight increase in bodyweight. At a dose of 1,000 mg/kg, the animals showed significant alterations in the histology of the liver and kidney. The hematopoietic system of the mice showed improvements indicating the ameliorative capability of the extract at controlled dosages. The presence of flavonoids in the prelimary screening of the herbal extract points to positive hepatoprotective and antoxidant activity on some liver enzymes. The herbal extract also further induced ROS detoxification. The minimal oral safe dosage of herbal extract established was 424 mg/kg. Hence, the ethanolic stem bark extract of *B. ferruginea* used in this study greatly points to its efficacy as traditional folklore medication. However, further comprehensive research efforts on the extracts of *B. ferruginea* is expedient for comparative studies on isolation, infrared spectrometry, MS and NMR.

Acknowledgments: We express our sincere appreciation to the laboratory staff of Central Research Lab, Tanke, Ilorin for the provision of the assays and bench space. We equally thank Mr. Bolu Ajayi of the Department of Plant Biology, University of Ilorin for identifying to species level the *Bridelia ferruginea* plant used for this study. This research was an outcome of an in-house financially non-supported study.
Research funding: None declared.
Author contributions: All the authors have accepted responsibility for the entire content of this submitted manuscript and approved submission.
Competing interests: The funding organization(s) played no role in the study design; in the collection, analysis, and interpretation of data; in the writing of the report; or in the decision to submit the report for publication.
Employment or leadership: None declared.
Honorarium: None declared.

References

1. Garrod LP, Lambert HP, O'Gray F. Antibiotics and chemotherapy, 4th ed. Edinburgh, London and New York: Churchill, Livingstone; 1995.
2. Awodele O, Agbaje E, Ogunkeye F, Kolapo A, Awodele D. Towards integrating traditional medicine (TM) into National Health Care Scheme (NHCS): Assessment of TM practitioners' disposition in Lagos, Nigeria. J Herb Med 2011;1:90–4. https://doi.org/10.1016/j.hermed.2011.09.002.
3. Ekanem J, Kolawole O, Abbah O. Trypanocidal potential of methanolic extract of Bridelia ferruginea benth bark in Rattus novergicus. Afr J Biochem Res 2008;2:45–50. https://doi.org/10.5897/AJBR.
4. Njamen D, Nkeh-Chungag B, Tsala E, Fomum Z, Mbanya J, Ngufor G. Effect of Bridelia ferruginea (Euphorbiaceae) leaf extract on sucrose-induced glucose intolerance in rats. Trop J Pharm Res 2012;11:759–65. https://doi.org/10.4314/tjpr.v11i5.9.
5. Ekanem J, Kolawole O, Abbah O. Trypanocidal potential of methanolic extracts of Bridelia ferruginea (benth) bark in Rattus novergicus. Afr J Biochem Res 2008;4:45–50. https://doi.org/10.5897/AJBR.
6. Mbah C, Akuodor G, Anyalewechi N, Iwuanyanwu T, Osunkwo U. In vivo antiplasmodial activities of aqueous extract ofBridelia ferruginea stem bark against Plasmodium berghei berghei in mice. Pharm Biol 2012;50:188–94. https://doi.org/10.3109/13880209.2011.592537.

7. Nene-Bi S, Traore F, Soro T. Etudes phytochimique et pharmacologique de Bridelia ferruginea Benth (Euphorbiaceae) sur la motricité du Taenia coli de cobaye. Afr Sci 2009;5:305–20. https://www.ajol.info/index.php/afsci/article/view/61745.
8. Olarewaju OI, Oloyede O, Ojo OA, Onikanni SA, Ajiboye BO. Aqueous Bridelia ferruginea stem bark transaminase activities in Albino rats. Afr J Biochem Res 2014;8:84–7. https://doi.org/10.5897/AJBR.
9. De Bruyne T, Cimanga K, Pieters L, Claeys M, Dommisse R, Vlietinck A. Gallocatechim (4-0-7) – Epigallocatechin. A new Biflavonoid isolated from Bridelia ferruginea. Nat Prod Let 1997; 11:47–52. https://doi.org/10.1080/10575639708043756.
10. Cimanga K, De Bruyne T, Apers S, Dieters L, Totte J, Kambu K, et al. Complement- inhibiting constituents of Bridelia ferruginea stem bark. Planta Med 1999;65:213–17. https://doi.org/10.12691/ajfn-2-1-3.
11. Akuodor G, Mbah C, Essien A, Akpan J, Ezeokpo B, Iwuanyanwu T, et al. Ulcer-protective and Antidiarrhoeal effects of the aqueous stem bark extract of Bridelia ferruginea in Rodents. Pharmacol 2012;3:591–7. https://doi.org/10.5567/pharmacologia.2012.591.5.
12. Olajide OA, Makinde JM, Okpako DT, Awe SO. Studies on the anti-inflammatory and related pharmacological properties of the aqueous extract of Bridelia ferruginea stem bark. J Ethnopharmacol 2000;71:153–60. https://doi.org/10.1016/S0378-8741(99)00201-9.
13. Mbah C, Akuodor G, Anyalewechi N, Iwuanyanwu T, Osunkwo U. In vivo antiplasmodial activities of aqueous extract of *Bridelia ferruginea* stem bark against *Plasmodium berghei berghei* in mice. Pharm Biol 2012;50:188–94. https://www.researchgate.net/publication/288393452_Pharmacological_profile_of_aqueous_extract_of_Bridelia_ferruginea_stem_bark_in_the_relief_of_pain_and_fever/citation/download.
14. Mitchell R, Kumar V, Abul K, Fausto N. Robbins Basic Pathology. 8th ed. Vol.7. Philadelphia: Saunders; 2007., pp. 516-522. https://www.scirp.org/(S(vtj3fa45qm1ean45vvffcz55))/reference/ReferencesPapers.aspx?ReferenceID=1402515.
15. Atawodi S, Bulus T, Ibrahim S, Ameh D, Nok A, Mamman M, Galadima M. In vitro trypanocidal effect of methanolic extracts of some. Nigerian Savannah Plants. Afr J Biotechnol 2003;2:317–21. https://doi.org/10.5897/AJB2003.000-1065.
16. Atawodi S. Comparative in vitro trypanocidal activities of petroleum ether, chloroform, methanol and aqueous extracts of some Nigerian Savannah Plants. Afr J Biotechnol 2005;2:177–82.
17. Bakoma B, Berke B, Eklu-Gadegbeku K, Agbonon A, Aklikokou K, Gbeassor M, et al. Acute and sub-chronic (28 days) oral toxicity evaluation of hydroethanolic extract of Bridelia ferruginea Benth root bark in male rodent animals. Food Chem Toxicol 2013;52: 176–9. https://doi.org/10.1016/j.fct.2012.1.
18. Wintola O, Sunmonu T, Afolayan A. Effect of *Aloe ferox* Mill. in the treatment of loperamide-induced constipation in Wistar rats. Gastroenterology 2010;10:95–99. https://doi.org/10.1186/1471-230X-10-95.
19. Wintola O, Sunmonu T, Afolayan A. Toxicological evaluation of aqueous extract of *Aloe ferox* Mill. in loperamide induced constipated rats. Hum Exp toxicol 2010;30:425–31. https://doi.org/10.1186/1471-230X-10-95.
20. Pousset J. Medicinal plants used as a source of raw material for the pharmaceutical industry; problems and prospects. Drug production from natural products. In: Proceeding of the 7th international symposium. Ife, Nigeria: DRPU, Obafemi Awolowo Univ; 1988:37–41 pp. http://www.bioline.org.br/pdf?tc05032.
21. Ajani E, Sabiu S, Bamisaye F, Salami M, Nurain I. Evaluation of tha cute and sub-acute toxicity effect of ethanol leaves extract of *Lagenaria brevifoliab*(bitter gourd) on hepatic and renal function of rats. J Pharm Biol Sci 2014;9:61–8. https://www.ncbi.nlm.nih.gov/pmc/articles/PMC3307184/.
22. Sabiu S, Ashafa O. Toxicological implication and laxative potential of ethanol root extract of *Morella serrata* in loperamide-induced constiapated wistar rats. Pharmaceut Biol 2016;54: 2901–8. https://www.ncbi.nlm.nih.gov/pubmed/27267728.
23. Sunmonu T, Oloyede O. Performance and haematological indices in rats exposed to monocrotophos contamination. Hum Exp Toxicol 2010;29:845–50. https://doi.org/10.1177/0960327110363441.
24. Awodele O, Amagon K, Agbo J, Prasad M. Toxicological evaluation of the aqueous stem bark extract of Bridelia ferruginea (Euphorbiaceae) in rodents. Interdiscip Toxicol 2015;8:89–98. https://doi.org/10.1515/intox-2015-0014.
25. Olarewaju O, Oloyede O, Ojo O, Onikanni S. Effects of aqueous extract of Bridelia ferruginea stem bark on some haematological parameters of albino rats. Innovat Pharm Pharmacother 2013;1: 70–5. https://www.researchgate.net/scientific-contributions/2030416254_Olarewaju_OI. https://www.researchgate.net/publication/276699570_Protective_effect_of_Irvingia_gabonensis_stem_bark_extract_on_cadmiuminduced_nephrotoxicity_in_rats/citation/download.
26. Olarewaju O, Oloyede O, Ajayi O, Ojo O, Ajiboye B. Toxicity studies of the crude aqueous stem bark extracts of *Bridelia ferruginea* in Albino rats. Int J Pharm Toxicol Sci 2014;4:19–27. https://www.ncbi.nlm.nih.gov/pmc/articles/PMC4961903/.
27. Wells R, Melntyre R, Morgan A. Physiological stress responses in big game fish after exposure: observation on plasma chemistry and blood factors. Comp Biochem Physiol 1986;64A:565–71. https://doi.org/10.1016/0300-9629(86)90366-x.
28. Tilkian S, Conover M, Tilkian A. Clinical implications of laboratory tests. St Louis, Toronto and_London: C.V. Mosby Company; 1979: 3–44; 117–32; 154–9 p.
29. Srilaxmi P, Sareddy G, Kishor P, Setty O, Babu P. Protective effcacy of natansnin, a dibenzoyl glycoside from Salvinia natans against CCl4 induced oxidative stress and cellular degeneration in rat liver. BMC Pharmacol 2010;10:471–2210. https://doi.org/10.1186/1471-2210-10-13.
30. Birben E, Sahiner U, Sackesen C, Erzurum S, Kalayci O. Oxidative stress and antioxidant defense. WAO 2012;5:9–19. https://doi.org/10.1097/WOX.0b013e3182439613.
31. National Institute of Health. NIH guide for the care and use of laboratory animal (Revised). Bethesda, MD: NIH Publication; 1985, vol. 83-23. https://www.nationalacademies.org/.
32. Mfon AG, Dick EA, David-Oku E, Linus AJ, Chukwuma EB. Antimalarial potency of the leaf extract of Aspilia africana (Pers.) CD Adams. Asian Pac J Trop Med 2012;5:126–9. https://doi.org/10.1016/S1995-7645(12)60010-8.
33. World Health Organization. Malaria. Geneva: World Health Organization; 2010. https://apps.who.int/iris/bitstream/handle/10665/44449/9789241500470_eng.pdf.
34. Lorke D. A new approach to practical acute toxicity testing. Arch Toxicol 1983;54:275–87. https://doi.org/10.4103/0971-6580.121674.

35. Misra H, Fridovich I. The role of superoxide anion in the autoxidation of epinephrine and a simple assay for superoxide dismutase. J Biol Chem 1972;247:3170–5. https://www.ncbi.nlm.nih.gov/pubmed/4623845.
36. Ellman GL. Tissue sulfhydryl groups. Arch Biochem Biophys 1959; 82:70–7. https://www.ncbi.nlm.nih.gov/pubmed/13650640.
37. Sinha K. Colorimetric assay of catalase. Anal Biochem 1972;47: 389–94. https://doi.org/10.1016/0003-2697(72)90132-7.
38. Adisa RA, Sulaimon LA. Assessment of liver antioxidant status and mitochondrial membrane composition of Plasmodium berghei-infected mice treated with selected antimalarials. Acta Biochim Pol 2017;64:485–91. https://www.ncbi.nlm.nih.gov/pubmed/28787466.
39. Silva J, Ramos AdS, Machado M, Moura D, Zoraima Neto, Canto-Cavalheiro MM, et al. A review of antimalarial plants used in traditional medicine in communities in Portuguese-Speaking countries: Brazil, Mozambique, Cape Verde, Guinea-Bissau, São Tomé and Príncipe and Angola. Memórias do Inst Oswaldo Cruz 2011;106:142–58. http://www.scielo.br/scielo.php?script=sci_arttext&pid=S0074-02762011000900019.
40. Adebayo JO, Krettli AU. Potential antimalarials from Nigerian plants: A review. J Ethnopharmacol 2011;133:289–302. https://doi.org/10.1016/j.jep.2010.11.024.
41. Kolawole OM, Adesoye AA. Evaluation of antimalarial activity of *Bridelia Ferruginea* Benth bark. Can J Pure Appl Sci 2010;4:1039–44. https://doi.org/10.1590/S0074-02762011000900019.
42. Amoa Onguéné P, Ntie-Kang F, Lifongo LL, Ndom JC, Sippl W, Mbaze L. The potential of anti-malarial compounds derived from African medicinal plants. Part I: A pharmacological evaluation of alkaloids and terpenoids. Malaria J 2013;12:449.
43. Olajide OA, Makinde JM, Awe SO. Effects of the aqueous extract of *Bridelia ferruginea* stem bark on carrageenan-induced oedema and granuloma tissue formation in rats and mice. J Ethnopharmacol 1999;66:113–17. https://doi.org/10.1016/s0378-8741(99)00006-9.
44. Mbah CC, Akuodor GC, Anyalewechi NA, Iwuanyanwu TC, Osunkwo UA. In vivo antiplasmodial activities of aqueous extract of *Bridelia ferruginea* stem bark against Plasmodium berghei berghei in mice. Pharmaceut Biol 2012;50:188–94. https://doi.org/10.3109/13880209.2011.592537.
45. Adebayo JO, Krettli AU. Potential antimalarials from Nigerian plants: a review. J Ethnopharmacol 2011;133:289–302. https://www.sciencedirect.com/science/article/pii/S0378874110008093?via%3Dihub.
46. Khozirah S, Noor Rain A, Siti Najila MJ, Imiyabir Z, Madani L. In vitro Antiplasmodial properties of selected plants J Sci Technol 2011;19:11–17. http://psasir.upm.edu.my/id/eprint/40635/1/97.%20In%20vitro%20antiplasmodial%20properties%20of%20selected%20plants%20of%20Sabah.pdf.
47. Akuodor G, Mbah C, Anyalewechi N, Iwuanyanwu TC, Osunkwo U. Pharmacological profile of aqueous extract of Bridelia ferruginea stem bark in the relief of pain and fever. J Med Plants Res 2011;5: 5366–9. https://www.researchgate.net/publication/274031044_Pharmacological_profile_of_aqueous_extract_of_Bridelia_ferruginea_stem_bark_in_the_relief_of_pain_and_fever.
48. Singh A, Kumar R. Evaluation of acute toxicity of aqueous extract of Eclipta alba and its effects on liver of male Swiss albino mice. J Herb Med Tox 2011;5:89–95. https://doi.org/10.4103/0253-7613.106437.
49. Bakoma B, Berké B, Eklu-Gadegbeku K, Agbonon A, Aklikokou K, Gbeassor M, et al. Acute and sub-chronic (28 days) oral toxicity evaluation of hydroethanolic extract of Bridelia ferruginea Benth root bark in male rodent animals. Food Chem Toxicol 2013;52: 176–9. https://www.sciencedirect.com/science/article/pii/S0278691512008289?via%3Dihub.
50. Taiwo I, Adewumi O, Odeigah P. Assessment of Bridelia ferruginea benth for its therapeutic potential in pregnancy-induced impaired glucose tolerance in rats. Int Res J Med Biomed Sci 2012;1:49–55. https://www.researchgate.net/publication/335960184_Assessment_of_Bridelia_ferruginea_benth_for_its_therapeutic_potential_in_pregnancy-induced_impaired_glucose_tolerance_in_rats/citation/download.
51. Odunlade A, Taiwo I, Arojojoye O, Lawal T. Hepatotoxicity of aqueous leaf extract of Bridelia ferruginea on the liver of Albino rats. Int J Nat Sci Res 2015;5:57–64. https://www.iiste.org/tag/journal-of-natural-sciences-research-call-for-papers/page/3/.
52. Tamargo J, Le Heuzey J-Y, Mabo P. Narrow therapeutic index drugs: a clinical pharmacological consideration to flecainide. Eur J Clin Pharmacol 2015;71:549–67. https://www.ncbi.nlm.nih.gov/pmc/articles/PMC4412688/.
53. Ezike AC, Akah PA, Nnamani EM, Okoli CO, Ojike FU, Eze FS, et al. Studies on the antiulcer and gastrointestinal effects of stem bark extract of Bridelia ferruginea. J Compl Integr Med 2011;8. https://europepmc.org/article/med/22754933. 22754933.
54. Kolawole O, Olayode J, Oyewo O, Adegboye A, Kolawole C. Toxicological renal eff ects of Bridelia ferruginea-treated wastewater in rats. Afr J Microbiol Res 2009;3:82–7. https://academicjournals.org/journal/AJMR/article-full-text-pdf/0792C6612243.
55. Nene BSA, Zahoui OS, Soro TY. Effects of Bridelia ferruginea Benth. (Euphorbiaceae) aqueous extract on renal function in the rat. Int J Cardiol 2011;152:S62. https://www.ncbi.nlm.nih.gov/pubmed/10432217.
56. Lim AKH. Diabetic nephropathy – complications and treatment. Int J Nephrol Renovascular Dis 2014;7:361–81. https://doi.org/10.2147/IJNRD.S40172.
57. Munuswamy S, Gnanamani A, Deepa G, Sudha M, Madharacheryulu E, Deivanai K. In vivo studies on evaluation of potential toxicity of unspent tannins using albino rats (*Rattus novergicus*). Food Chem Toxicol 2008;46:2288–2295. https://academicjournals.org/journal/AJMR/article-full-text-pdf/0792C6612243.
58. Arika WM, Nyamai DW, Musila MN, Ngugi MP, Njagi ENM. Hematological Markers of In Vivo Toxicity. J Hematol Thromb Dis 2016;4:1–7. https://doi.org/10.4172/2329-8790.1000236.
59. Weingand K, Brown G, Hall R, Davies D, Gossett K, Neptun D, et al. Harmonization of animal clinical pathology testing in toxicity and safety studies. The Joint Scientific Committee for International Harmonization of Clinical Pathology Testing. Fundam Appl Toxicol 1996;29:198–201. https://www.ncbi.nlm.nih.gov/pubmed/8742316.
60. Okpuzor J, Ogbunugafor H, Kareem GK. Hepatic and hematologic effects of fractions of *Globimetula Braunii* in normal albino rats. EXCLI Journal 2009;8:182–9. https://www.semanticscholar.org/paper/Hepatic-and-hematologic-effects-of-fractions-of-in-Kareem-Ogbunugafor/e16d3d057f00c5653b0e78d447c8ed6dcd1faf79.
61. Patrick-Iwuanyanwu KC, Onyeike EN, Wegwu MO. Hepatoprotective effects of methanolic extract and fractions of African mistletoe Tapinanthus bangwensis (Engl. & K. Krause) from

Nigeria. EXCLI Journal 2010;9:187–94. https://www.ncbi.nlm.nih.gov/pmc/articles/PMC5698891/.
62. Evaluation of hematological and biochemical activity of ethanolic extract of Zygophyllum simplex Linn. in wistar rats, 2016. Pakistan J Biol Sci: PJBS 9, 179–84. https://doi.org/10.3923/pjbs.2016.179.184.
63. Ladokun O, Ojezele M, Arojojoye O. Comparative study on the effects of aqueous extracts of viscum album (mistletoe) from three host plants on hematological parameters in albino rats. Afr Health Sci 2015;15:606–12. https://doi.org/10.4314/ahs.v15i2.38.
64. Ofem O, Ani E, Eno A. Effect of aqueous leaves extract of *Ocimum gratissimum* on hematological parameters in rats. Int J Appl Basic Med Res 2012;2:38–42. http://www.ijabmr.org/article.asp?issn=2229-516X;year=2012;volume=2;issue=1;spage=38;epage=42;aulast=Ofem.
65. Nigatu D, Mekbib A, Asfaw D, Eyasu M, Wondwossen E, Bekesho G. Assessment of hematological, biochemical and histopathological effects of acute and sub-chronic administration of the aqueous leaves extract of Thymus schimperi in rats. J Clin Toxicol 2016;6. https://doi.org/10.4172/2161-0495.1000286.
66. Ola-Davies OE, Olukole S., Amoo OA. Haematological and serum biochemical variables in rats treated with ethanol extract of the root of *Moringa oleifera*. Afr J Biomed Res 2014;17:31–5. https://www.researchgate.net/publication/306107787.
67. Ogbunugafor H, Igwo-Ezikpe M, Igwilo I, Ozumba N, Adenekan S, Ugochukwu C, et al. In vitro and in vivo evaluation of antioxidant properties of *Moringa Oleifera* ethanolic leaves extract and effect on serum lipid indices in rat. Macedonian J Med Sci 2012;15: 397–403. http://www.mjms.mk/Online/MJMS_2012_5_4/MJMS.1857-5773.2012-0240.pdf.
68. Erslev A. Humoral regulation of red cell production. Blood 1953;8:349 https://www.ncbi.nlm.nih.gov/pubmed/13032205.
69. Okwu DE, Ukanwa N. Isolation and characterization of flavonoids chalcones and anthocynidines from Bridelia ferruginea benth. Chem Sin 2010;1:21–8. https://www.researchgate.net/publication/265033845.
70. Kareem K, Kareem S, Adeyemo O, Egberongbe R. In vitro antimicrobial properties of Bridelia ferruginea on some clinical isolates. Agric Biol J N Am 2010;1:416–20. https://journals.sagepub.com/doi/10.1177/1934578X1801301207.
71. Osman CP, Ismail NH. Antiplasmodial anthraquinones from medicinal plants: the chemistry and possible mode of actions. Nat Prod Commun 2018;13. https://doi.org/10.1177/1934578X1801301207.
72. Khan W, Subhan S, Shams DF, Afridi SG, Ullah R, Shahat AA, et al. Antioxidant potential, phytochemicals composition, and metal contents of Datura alba. BioMed Res Int 2019; 2019:1–8. https://www.hindawi.com/journals/bmri/2019/2403718/.
73. Engwa GA., November 7th 2018. Free radicals and the role of plant phytochemicals as antioxidants against oxidative stress-related diseases. Phytochemicals: Source of Antioxidants and Role in Disease Prevention. Source of Antioxidants and Role in Disease Prevention, Toshiki Asao and Md Asaduzzaman, IntechOpen, pp. 49–74. https://doi.org/10.5772/intechopen.76719. Available from: https://www.intechopen.com/books/phytochemicals-source-of-antioxidants-and-role-in-disease-prevention/free-radicals-and-the-role-of-plant-phytochemicals-as-antioxidants-against-oxidative-stress-related.
74. Olarewaju O, Oloyede O. Aqueous Bridelia ferruginea stem bark transaminase activities in albino rats. Afr J Biochem Res 2014;8: 84–7. https://academicjournals.org/journal/AJBR/article-abstract/3AF6D8544720.
75. Ajiboye T, Abdussalam F, Adeleye A, Iliasu G, Ariyo F, Adediran Z, et al. Bridelia ferruginea promotes reactive oxygen species detoxification in N-nitrosodiethylamine-treated rats. J Diet Suppl 2013;10:210–28. https://pubs.acs.org/doi/10.1021/jf00039a005.