THE TROPICAL JOURNAL OF HEALTH SCIENCES

Volume 19 Number 2 July, 2012

CONTENTS

Editorial comments ____ v

Research papers

Effect Of Interval Training On Blood Pressure And Exercise Capacity In Hypertension: A Randomized Controlled Study
S. Lamina, R.C. Nwacha & G.C. Okoye ____ 1

Vitamin E or Red Palm Oil Increases The Level Of Nitric Oxide In Wistar Rats Chronically Exposed To Dichlorvos.
S.B. Akinyoola , V.F. Edem, O.G. Arinola & O. Owoeye ____ 8

Psychiatric Disorders Among People Living With HIV/AIDS Attending Outpatient Clinics At University Of Ilorin Teaching Hospital, Nigeria
D Sulyman, O.A. Abiodun, A.D. Yussuf ____ 12

Haemostatic Parameters During Pregnancy In Ilorin, Nigeria
I.A. Durotoye, A.S. Babatunde, H.O.Olawumi, P.O.Olatunji, J.O. Adewuyi ____ 18

Improved Erythrocyte Osmotic Fragility and Packed Cell Volume following administration of Aloe barbadensis Juice Extract in Rats.
L.S. Ojulari, A.A. Safiriyu, M.T. Ayinla, J.K. Abdulsalam, A.O. Oyabambi, O.A. Adegoke ____ 23

Effects Of Telfairia occidentalis On The Heamatological Parameters, Liver And Spleen Of Pregnant Wistar Rats
R.E.Kadir, G.O.Omotoso , A.A.Akinlolu, B.U.Enaibe, O.B.Gbenle ____ 27

Garlic Consumption Alters Testicular Histology and Anti-Oxidant Status In Wistar Rats.
G.O.Omotoso, A.O Oyewopo, I.O Onanuga, B.U Enaibe. ____ 31

Acute Coronary Syndrome In Zanzibar, Tanzania
Salim Budha ____ 34

Case Report

Cryptococcal Meningitis, A Rare Opportunistic Infection In An HIV Infected Nigerian Boy: A Case Report
A.A. Abdulkarim , O.S. Katibi, S.S. Mohammed, H.A. Ekundayo , A. Fadeyi, A.J. Alarape. ____ 37

Cerebral And Myocardial Infarction In A Patient With Uncorrected Tetralogy Of Fallot
W. E. Sadoh, I. N. Adigweme, E. J. Ogbemudia ____ 40

Effects Of Telfairia occidentalis On The Heamatological Parameters, Liver And Spleen Of Pregnant Wistar Rats

[1,2]R.E.Kadir [1]G.O.Omotoso , [1]A.A.Akinlolu, [1]B.U.Enaibe, [1]O.B.Gbenle

Departments of [1]Anatomy, Faculty of Basic Medical Sciences and [2]Obstetrics and Gynaecology, College of Health Sciences, University of Ilorin, Ilorin, Nigeria.

Abstract

Telfairia occidentalis is a dioecious perennial vine widely used for its medicinal and dietary benefits. The study was designed to evaluate the effect of T. occidentalis on haematological parameters of pregnant rats following oral administration, as well as its effects on the liver and spleen of these rats. Fifteen pregnant Wistar rats weighing between 110-130 g were used for the study. The rats were divided into 3 groups: Group A was the control, Group B was the treatment group given T. occidentalis twice daily for 4 days, while Group C received the extract twice daily for 10 days. Findings showed increase size in hepatocytes of the treated groups and increase in the trabeculae and white pulp of the treated group non-statistically significant increases in haematological parameters (RBC, PCV haemoglobin level and lymphocyte count) of treated animals. These increases in blood parameters observed in this study were not as pronounced as those obtainable in non-pregnant and male rats.

Keywords: Telfairia occidentalis, haematlogical parameters, cytoarchitecture, liver, spleen.

Introduction

Plants provide an alternative strategy when we are in search of new drugs. There is an abundance of plants reputed in traditional medicine to possess protective and therapeutic properties. It is likely that plants will continue to be a valuable source of new molecules which may, after possible chemical manipulation provide new and improved drugs[1]. Traditional medicinal plants are a therapeutic resource used by the population of the continent specifically for health care which may also serve as starting materials for drugs[2].

Correspondence to:

R.E. Kadir
Department of Anatomy,
Faculty of Basic Medical Sciences,
University of Ilorin, Ilorin, Nigeria.
ennyshittabey@yahoo.com

T. occidentalis, commonly called fluted pumpkin, locally known as Ugwu, occurs in the forest zone of West and Central Africa, most frequently in Benin Republic, Nigeria and Cameroon. It is a local herb commonly consumed as vegetables in many parts of Nigeria especially the Igbo tribe[3]. The amino acid profile of T. occidentalis has also been shown to be very rich and includes alanine, aspartate, glycine, glutamine, histidine, lysine, methionine, phenyl alanine, valine, tyrosine and isoleucine[4]. Other studies revealed that the long term feeding of T. occidentalis supplemented diet caused a significant increase in weight of animals which may be due to its content of rich nutrients[5].

The symptoms of protein energy malnutrition such as kwashiorkor and marasmus were rarely observed among dwellers in region where adequate amount of protein is obtained from fruits/seed and leaves of plants rich in protein such as T. occidentalis. It is observed that the leaf meal of T. occidentalis caused increased growth in bird. T. occidentalis has also been found to protect and ameliorate oxidative brain and liver damage induced by malnutrition in rats[6]. Various studies have confirmed the hepatoprotective properties of T. occidentalis leaves[5,7,8]. Some of these activities could be attributed to the high antioxidant activity of the extracts of T. occidentalis leaves.

Aqueous extracts of T. occidentalis had been reported to reduce blood glucose level and also have antidiabetic effects in glucose-induced hyperglycemic and streptozotocin-induced diabetic mice, while it did not alter the glucose levels in normoglycemic mice[9].

Materials And Methods

Twenty seven (27) female rats weighing between 110-130g were used for the experiment. They were acclimatized for 2 weeks prior to commencement of the experiment. They were exposed to male Wistar rats for mating during the proestrus cycle, these lasting thirteen days as the rats got pregnant at different times. Three female rats to one male rat were put in each cage. The female rats had daily vaginal smears to confirm the presence of spermatozoa in the vagina. The female Wistar rats were also examined for the presence of vaginal plug in the vaginal orifice, which signifies pregnancy.

Sixteen of the female rats became pregnant, and the mating was cohabitation in the rats was ended. This constituted 59% pregnancy rate as at day 13 of cohabitation. Fifteen of the pregnant rats were isolated

for the study, and were randomly grouped into three, as follow:

- Control Group A: fed with normal diet and water
- Group B: given T. occidentalis for 4 days during the 1st trimester (Days 4, 5, 6 and 7)
- Group C: given T. occidentalis for 10 days during all the trimester (Days 4-7, 11-14, 18 and 19).

Administration of Extract and Collection of Blood Samples and Tissue Specimens

Fresh leaves of T. occidentalis were obtained, weighed and quizzed to extract the pure juice of the plant. 90mg/ml of T. occidentalis was obtained and administered daily to the pregnant rats in two divided doses. The extract was prepared freshly every morning. The animals were sacrificed the day after the administration of the extract was stopped. Cervical dislocation method of sacrificing was used. The excision of the tissue (liver, spleen and blood) was surgical through the opening of the anterior abdominal wall. Blood samples were taken from the abdominal aorta of the rat into EDTA bottles for haematological studies.

The liver and spleen specimens were fixed in 10% formol saline, and thereafter processed histologically.

Data obtained from the haematology results were subjected to the Student's t-test and analysed for statistical significance.

Results

Histology Result

The liver histology of the groups that were treated with telfaira occidentalis was similar to that of the control group. The sinusoids (S) were preserved in all these slides. The hepatocytes (H) were all preserved and the nuclei (N) were similarly stained. There was no significant increased density of the hepatocytes and no increased intensity in staining of the nuclei was noted in the treated group compared to the control group. However, the hepatocytes of the treated groups appeared larger than the Control.

The splenic histology of the control group was similar to that of the group B (group that had the extract for 4 days). The trabeculae, white pulp and red pulps were all preserved, both in concentration and intensity of staining with dye. However, group C had increased concentration of the trabeculae and densely stained white pulp.

Haematology Results

The result showed a total reduction in white blood cell counts of pregnant rats in the treated groups compared to the control, and the reduction was more in Group C animals. However, this same group had increase in lymphocyte count compared to the other groups. This difference was not statistically significant ($p > 0.05$). In the case of the red blood cell count, animals fed with T. occidentalis had slight increases in their RBC count compared with the Control, this difference also was however not statistically significant ($p>0.05$). Animals that received T. occidentalis for a longer period had the higher count of RBC. Animals in Group B that had T. occidentalis for 4 days, which was during the first trimester, recorded a highest level of packed cell volume (PCV) and haemoglobin, compared with the other groups.

Discussion

Telfairia occidentalis is a plant commonly consumed in western part of Africa, and popularly believed to improve blood parameters.

The hepatocytes of the treated groups were larger than those of the control. Hepatocytes function in extramedullary haematopoiesis, which may explain the increases seen in the treated groups. The spleen also functions in extramedullary haematopoiesis. The increase in staining noted in the white pulp of group C may be responsible for the increase in lymphocyte count noted in this group, as the function of the white pulp is production of white blood cells - especially lymphocytes, which produces antibodies that are part of infection fighting immune system. The trabeculae are connective tissues which help in supporting the

Haematology Results

Parameters	A	B	C
WBC x 10^9	8.93±0.68	6.53±1.16	5.58±0.89
N	53.25±4.50	53.25±2.69	49.50±4.18
L	43.50±3.78	43.75±2.84	47.25±4.92
M	3.33±1.45	2.67±1.20	3.50±0.50
E	0.75	0.5	0.75
Hb (g/dl)	10.83±0.64	11.30±0.90	10.88±0.28
PCV (%)	32.50±1.94	34.50±3.01	32.75±0.86
RBC x 10^{12}	3.40±0.32	3.55±0.56	3.57±0.21

None of the differences between the different groups is statistically significant ($p>0.05$)

HISTOLOGY RESULTS

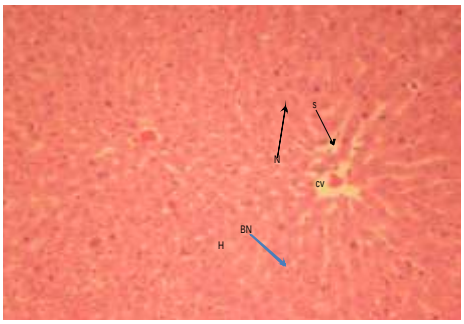

Plate 1. A photomicrograph of a section of the liver of pregnant wistar rats in group A (control group) using H&E stain(magnification x250).

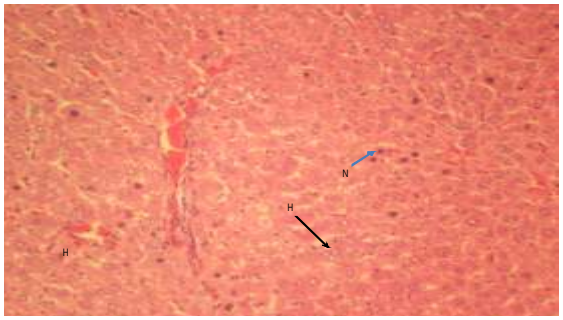

Plate 2. A photomicrograph of a section of the liver of pregnant wistar rats in group B (with 4days of *T.Occidentalis* administration using H&E stain (magnification x250).

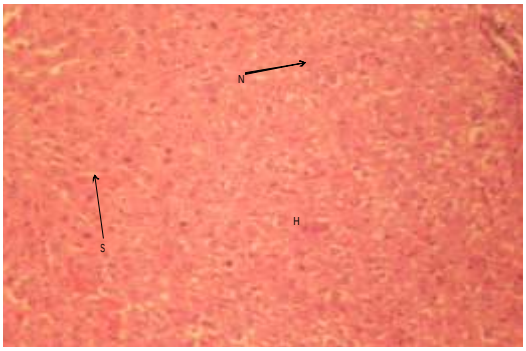

Plate 3. A photomicrograph of a section of the liver of pregnant wistar rats in group B (with 10days of *T.Occidentalis* administration) using H&E stain (magnification x250).

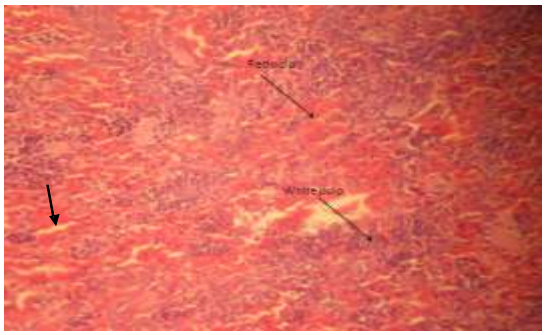

Plate 4. A photomicrograph of a section of the spleen of pregnant wistar rats in group A (control), using H&E stain (magnification x250). The unnamed arrow is the trabecula.

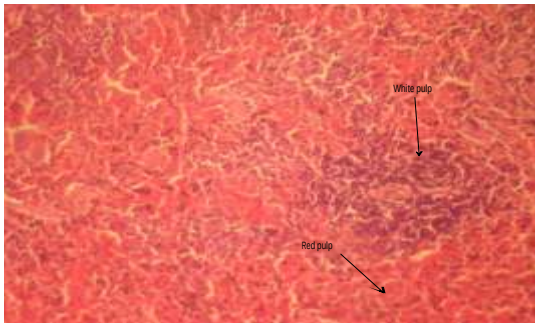

Plate 5. A photomicrograph of a section of the spleen of pregnant wistar rats in group B (with administration of *T. Occidentalis* for 4 days), using H&E stain (magnification x250).

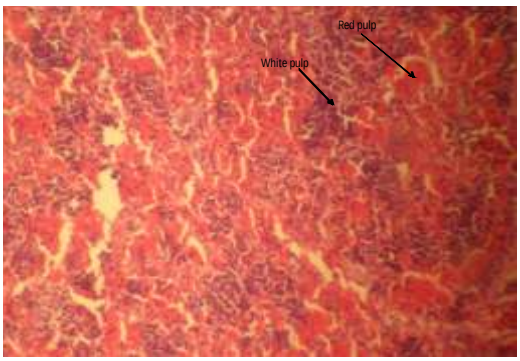

Plate 6. A photomicrograph of a section of the spleen of pregnant wistar rats in group B (with administration of *T.Occidentalis* for 10days), using H&E stain (magnification x250).

blood vessels.

Some studies that were conducted previously have demonstrated that Telfairia occidentalis extract significantly increased haematological parameters [10,11,12], though these results also showed that the increase in the haematological indices started after the seventh day of treatment, signifying a long term administration before a significant increase can be appreciated. Studies by Fiona and Gladys (2011) on administration of T. occidentalis leaves showed a modest increase in haemoglobin (Hb) levels in anaemic mice.

In the current study, though there were increases in erythrocyte count, PCV and haemoglobin levels in treated animals, these were not statistically significant. The reason for this probably was due to the short duration of administration, especially in Group B. The rats used in the current experiment were pregnant rats, which is in contrast to previous studies, where non pregnant rats or male rats were used. Pregnancy increases the plasma volume, and causes a physiological dilutional anaemia. This could also be a reason why a significant increase was not observed in this study. However, increasing the dose and duration of administration might yield very significant increases in haematological parameters studied. Meanwhile, increasing the dose may be associated with teratogenic effects in the fetus and/or tissue distortion or destruction in the mother. This increase dose dependent deleterious effect was demonstrated by Saalu et al when doses of 400mg/ml or more were used. Studies by Fiona and Gladys (2011) on administration of T. occidentalis leaves showed a modest increase in

haemoglobin (Hb) levels in anaemic mice.

In conclusion, studies on administration of T. occidentalis leaves showed a modest increase in haemoglobin (Hb) levels in anaemic mice. Most of the significant haematological effects of use of T. occidentalis are evident when administered over a long-term duration [13].

The slight increases in erythrocyte count, PCV and haemoglobin noticed in this study, might not be unconnected with the pregnancy state of animals used for the experiment.

Therefore, pregnant women should continue to be encouraged on taking haematenics and blood transfusion as required, until further studies can substantiate this general belief.

Also, further studies involving increase doses of T. Occidentalis in pregnant rats will be required.

References

1. Shaw T. Studies on interhepatic arterial circulation. Surgery. 2008; 33:333-41.

2. Sofowora A. (1986): Nigeria medicinal plants, pharmacology and toxicology in the state medicinal plants research in Nigeria. University of Ibadan Press.

3. Oguntona T. Nutritional quality of plant foods the green leafy vegetable 1988; 5:120-33.

4. Tindail H.D. Commercial vegetable growing, oxford university press: London; 1968; p.69.

5. Emeka EJ, Iweala, Obidoa Onyechi: Some Biochemical, Haematological and Histological Responses to a Long Term Consumption of Telfairia occidentalis-Supplemented Diet in Rats. Pakistan Journal of Nutrition. 2009; 8:1199-1203.

6. Fasuyi.M, Nonyerem.H. Composition of some Nigeria leafy vegetable J. Amer. Diet Assoc. 2007; 53 (2):130-2.

7. Oboh G. Hepatoprotective property of ethanolic and aqueous extract of fluted pumpkin (Telfairia occidentalis) leaves against garlic-induced oxidative stress. J. Med. Food. 2005; 8:560-3.

8. Nwanna EE, Oboh G. Antioxidant and hepatoprotective properties of polyphenol extracts from Telfairia Occidentalis (fluted pumpkin) leaves on acetaminophen induced liver damage. Pak. J. Biol. Sci. 2007; 10:2682-7.

9. Ifon E.T. and Bassir O. The nutritive value of some Nigeria leafy green vegetable. Part I vitamin and mineral content. Food Chemistry. 1979; 5:263-7.

10. Alada, A. The hematological effects of Telfairia occidentalis diet preparation. Afri. J. Biomed. Res. 2000; 3(3):185-6.

11. Nwangwa, E. K. 2006. Effects of Aqueous extract of Telfairia occidentalis on hematological parameter of rats. J. App. Sci. (In press)

12. Oyeyemi M. O.T, Leigh, O.O., Ajala, O. O.Badejo,A .O. , Emikpe, BO (2008): The effects of the aqueous extract of Telfairia occidentalis leaves on the testis and spermatozoa characteristics in male Albino rats. Folia Veterinaria. 2008; 52(2):102-5.

13. Fiona Hamlin and Gladys O Latunde-Dada. Iron bioavailability from a tropical leafy vegetable in anaemic mice. Nutrition & Metabolism. 2011;8:9