Toxicology Reports 6 (2019) 496–504

Contents lists available at ScienceDirect

Toxicology Reports

journal homepage: www.elsevier.com/locate/toxrep

Safety effect of fractions from methanolic leaf extract of *Ocimum gratissimum* on reproduction in male wistar rats

Anoka A. Njan, Solomon O. Olaoye, Saheed O. Afolabi, Benjamen C Ejimkonye, Anthonia Soje, Olufunke E. Olorundare, Ezekiel O. Iwalewa

University of Ilorin, Department of Pharmacology and Therapeutics, Faculty of Basic Medical Sc, 240003, Ilorin, Nigeria

ARTICLE INFO

Keywords:
Reproductive toxicity
Serum testosterone
Sperm parameters
Testes

ABSTRACT

This study evaluates the reproductive toxicity of ethyl acetate and butanolic fractions from crude methanolic leaf extract of *Ocimum gratissimum* in male Wistar rats. Acute toxicity was assessed to determine the safety dose, Sub-chronic reproductive toxicity studies were carried out by administering daily 25, 100 and 400 mg/kg body weight doses of the fractions to respective group of animals and 1 ml of normal saline daily for the control group for 28 days. Blood, epididymis and testes were harvested for reproductive hormones, sperm parameters, and histopathologic analysis respectively. There was significant ($P < 0.05$) increase in serum levels of testosterone, body-weight gain, sperm count. There was also apparent increase in mean-testicular weight and preservation of testicular histology with increase spermatogenesis in both the ethyl acetate and butanolic fraction treated groups compared with control. Serum levels of luteinising hormone was however significantly ($P < 0.05$) decrease across the groups compared to control. These effects were more pronounced in the butanolic fraction group compared to the ethyl acetate treated group. Sperm motility was also significantly ($P < 0.05$) higher in the ethyl acetate treated group compared to control. Findings from this studies demonstrate that these fractions were non-toxic at the tested doses with regards to male reproduction but, rather, exhibited fertility enhancing effects which was better with the butanolic fraction. Our findings also shows that the ethyl acetate fraction may be safer than the butanolic fraction.

1. Introduction

Man has, for long, depended on ingesting herbs as supplements for body preservation as well as therapy for several ailments such as diarrhoea, lower respiratory tract infection, common cold and skin infections [1,2]. The ingestion of these natural products has increased incredible global endorsement in recent years [3]. Factors attributed to this include the desire to naturally keep the body healthy [4], and exploration for compounds that are active against diseases with rarity of medications [5] as well as those that differed existing medications such as human immunodeficiency virus infection [3]. Adverse actions complicating the use of conventional medicines [6,7], beliefs among users that herbs lacks toxic effects [8–10], and comparatively high cost of buying conventional medicines and/or accessing contemporary healthcare facilities [11] also play a role. Others include the ever increasing production of herbal supplements and their subsequent sales ''over-the-counter'', retailing of herbal supplements as ''health foods'' and not ''pharmaceuticals'' which promotes self-prescription and abuse of such supplements [5], as well as uncensored and/or unrestricted super-benefit advertisements of natural products over conventional medicines [12].

Ocimum gratissimum, commonly referred to as 'scent leaves', and also known as Ramtulsi in Hindi, Bengali, and Gujrati; Fever leaf in English; Banjere in Punjabi; Rama tulsi in Malyalam; Elumicham tulasi in Tamil; Nimma tulsi in Kannad [13], is a shrub of the Lamicaea family of plants [14], genus *Ocimum* and species gratissimum [15] which is native to Central Africa and Southeast Asia [16] but cultivated in Nigeria, Southern American and Asian countries [13], is one of the common herbs consumed in many part of the world because of its palatability and claimed medicinal benefits. It is known locally in Nigeria as Daidoya, Efinrin and Nchoanwu among the Hausa, Yoruba and Ibo ethnic groups respectively [17] and employed locally as component in herbal preparations [18]. It is a major condiment in local delicacies in many African and South American countries [19], Thailand [15] and Northeast Brazil [18,20].

It is employed in the management of common cold, dermatologic diseases, lower respiratory tract infection, high grade pyrexia, headache, diarrhoea [21,22] and neonatal umbilical cord care [18,23]. It is

E-mail addresses: anoka.an@unilorin.edu.ng (A.A. Njan), gokeolaoye@gmail.com (S.O. Olaoye), afolabi023@yahoo.com (S.O. Afolabi), ejimsbenjamin@gmail.com (B.C. Ejimkonye), sojemakafan@gmail.com (A. Soje), asooeo@yahoo.co.uk (O.E. Olorundare), eoiwalewa@yahoo.com (E.O. Iwalewa).

https://doi.org/10.1016/j.toxrep.2019.04.009
Received 5 January 2019; Received in revised form 16 April 2019; Accepted 28 April 2019
Available online 01 June 2019
2214-7500/ © 2019 Published by Elsevier B.V. This is an open access article under the CC BY-NC-ND license (http://creativecommons.org/licenses/BY-NC-ND/4.0/).

also a treatment preference for upper respiratory tract infection, rectal prolapse, menstruation related problems, abdominal pains, conjunctivitis, seizures and febrile conditions in some African countries [24]. It is used, in India, to treat excessive sweating, sunstroke, some respiratory illnesses and has been reported to possess anti-inflammatory, antiparasitic, cytotoxic and analgesic potentials [20] while essential oils from its leaf is integrated into some antiseptic lotions employed in the treatment of some skin conditions [15,25].

Despite the natural state of many medicinal plants, available clinical information has associated many organ and systemic toxicities to their consumption [1,12,26]. *Ocimum gratissimum* has especially been investigated for several of these toxicities and, despite its promising clinical relevance, its ingestion has been linked with nephrotoxicity [23], hepatotoxicity following high dose of exposure [21] and male reproductive toxicities [19,27].

Interestingly, however, these toxicity studies focused on the crude extracts and essential oils from the *Ocimum gratissimum* leaves and there have been no documented studies that investigated the likely safety or otherwise of possible fractions from the crude leaf extracts.

The male reproductive system is a complex and delicate regulated process that can be disturbed adversely following exposure to exogenous environmental compounds – an entity known as reproductive toxicity [28]. In addition to genetic flaws, it is thought that most of male reproductive anomalies depend on exogenous toxic exposures, the so called Testicular Dysgenesis Syndrome [29].

In view of the widespread use of *O. gratissimum*, its possession of bioactive compounds capable of interfering with fertility, and the lack of reproductive toxicity studies in males on possible fractions of its extract; this study aimed at exploring the possible toxic effects of ethyl acetate and butanolic fractions of the crude methanolic leaf extract of *O. gratissimum* on the male reproductive system of rats.

2. Materials and methods

2.1. Experimental animals

Male Swiss mice (average weight of 26 g) and Male Wistar Albino rats, (weighing 150–200 g), were used for the acute and subchronic study respectively, animals were procured from a private commercial animal farm in Ogbomosho, Oyo state, Nigeria. Animals were kept in well aerated cages where bedding was replaced each day, at a room temperature of about 26–27 °C and 12 h light/dark cycle. They were allowed to adapt for two weeks preceding to experimentation. During this period, they were all provided with the same Standard commercially available rat pellets (Manufactured by Crown Flour Mill Limited, Nigeria) and tap water *ad libitum*. The Institutional Animal Research Ethics Committee reviewed and certified the experimental protocol UERC/ASN/2018/1474 in conformity with guidelines that are in compliance with National and International Laws and Guidelines for Care and Use of Laboratory Animals in Biomedical Research. Strict adherence to the Ethical Committee's directives was observed. Efforts were made to reduce suffering by the animals. The criterion of anaesthesia was the absence of body or limb movement in response to a standardised tail clamping stimulus.

2.2. Plant material and extraction

Fresh plants of *Ocimum gratissimum* were harvested at Awuyan village in Moro local government of Kwara state. The plant was identified and authenticated at the Department of Plant Biology, University of Ilorin and a vouchered specimen of the plant with reference number UILH/001/1319 was then dropped at the herbarium.

Leaves from the plants were shredded off the stem, washed with clean water and air dried at room temperature until a constant weight was attained. The dried leaves were crushed to fine powder using mechanical grinder. 8 kg of the fine powder was macerated in 16 litres of 99.9% methanol in a clean, airtight container for 7 days with occasional shaking. The mixture was filtered through a park of fresh clean cotton wool followed by Whatmann number 1 filter paper (Cat no 1002 150) to acquire a brownish green filtrate. The procedure was repeated for the left over residue. The filtrate was concentrated in vacuo at 40 °C using a rotary evaporator (model: RV10 Basic S9, batch number 07.249711, manufactured by IKA laboratory equipment USA) to obtain an oily brownish-green jelly-like extract.

2.3. Extract fractionation

The extract was fractionated by solvent-solvent partitioning using Kupchan method as described by [30] with modification in solvent types and volumes. A solution of the extract was made with 150 mls of methanol to which 250mls of distilled water was added to give an aqueous-methanolic solution which transferred into a 2 L separating funnel. 900mls of n-hexane was added and the mixture was vigorously agitated, left to stand for 4 h to obtain two clearly separated layers. The lower aqueous layer was gently drained into a clean container while the upper n-hexane fraction was drained into another container. The procedure was repeated with further addition of n-hexane to the aqueous fraction until the upper layer was clear. The process was subsequently repeated with the aqueous fraction using ethyl acetate and butanol to obtain the ethyl acetate and the butanolic fractions respectively. The left over aqueous residue was kept in a clean container at the end of the whole process. Individual fraction obtained was concentrated in vacuo at 40 °C using the rotary evaporator stated above. The concentrated fractions were further freeze dried using a freeze drier (LTE LYOTRAP. LTE Scientific Ltd, Greenfield, Old Ham. OL3 TEN) and stored at 4 °C until needed. The ethyl acetate and butanolic fractions were used for this experiment.

2.4. Acute toxicity test

Acute toxicity study was conducted using the method [31] as described [32]. 12 male Swiss albino mice (average weight of 26 g) were used in the study (in two phases) for each fraction. In phase one of the study, 9 animals were randomly distributed into three groups of 3 animals each to which 10, 100 and 100 mg/kg bodyweight doses of the fraction were administered intraperitoneally respectively. They were observed closely half hourly for the first 4 h, then hourly for the next 20 h for signs of toxicity and mortality. There was no mortality in the Phase 1 study thereby necessitating a phase 2 study. In phase 2, one animal was each treated with 1600, 2900 and 5000 mg/kg bodyweight doses of the fraction respectively. The animals were also closely observed half-hourly for the first 4 h, hourly for 20 h. There was mortality at the 2900 mg/kg and 5000 mg/kg body weight dose within 24 h for the butanolic and ethyl acetate fraction respectively. All surviving experimental animals were observed for a total of 14 days. The LD_{50} was calculated with the second phase using the formula $LD_{50} = \sqrt{(D0.D100)}$; where D_0 and D_{100} represent the maximum dose at which no mortality and the minimum dose at which mortality occurred respectively. Other observed signs of toxicity were noted.

2.5. Reproductive toxicity studies

For the sub-chronic reproductive toxicity study of each fraction, 21 Adult male rats weighing between 150 and 200 g were randomly divided into 3 groups of 7 animals each and were treated daily with 25, 100 and 400 mg/kg body weight doses of the respective fraction while another group of 7 animals (control) received 1 ml of normal saline (the vehicle of administration) daily for 28 days. At the end of the experimental phase, all animals were fasted overnight and thereafter euthanized by halothane anaesthesia. After euthanasia, Blood was collected by cardiac puncture for serum reproductive hormone assay and the animals underwent laparotomy for removal and weighing of the

right epididymis, seminal vesicles, and testes. The organs were freed of adjacent fat and their absolute weight was measured in analytical balance (A&D, HR-120, Tokyo, Japan) followed by the determination of the respective relative weights (organ weight per 100 g of body weight). The organs were also examined macroscopically for assessment of changes in the appearance, size, color, and shape.

2.5.1. Gonadosomatic index

Gonadosomatic index for each animal was calculated by expressing the weight of the right testis over the pre-sacrifice body weight as a percentage as described by Parandin and Rohani, 2010. Gonadosomatic index (GSI) = [gonad weight / total tissue weight] × 100%.

2.5.2. Sperm count

Sperms were collected from the epididymal secretion in the left epididymis cauda. The secretion was placed in a 0.5 mL drop of saline solution and diluted in 20 mL distilled water. From this homogenate, a sample was taken and the number of sperm counted using a hemocytometer with improved double Neubauer ruling. The total number of spermatozoa was obtained by averaging two counts, corresponding to the upper and lower field in the Neubauer chamber (23. Moraes GES, 24. Rocha AOB)

2.5.3. Sperm motility

A drop of the semen specimen was placed on a glass slide, mixed with three drops of normal saline at room temperature and examined under a light microscope. The number of motile and non-motile spermatozoa were counted. The percentage motility was calculated by expressing the number of motile sperm over the total sperm counted as a percentage as described [33].

2.5.4. Live sperm percentage

A drop of the semen specimen was placed on a glass slide, mixed with a drop of 0.5% eosin solution at room temperature and examined under a light microscope to count the number of live (unstained) and dead (stained red) spermatozoa as described [33]. The live sperm percentage was calculated by expressing the number of live sperm divided by total sperm counted as a percentage.

2.5.5. Serum hormonal assay

Blood samples, obtained by cardiac puncture, were allowed to clot in plain bottles and centrifuged at 4000 rpm for 10 min using a centrifuge (800D manufactured by TOBITEK Allied Industries). Serum was subsequently harvested for testosterone, follicle stimulating hormone and luteinising hormone assays. Serum samples and ELISA hormone standards were prepared in standard ELISA microwells (Designed and manufactured by Monobind Inc., USA) following instructions in the ELISA kit operational Manual. The absorbance were read with ELISA machine (Rayto RT-2100C microplate reader). Serum hormonal assay were obtained from a plotted graph of absorbance versus concentration of hormone standards.

2.5.6. Testicular histology

The left testes were fixed for three days in 10% formalin and later dehydrated with different grades of ethanol, cleared in xylene and immersed in paraffin wax for sectioning. 5 µm slices of the testicular tissue were cut, mounted on glass slides, and stained for light microscopy with haematoxylin and eosin dye as described [34]. Slides were observed at x40 and x400 magnification and picture micrographs were taken.

2.6. Data presentation and statistical analysis

Data were presented in tables and line graphs as Mean + Standard Error of Mean. Results were analysed with graph pad Instat software (Version 6.01) using one way analysis of variance (ANOVA) followed by Dunnets post hoc test for comparisons of different means and P value was set at $P < 0.05$ [35].

Table 1
Acute toxicity test of butanolic and ethyl acetate fraction of methanolic leaf extract of *Ocimum gratissimum*.

1A			
BUTANOL FRACTION			
Phase	Fraction dose (mg/kg)	Log dose	No. of death
1	10	1	0/3
	100	2	0/3
	100	3	0/3
2	1600	3.2	0/1
	2900	3.4	1/1
	5000	3.4	1/1
LD50 = 2154.1mg/kg			

1B			
ETHYL ACETATE FRACTION			
Phase	Fraction dose (mg/kg)	Log dose	No. of death
1	10	1	0/3
	100	2	0/3
	100	3	0/3
2	1600	3.2	0/1
	2900	3.4	0/1
	5000	3.4	1/1
LD50 = 3807.9mg/kg			

Number of animals used/ fraction: Phase 1 (n_1) = 9,Phase 2 (n_2) = 3, Total ($n_1 + n_2$) = 12.
Number of animals used/ fraction: Phase 1 (n_1) = 9,Phase 2 (n_2) = 3, Total ($n_1 + n_2$) = 12.
*Dose at which mortality was recorded.

3. Results

The percentage yield of the methanolic leaves extract of *Ocimum gratissimum* was 10.94%.

The LD_{50} of the butanolic and ethyl acetate fraction from the methanolic leaf extract of Ocimum *gratissimum* were 2154.1 mg/kg and 3807.9 mg/kg respectively (Table 1). Dose dependent dizziness and sedation were observed in the animals during phase 2 test of both fractions.

Both fractions caused significant increase in serum testosterone levels and significant decrease in serum levels of luteinising hormone (Table 2). Both fractions caused significant gain in body weight (Fig. 1) which was not dose dependent with respect to the butanolic fraction. Both fractions also caused significant and dose dependent increase in sperm count when compared to control (Fig. 2).There was significant increase in sperm motility at the 25 mg/kg dose of ethyl acetate fraction compared to control (Fig. 3). There was no significant changes in live sperm percentage (Fig. 4) and sperm morphology (Fig. 5). There was apparent increases in epididymis weights (Fig. 6) testicular weight (Fig. 7) and gonadosomatic index remained unchanged (Fig. 8). Testicular histoarchitecture was preserved and despite gain in testicular weight, there were no signs of inflammation of the testes of animals treated with both fractions compared to control (Fig. 9a–f).

4. Discussion

This study investigated the sub-chronic effects of oral administration of butanolic and ethyl acetate fractions from methanolic leaf extract of *Ocimum gratissimum* on reproductive hormones, sperm parameters and testicular histology as indices for fertility in male Wistar rats. The percentage yield of the methanolic extract of *Ocimum*

Table 2
Effect of butanolic and ethyl acetate fraction of methanolic extract of *Ocimum gratissimum* leaves on serum hormonal levels.

HORMONE	Control	25 mg/kg	100 mg/kg	400 mg/kg
FSH(mIU/ml)				
Butanolic	2.39 ± 0.12	2.25 ± 0.12	2.42 ± 0.12	2.43 ± 0.08
Ethyl Acetate	2.39 ± 0.12	2.14 ± 0.12	2.17 ± 0.68	2.15 ± 0.04
LH (mIU/ml)				
Butanolic	4.94 ± 0.07	5.17 ± 0.25**	4.03 ± 0.12**	3.84 ± 0.20***
Ethyl Acetate	4.94 ± 0.07	3.33 ± 0.12**	3.45 ± 0.12**	1.96 ± 0.09***
TEST (ng/ml)				
Butanolic	0.14 ± 0.01	0.50 ± 0.01**	0.24 ± 0.01****	0.70 ± 0.02****
Ethyl Acetate	0.14 ± 0.01	0.18 ± 0.01**	0.16 ± 0.01	0.23 ± 0.01****

Data are given as mean ± S.E.M. Data were analyzed by ANOVA followed by Dunnet's test. n = 7; * $p \leq 0.05$; * * $p \leq 0.01$; * * * $p \leq 0.001$; **** $P \leq 0.0001$ is significant vs control.

gratissimum was determined to be 10.94 percent in contrast to 8.88 percent and 9.60 percent earlier reported [13] and [36] respectively, and this increase might be as a result of the dual maceration technique employed for the leaf extraction.

The assessment of body weight during treatment with a definite compound offers information on the overall health of the animals. A decrease of body mass or a diminution in weight gain may indicate varied responses, including systemic treatment-induced toxicity [37,38]. Both fractions of *Ocimum gratissimum* did not change the Rohrer's Index development of treated animals, (Fig. 1) signifying lack of systemic toxic effect. There were no clinical signs of toxicity and deaths during the experimental procedure.

A standard serum testosterone hormone level is critical in maintaining the anatomical properties and physiological roles of the male reproductive organ [39]. The synthesis and secretion of this hormone by the Leydig cells is governed by Luteinizing hormone release by the anterior pituitary gland, while (testosterone) via a negative feedback mechanism, also regulates the release of luteinising hormone [40].

However, this can be disrupted by exposure to toxic compounds which may be present in the environs either via ingestion, inhalation or transdermal absorption leading to modification in the endocrine function of the testis. In this study, both the ethyl acetate and the butanolic fractions of the methanolic leaf extract of *Ocimum gratissimum* caused elevated serum testosterone levels (Table 2) ($P < 0.0001$).

Previous studies on the crude extract of *Ocimum gratissimum* have linked its male reproductive toxicity effects to its oxidative constituents such as triterpenes and saponins [19]. However, its phenolics constituents such as flavonoids have been reported to possess great free radical scavenging property and therefore responsible for most of its antioxidant effects [41]. These phenolics have also been reported to be highest in the ethyl acetate fraction of the crude methanolic extract [42]. They are principally important because, even at low concentrations, they retained their roles at scavenging free radicals that may accelerate oxidative cellular damage via membrane or tissue protein injury, degradation of vital cellular enzymes, carbohydrate metabolism imbalance and modification of the cells' genetic material [43]. The elevated serum testosterone observed in this study could have been due to a direct action of the fractions on the testicular tissue, scavenging oxidating radicals in the testicular tissues and consequently stabilising the cells of the testis and improving their growth, development and function.

Similarly both fractions of *Ocimum gratissimum* leaf extract might have direct stimulatory action on Leydig cells promoting the synthesis and secretion of testosterone leading to the observed elevated serum testosterone levels (Table 2) and successive decrease in serum luteinising hormone via a negative feedback mechanism. This findings is in contrast to that of Obianime and his colleaques [19] that found no significant change in the serum levels of testosterone in mice treated with doses of aqueous crude extract of *Ocimum gratissimum* as well as that of Parandin and Rohani [27] that reported a significant decrease in serum level of testosterone in rats treated with 300 mg/kg bodyweight dose of the essential oil of *Ocimum gratissimum.*

Both fractions caused significant increase in sperm count in the treated animals (Fig. 2) and this was also observed to be more

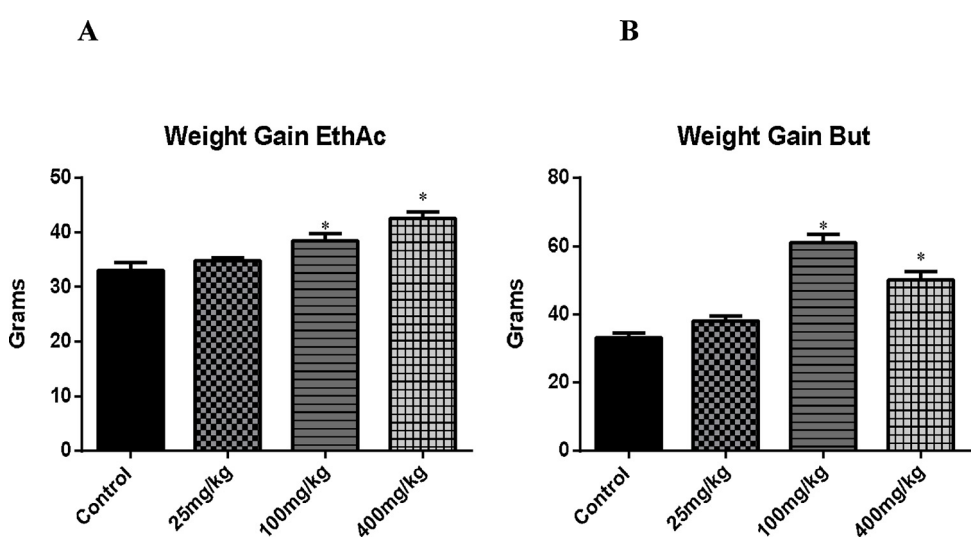

Fig. 1. A. Effect of ethyl acetate fraction of methanolic extract of *ocimum gratissimum* leaves on body weight gain. B. Effect of ethyl acetate fraction of methanolic extract of *ocimum gratissimum* leaves on body weight gain.
Data are given as mean ± S.E.M. Data were analyzed by ANOVA followed by Dunnet's test. n = 7; * $p \leq 0.05$; * * $p \leq 0.01$; * * * $p \leq 0.001$ is significant vs control.

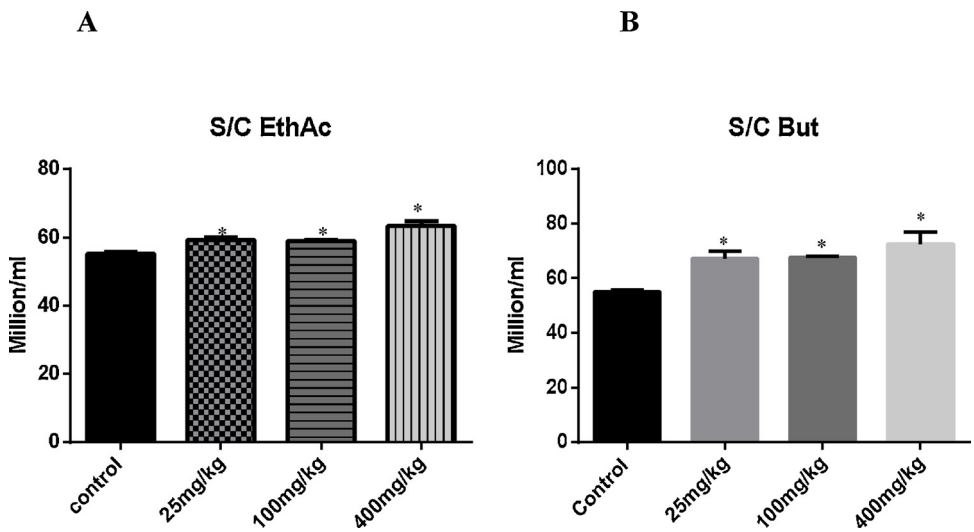

Fig. 2. A. Effect of ethyl acetate fraction of methanolic extract of *Ocimum gratissimum* leaves on the sperm count. B. Effect of butanolic fraction of methanolic extract of *Ocimum gratissimum* leaves on the sperm count.
Data are given as mean ± S.E.M. Data were analyzed by ANOVA followed by Dunnet's test. n = 7; ∗ p ≤ 0.05; ∗∗ p ≤ 0.01; ∗∗∗ p ≤ 0.001 is significant vs control.

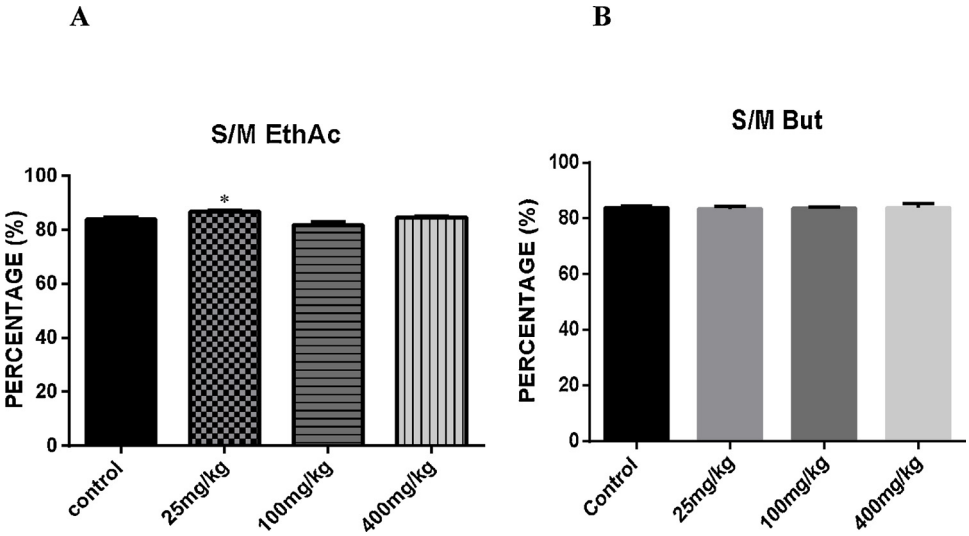

Fig. 3. A. Effect of ethyl acetate fraction of methanolic extract of *ocimum gratissimum* leaves on the percentage sperm motility. B. Effect of butanolic fraction of methanolic extract of *ocimum gratissimum* leaves on the percentage sperm motility.
Data are given as mean ± S.E.M. Data were analyzed by ANOVA followed by Dunnet's test. n = 7; ∗ p ≤ 0.05; ∗∗ p ≤ 0.01; ∗∗∗ p ≤ 0.001 is significant vs control.

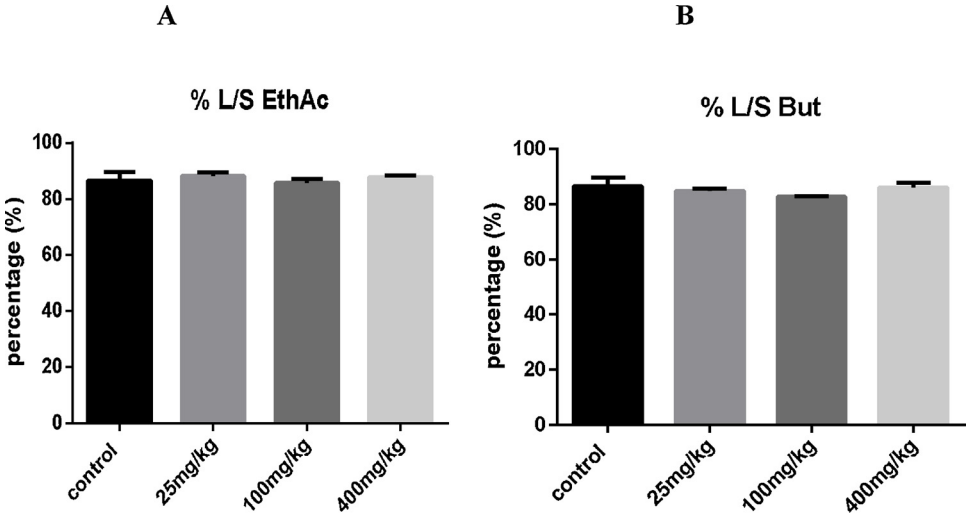

Fig. 4. A Effect of ethyl acetate fraction of methanolic extract of *ocimum gratissimum* leaves on the percentage sperm viability. B Effect of butanolic fraction of methanolic extract of *ocimum gratissimum* leaves on the percentage sperm viability.
Data are given as mean ± S.E.M. Data were analyzed by ANOVA followed by Dunnet's test. n = 7; ∗ p ≤ 0.05; ∗∗ p ≤ 0.01; ∗∗∗ p ≤ 0.001 is significant vs control.

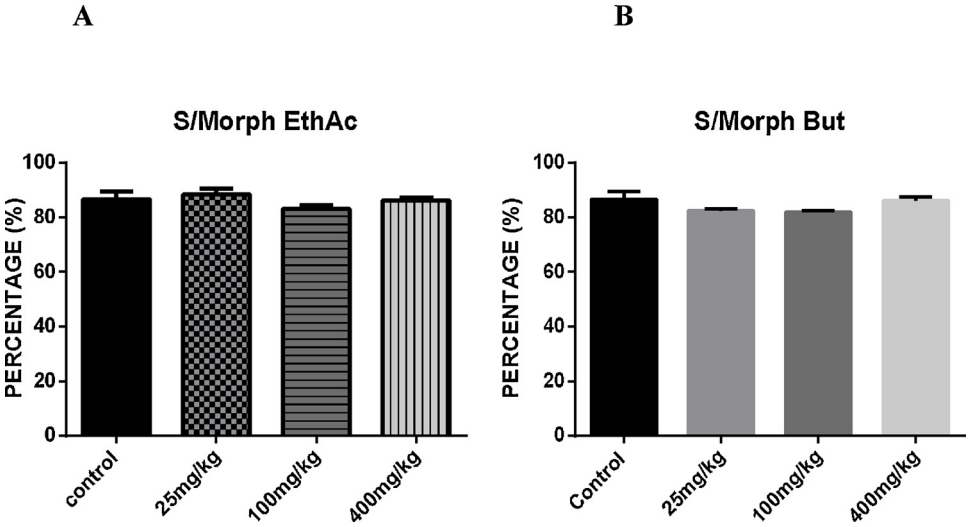

Fig. 5. A. Effect of ethyl acetate fraction of methanolic extract of *ocimum gratissimum* leaves on the percentage sperm Morphology. B. Effect of butanolic fraction of methanolic extract of *ocimum gratissimum* leaves on the percentage sperm Morphology.
Data are given as mean ± S.E.M. Data were analyzed by ANOVA followed by Dunnet's test. n = 7; ∗ p ≤ 0.05; ∗∗ p ≤ 0.01; ∗∗∗ p ≤ 0.001 is significant vs control.

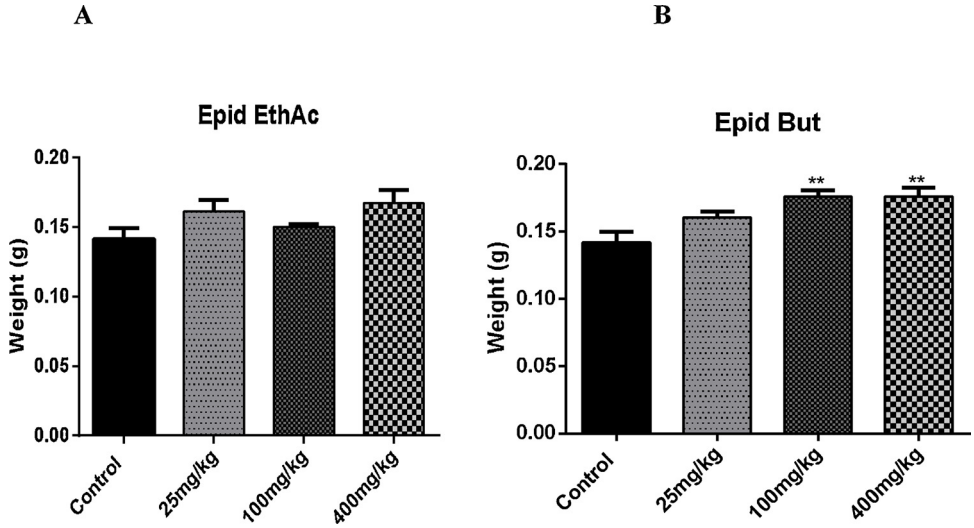

Fig. 6. A. Effect of ethyl acetate fraction of methanolic extract of *Ocimum gratissimum* leaves on weight of epididymis. B. Effect of butanolic fraction of methanolic extract of *Ocimum gratissimum* leaves on weight of epididymis.
Data are given as mean ± S.E.M. Data were analyzed by ANOVA followed by Dunnet's test. n = 7; ∗ p ≤ 0.05; ∗∗ p ≤ 0.01; ∗∗∗ p ≤ 0.001 is significant vs control.

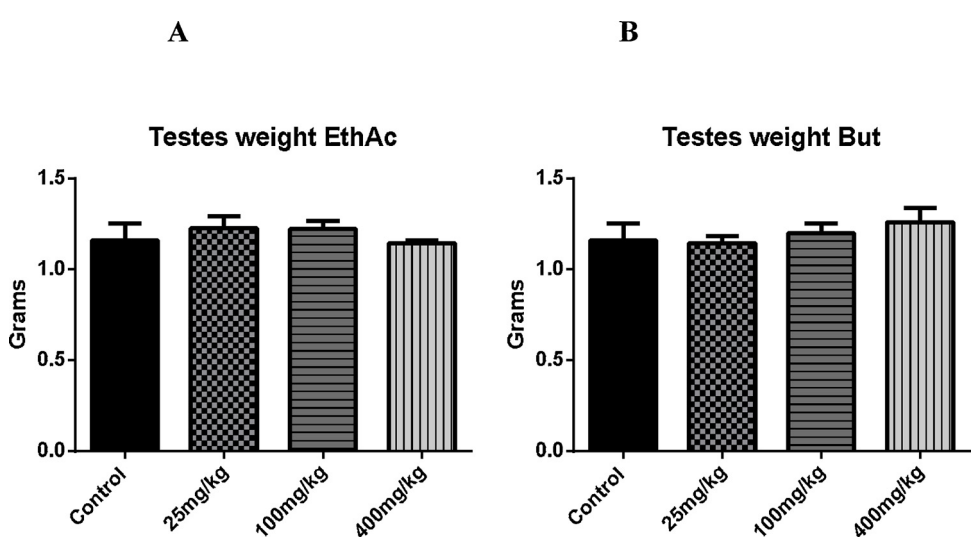

Fig. 7. A. Effect of ethyl acetate fraction of methanolic extract of *ocimum gratissimum* leaves on testicular weight. B. Effect of butanolic fraction of methanolic extract of *ocimum gratissimum* leaves on testicular weight.
Data are given as mean ± S.E.M. Data were analyzed by ANOVA followed by Dunnet's test. n = 7; ∗ p ≤ 0.05; ∗∗ p ≤ 0.01; ∗∗∗ p ≤ 0.001 is significant vs control.

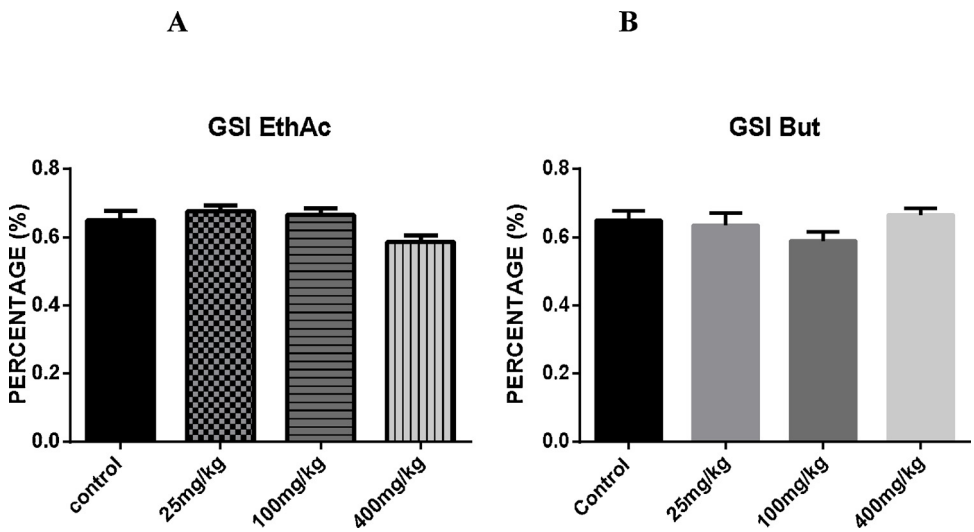

Fig. 8. A. Effect of ethyl acetate fraction of methanolic extract of *ocimum gratissimum* leaves on gonadosomatic index. B. Effect of butanolic fraction of methanolic extract of *ocimum gratissimum* leaves on gonadosomatic index.
Data are given as mean ± S.E.M. Data were analyzed by ANOVA followed by Dunnet's test. n = 7; ∗ p ≤ 0.05; ∗∗ p ≤ 0.01; ∗∗∗ p ≤ 0.001 is significant vs control.

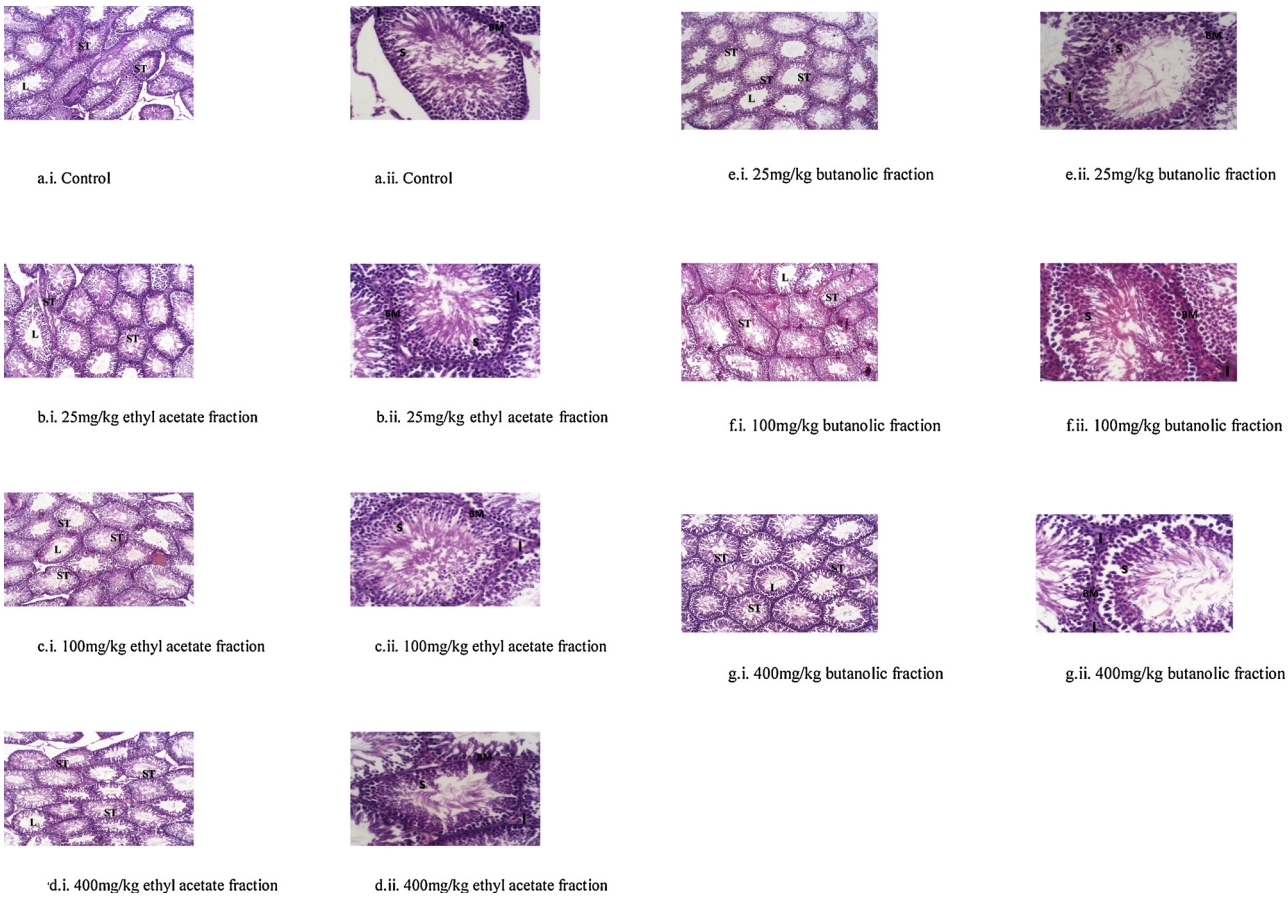

Fig. 9. Photomicrographs showing the effects of ethylacetate (9b–d). Photomicrographs showing the effects of butanolic fractions (9e–g). Photomicrographs showing the effects of ethylacetate (9b–d) and butanolic fractions (9e–g) of methanolic extract of *ocimum gratissimum* leaves on testicular histology. Haematoxylin and Eosin staining, Left column (i) x40; Right column (ii) x400. ST = Seminiferous tubule; L = Lumen; I = Interstitium, BM = Basement membrane; S = Spermatozoon.

pronounced with the butanolic fraction. Again, this finding contrasts [19] and [27] that reported significant decrease in sperm number in mice treated with crude aqueous extract of *Ocimum gratissimum* and rats treated with the essential oil from *Ocimum gratissimum* leaves respectively. The ethyl acetate fraction also caused a significant increase in the percentage sperm motility (Fig. 3) in the 25 mg/kg treated group, this can also result from the increase activity of testosterone in enhancing the functioning of the epididymis, an accessory organ of reproduction within which sperm develops to full maturation. The enhanced motility of the spermatozoa might also be as a result of enhanced membrane equilibrium of the cells at their various phases of succession as substances with anti-oxidant properties are known to offer

improved membrane stabilisation to cells. The apparent and significantly increase weight of the epidydimis (Fig. 6) in the ethyl acetate and butanolic fraction treated groups can be linked to the anabolic effect of testosterone particularly its role in aiding the growth and development of other accessory sexual organs. There was no change in the absolute testicular weight (gonadosomatic index) (Fig. 8) across the groups treated with both fractions suggesting that the integrity of the testis were preserved in both groups.

Histopathology is one of the tools also used to predict testicular dysfunction [44], this study shows that the histoarchitecture of the testes across the groups treated with ethyl acetate and the butanolic fractions was preserved (Fig. 9a–g) and there was no sign of inflammatory signs notwithstanding the increment in weight of the testes at autopsy, an indication that the fractions caused an enhancement in the normal functioning of the testes

5. Conclusion

We conclude from our findings that the ethyl acetate fraction is more acutely tolerable than the butanolic fraction though both fractions were not toxic with regards to male reproduction at the investigated doses but rather exhibited fertility enhancing properties especially with the preservation of the testicular histoarchitecture and increasing sperm count as indices for male fertility.

Ethical consideration

The experimental procedure was carried out in conformity with the rules guiding animal handling and care in biomedical researches and ethical clearance was obtained from the university of Ilorin ethical review committee.

Conflict of interest

The authors declare no conflict of interest.

Acknowledgements

We appreciate Prof Abraham Ibiyemi for given us unrestricted access to his laboratory where plant extraction and fraction work was executed. We equally appreciate the technical input of Dr Biliaminu of the Department of Chemical Pathology of the University of Ilorin in the serum hormonal analysis.

References

[1] K.G. Choi, Neurotoxicity of herbal medicine, J. Korean Med. Assoc. 48 (4) (2005) 308–317.
[2] K. Subramanian, D. Sankaramourthy, M. Gunasekaran, Toxicity studies related to medicinal plants, Nat. Prod. Drug Discov. (2018) 491–505, https://doi.org/10.1016/B978-0-08-102081-4.00018-6 Chapter 18.
[3] N.E. Thomford, K. Dzobo, D. Chopera, A. Wonkam, M. Skelton, D. Blackhurst, S. Chirikure, C. Dandara, Pharmacogenomics implications of using herbal medicinal plants on african populations in health transition, Pharmaceuticals 8 (3) (2015) 637–663.
[4] S.W. Tang, W. Tang, B.E. Leonard, Patients on psychotropic medications and herbal supplement combinations: clinical considerations, Int. Clin. Psycopharmacol. 32 (2) (2017) 63–71.
[5] H. Rahman, M. Kim, G. Leung, J.A. Green, S. Katz, Drug-herb interactions in the elderly patient with IBD: a growing concern, Curr. Treat. Options Gastroenterol. 15 (4) (2017) 618–636.
[6] H. Nasir, H. Shirzad, Toxicity and safety of medicinal plants, J. Herb. Med. Pharmacol. 2 (2) (2013) 21–22.
[7] A. Karimi, M. Majlesi, M. Rafieian-Kopaei, Herbal VERSUS synthetic drugs; beliefs and facts, J. Nephropharmacol. 4 (1) (2015) 27–30.
[8] S. Wachtel-Galor, I.F.F. Benzie, I.F.F. Benzie, S. Wachtel-Galor (Eds.), Herbal Medicine: An Introduction to its History, Usage, Regulation, Current Trends, and Research Needs. Herbal Medicine: Biomolecular and Clinical Aspects (Online), 2nd edition, CRC Press/Taylor & Francis, Boca Raton (FL), 2011Chapter 1..
[9] N.P. Singh, A. Prakash, Nephrotoxic potential of herbal drugs, J. Int. Med. Sci. Assoc. 24 (2) (2011) 79–81.
[10] C. Liu, H. Fan, Y. Li, X. Xiao, Research advances on hepatotoxicity of herbal medicines in China, Comput. Biomed. Res. 7150391 (2016) 14, https://doi.org/10.1155/2016/7150391.
[11] E.K. Mpinga, T. Kandolo, H. Verloo, B. Zacharie, N. Kandala, P. Chastonay, Traditional/alternative medicines and the right to health: key elements for a convention on global health, Health Hum. Right J. 15 (1) (2013) E44–45.
[12] E.M. Alissa, Medicinal herbs and therapeutic drugs interactions, Ther. Drug Monit. 36 (4) (2014) 413–422.
[13] V.K. Gupta, J. Singh, R. Kumar, A. Bhanot, Pharmacognostic and preliminary phytochemical study of *Ocimum gratissimum*linn. (Family: Lamiaceae), Asian J. Plant Sci. 10 (7) (2011) 365–369.
[14] E.V. Ugonna, Effects of *Ocimum gratissimum* and *gongronema latifolium* on fertility parameters, a case for bi-herbal formulations, Stand. Res. J. Med. Plants 1 (1) (2013) 1–5.
[15] E.I. Nweze, E.E. Eze, Justification for the use of *Ocimum gratissimum* L in herbal medicine and its interaction with disc antibiotics, BMC Complement. Altern. Med. 9 (2009) 37, https://doi.org/10.1186/1472-6882-9-37.
[16] O.E. Ofem, E.J. Ani, A.E. Eno, Effects of aqueous leaves extract of *Ocimum gratissimum* on haematological parameters in rats, Int. J. Appl. Basic Med. Res. 2 (1) (2012) 38–42.
[17] C. Mbakwem-Aniebo, O. Onianwa, I.O. Okonko, Effects of *Ocimum gratissimum* leaves on common dermatophytes and causative agent of *Pityriasis versicolor* in rivers state, Nigeria, J. Microbiol. Res. 2 (4) (2012) 108–113.
[18] D.J. Ogundipe, R.O. Akomolafe, A.A. Sanusi, E.C. Imafidon, O.S. Olukiran, A.A. Oladele, Effects of two weeks administration of *Ocimum gratissimum* leaf on feeding pattern and markers of renal function in rats treated with gentamicin, Egypt. J. Basic Appl. Sci. 3 (3) (2016) 219–231.
[19] A.W. Obianime, J.S. Aprioku, C.T.O. Esomonu, Antifertility effects of aqueous crude extract of *Ocimum gratissimum* L. leaves in male mice, J. Med. Plant Res. 4 (9) (2010) 809–816.
[20] K.S. Prabhu, R. Lobo, A.A. Shirwaikar, A. Shirwaikar, *Ocimum gratissimum*: a review of its chemical, pharmacological and ethnomedicinal properties, Open Complement. Med. J. 1 (2009) 1–15.
[21] A.Y. Onaolapo, O.J. Onaolapo, *Ocimum gratissimum* linn causes dose dependent hepatotoxicity in streptozotocin-induced diabetes wistar rats, Macedonia J. Med. Sci. 5 (1) (2012) 17–25.
[22] O.T. Adedosu, J.A. Badmus, O.K. Afolabi, O.F. Yakubu, Effect of methanolic leaf extract of *Ocimum gratissimum* (Linn) leaves on sodium arsenite-induced toxicity in rats, J. Pharmacol. Toxicol. 7 (5) (2012) 259–266.
[23] O.A. Ebeye, O.V. Ekundina, I.E. Wilkie, Histological and biochemical effects of aqueous extract of *Ocimum gratissimum* on the liver and kidney of adult wistar rats, Afr. J. Cell. Pathol. 2 (4) (2014) 59–64.
[24] L.G. Matasyoh, J.C. Matasyoh, F.N. Wachira, M.G. Kinyua, T.A.W. Muigai, T.K. Mukiama, Chemical composition and antimicrobial activity of the essential oil of *Ocimum gratissimum* L. growing in Eastern Kenya, Afr. J. Biotechnol. 6 (6) (2007) 760–765.
[25] L.O. Orafiya, A.O. Oyedele, A.O. Shittu, A.A. Elujoba, The formulation of an effective topical antibacterial product containing *Ocimum gratisssimum* leaf essential oil, Int. J. Pharmacol. 224 (1-2) (2001) 177–183.
[26] A.A. Izzo, Interactions between herbs and conventional drugs: overview of the clinical data, Med. Princ. Pract. 21 (5) (2012) 404–428.
[27] R. Paradin, S.A.H. Rohani, Effect of the oil extract of *Ocimum gratissimum* leaves on the reproductive function and fertility in adult male rats, J. Appl. Biol. Sci. 4 (2) (2010) 1–4.
[28] O.A. Ayoka, O.E. Ojo, E.C. Imafidon, K.A. Ademoye, A.A. Oladele, Neuro-endocrine effects of aqueous extract of *Amaranthus virdis* (linn.) leaf in male Wistar rat model of cyclophosphamide-induced reproductive toxicity, Toxicol. Rep. 3 (2016) 608–619.
[29] N.E. Shakkebaek, E. Rajpert-De Meyts, K.M. Main, Testicular dysgenesis syndrome: an increasingly common developmental disorder with environmental aspects, Hum. Reprod. 16 (2001) 972–978.
[30] M.A. Muhit, S.M. Tareq, A.S. Apu, D. Basak, M.S. Islam, Isolation and identification of compounds from the leaf extract of *Dillenia indica* Linn, Bangladesh Pharm. J. 13 (1) (2010) 0301–4606.
[31] D. Lorke, A new approach to practical acute toxicity testing, Arch. Toxicol. 54 (1982) 275–287.
[32] E. Chinedu, D. Arome, F.S. Ameh, A new method for determining acute toxicity in animal models, Toxicol. Int. 20 (3) (2013) 224–226.
[33] A.O. Oyewopo, S.K. Olaniyi, C.I. Oyewopo, A.T. Jimoh, Cell phone alters oxidative status and impairs testicular function of male wistar rats, J. Reprod. Endocrinol. Infertil. 2 (1) (2017) 22, https://doi.org/10.21767/2476-2008.100022.
[34] S. Parhizkar, S.B. Zulkifli, M.A. Dollah, Testicular morphology of male rats exposed to *Phaleria macrocarpa* (Mahkota dewa) aqueous extract, Iran J. Basic Med. Sci. 17 (5) (2014) 384–390.
[35] B.K. Mahajan, B.K. Mahajan (Ed.), Significance of Difference in Means. Methods in Biostatistics for Medical and Research Workers, JAYPEE Brothers Medical Publishers, 1997, pp. 117–141 Chapter 9.
[36] K.O. Awojide, M.E. Haliu, L.G. Hassan, C.J. Ugwah-Oguejiofor, Phytochemical screening and evaluation of anti-inflammatory activity of ethyl acetate leaves extract from *Ocimum gratissimum* (L.), J. Dent. Med. Sci. 15 (2) (2016) 16–22.
[37] R.C.S. Sá, M.N. Leite, M.M. Reporedo, R.N. Almeida, Evaluation of long-term exposure to Mikania glomerata (Sprengel) extract on male Wistar rats' reproductive organs, sperm production and testosterone level, Contraception (Stoneham) 67 (2003) 327–331.
[38] A.O.B. Rocha, J.C.L. Pita, K.M. Oliveira, C.A.X. Mota, E.C. Estevam, W.P. Viana, R.C.S. Sá, M.F.F.M. Diniz, Toxicological effect of hydroalcoholic extract of Pradosia

huberi Ducke in Wistar rats, Braz. J. Pharmacy 93 (2012) 371–378.
[39] P. Prathima, K. Venkaiah, R. Pavani, T. Daveedu, M. Munikumar, M. Gobinath, M. Valli, S.B Sainath. α-lipoic acid inhibits oxidative stress in testis and attenuates testicular toxicity in rats exposed to carbimazole during embryonic period, Toxicol. Rep. 4 (2017) 373–381.
[40] K. Sembuligam, P. Sembuligam. Male Reproductive System. Essentials of Medical Physiology. Sembuligam K. and Sembuligam P., sixth edition. © JayPee Brothers Medical Publishers. 455-466.
[41] A.C. Akinmoladun, E.O. Ibukun, E. Afor, E.M. Obuotor, E.O. Farombi, Phytochemical constituents and antioxidant activity of extract from the leaves of *Ocimum gratissimum*, Sci. Res. Essay 2 (5) (2007) 163–166.
[42] M.A. Ajayi, S. Umukoro, B. Ben-Azu, B. Adzu, O.G. Ademowo, Toxicity and protective effect of phenolic-enriched ethylacetate fraction of *Ocimum gratissimum* (Linn) leaf against acute inflammation and oxidative stress in rats, Drug Dev. Res. 78 (3–4) (2017) 135–145.
[43] L.G. Pieroni, F.M. de Rezende, V.F. Ximenes, A.L. Dokkedal, Antioxidant activity and total phenols from the methanolic extract of *Miconia albicans* (Sw.) triana leaves, Molecules 16 (11) (2011) 9439–9450.
[44] S. Campion, The current status of biomarkers for predicting toxicity, Expert Opin. Drug Metab. Toxicol. 9 (2013) 1391–1408.