[Downloaded free from http://www.nigeriamedj.com on Wednesday, April 10, 2013, IP: 82.128.53.90] || Click here to download free Android application for this journ

CASE REPORT

That dyspepsia in the young could be cancer

Abdulfatai B. Olokoba, Olusegun A. Obateru, Mathew O. Bojuwoye, Olatunde K. Ibrahim[1], Lateefat B. Olokoba[2]

Departments of Medicine, Gastroenterology Unit, [1]Pathology, [2]Ophthalmology, University of Ilorin Teaching Hospital, Ilorin, Nigeria

Address for correspondence:
Dr. Abdulfatai B. Olokoba,
Department of Medicine, University of Ilorin Teaching Hospital,
Ilorin, Kwara State, Nigeria.
E-mail: drabolokoba@yahoo.com

ABSTRACT

Malignant tumour of the stomach is not common in young adults. When it does occur, it is associated with a high morbidity and mortality. The objective of this report is to document our experience with three cases of gastric adenocarcinoma in young adult Nigerians seen over a period of 18 months in our centre.

Key words: Adenocarcinoma, endoscopy, gastric, young adults

INTRODUCTION

Worldwide, gastric cancer is one of the most common cancers in the gastro-intestinal (GI) tract, and it is the fourth most common cancer and the second leading cause of cancer-related death, with about 700 000 deaths annually.[1,2] Typically, the average age of patients who suffer from gastric cancer is approximately 60 years; on occasion, however, about 1-3% of gastric cancer cases occur in patients less than 30 years of age.[3-5] Gastric adenocarcinoma accounts for 95% of gastric malignancies.[3] Gastric cancer in younger individuals is associated with a much higher rate of morbidity and mortality.[6] The incidence of gastric cancer varies greatly across populations,[7] with the highest incidence reported in Japan.[2] Risk factors associated with gastric carcinoma include *Helicobacter pylori* (*H. pylori*) infection, low fat and protein diet, low intake of vitamins A and C, high intake of salted meat and fish, high intake of nitrates and a low socioeconomic status.[8,9] Upper GI endoscopy and biopsy remain the main stay of diagnosis. The clinico-pathological and endoscopic profiles of this group of patients are not well known. There is no previous endoscopic and histological report of gastric adenocarcinoma from Ilorin, Nigeria.

CASE REPORTS

Case I

A 34-year-old male civil servant presented with 6 months history of upper abdominal discomfort associated with recurrent vomiting of stale food residue, anorexia, early satiety and weight loss. He had no history of dysphagia, odynophagia or haematemesis. He had no history of ingestion of alcoholic beverages, smoked food or a family history of GI malignancy.

Physical examination revealed a chronically ill looking, pale young man, with no lymph node enlargement. Abdominal examination showed epigastric tenderness and succussion splash, but digital rectal examination was essentially normal.

Upper GI endoscopy findings revealed a distended stomach with a circumferential, firm, ulcerated mass with necrotic surface at the antrum obstructing the gastric outlet, and a deformed pyloric ring making it difficult to intubate the duodenum [Figure 1]. Histology of the biopsy specimen showed a moderately differentiated adenocarcinoma of the gastric mucosa with no evidence of *H. pylori* in the biopsy sample [Figure 2].

He was worked up and had a partial gastrectomy with Bilroth II drainage procedure, and was placed on anti-cancer chemotherapy – Irinotecan and 5-fluorouracil. His clinical condition improved initially but later deteriorated with worsening abdominal distention, ascites and pedal oedema. A second exploratory laparatomy done about 3 months later revealed disseminated disease with malignant ascites and bowel obstruction. He succumbed to the disease a few days later.

Case II

A 29-year-old male farmer presented with 4 months history of epigastric pain associated with recurrent vomiting, anorexia, early satiety and weight loss. He also had haematemesis and melaena. He had a history of ingestion of alcoholic beverages and ingestion of smoked food, there was no history of cigarette smoking and no family history of GI malignancy.

Physical examination revealed a chronically ill looking pale young man, but had no palpably enlarged peripheral lymph nodes. Abdominal examination revealed epigastric

Access this article online	
Quick Response Code:	Website: www.nigeriamedj.com
	DOI: 10.4103/0300-1652.110053

[Downloaded free from http://www.nigeriamedj.com on Wednesday, April 10, 2013, IP: 82.128.53.90] || Click here to download free Android application for this journ

tenderness, and a digital rectal examination revealed melaena stool. Upper GI endoscopy showed a dilated stomach with huge friable mass with necrotic surface, seen at the antral area of the stomach with distortion of the local anatomy [Figure 3]. Histological examination of the biopsy specimen showed a poorly differentiated

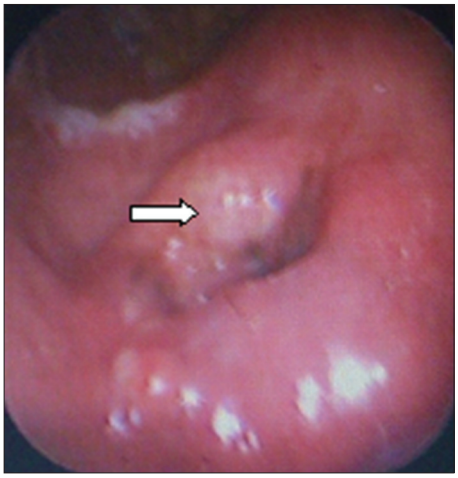

Figure 1: Huge friable mass at the antrum of the stomach (arrowed)

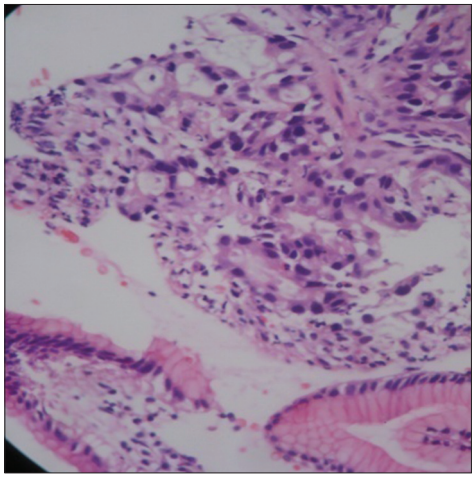

Figure 2: Histology of the biopsied mass showing moderately differentiated gastric adenocarcinoma, magnification ×400

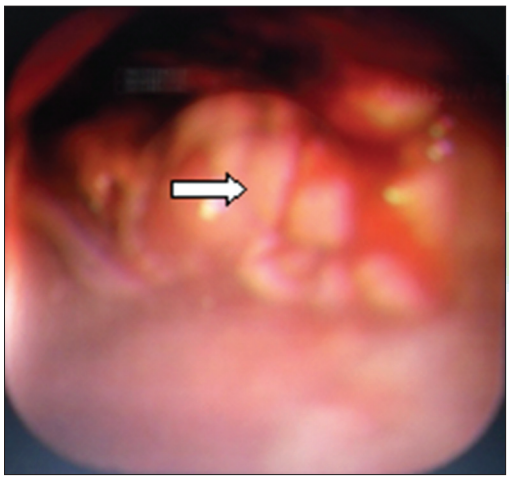

Figure 3: Huge friable mass at the antrum of the stomach (arrowed)

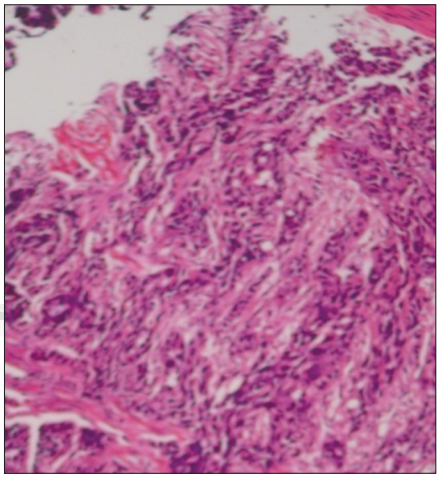

Figure 4: Biopsied mass showing poorly-differentiated gastric adenocarcinoma, magnification ×400

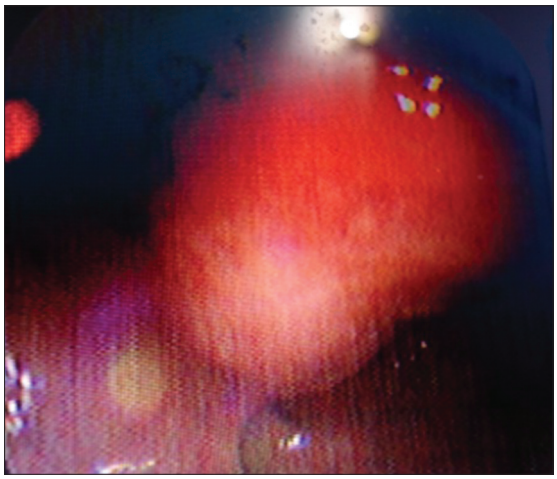

Figure 5: Huge mass at the antrum of the stomach

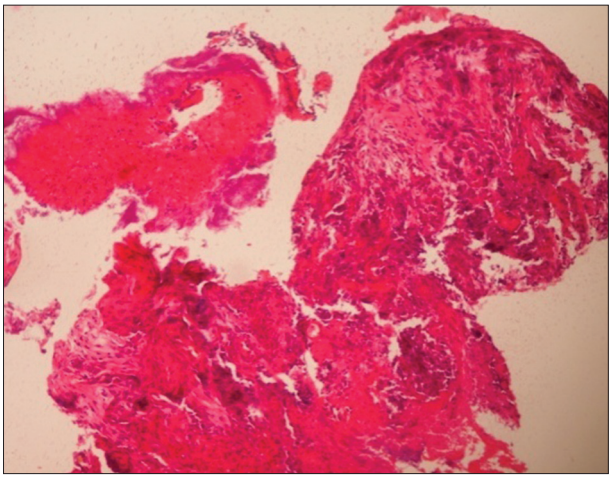

Figure 6: Fragments from gastric biopsy showing malignant epithelial cells in poorly formed glands, magnification ×400

[Downloaded free from http://www.nigeriamedj.com on Wednesday, April 10, 2013, IP: 82.128.53.90] || Click here to download free Android application for this journ

adenocarcinoma of the gastric mucosa infiltrating and dissecting the muscularis propria; there was no evidence of *H. pylori* in the biopsy sample [Figure 4]. He had a partial gastrectomy, and is presently on chemotherapy. He is being followed up in the clinic.

Case III

A 38-year-old female primary school teacher who presented in August 2012 with a 12-month history of recurrent epigastric pain, which responded initially to anti-ulcer medications, but later developed anorexia, early satiety, weight loss and vomiting. She had no history of dysphagia or odynophagia. She also had no history of intake of smoked foods, alcohol consumption, cigarette smoking or family history of GI malignancy. Physical examination was unremarkable except for palor and epigastric tenderness. Upper GI endoscopy revealed a huge friable rounded mass at the antrum of the stomach making it impossible to intubate the duodenum [Figure 5]. Biopsy and histology showed malignant epithelial cells in poorly formed glands. There was no evidence of *H. pylori* in the biopsy sample [Figure 6]. She is presently being worked up for surgery and chemotherapy.

Staining for *H. pylori* in all the three patients was carried out with Haematoxillin and Eosin, and Giemsa staining, although immunohistochemistry would have been better in staining for the organism.

DISCUSSION

Although gastric cancer is largely a disease of the older age groups, it has also been reported in the young.[3-5] This condition is known to be more common in males compared with females,[4,5] as was our experience in this report. The presenting symptoms were typical in our patients with epigastric pain, recurrent vomiting and weight loss. *Bakare et al.*[5] in north-eastern Nigeria, found the antrum of the stomach to be the most predominant location of gastric tumour, while *Bai et al.*[3] found the gastric corpus to be the predominant location of the tumour among young Chinese patients. All our patients had their tumours located in the antrum of the stomach. Gastric adenocarcinoma is the most predominant histologic type worldwide.[2,9] This also was our experience in this report. The only identifiable risk factor for gastric cancer was the consumption of salted and smoked fish by the 29-year-old farmer. Although the association of *H. pylori* infection and gastric cancer is well documented,[9-11] there was no evidence of *H. pylori* infection in our report.

In conclusion, dyspepsia in the young age group could herald gastric cancer. It is recommended that attending physicians should have a high index of suspicion for gastric cancer in young adults with dyspepsia especially when the dyspepsia is poorly responsive to therapy.

REFERENCES

1. Fuchs CS, Mayer RJ. Gastric carcinoma. N Engl J Med 1995;333:32-41.
2. Roder DM. The epidemiology of gastric cancer. Gastric Cancer 2002;5:5-11.
3. Bai Y, Li Z. Endoscopic, clinico-pathological features and prognosis of very young patients with gastric cancer. J Gastroenterol Hepatol 2011;26:1626-9.
4. Alatise OI, Lawal OO, Adesunkanmi AK, Agbakuru AE, Arigbabu OA, Ndububa DA, *et al*. Clinical pattern and management of gastric cancer in ile-ife, Nigeria. Arab J Gastroenterol 2007;8:123-6.
5. Bakare AA, Ibrahim AG, Gali BM, Dogo D, Nggada HA. Pattern of gastric cancer in North-eastern Nigeria. A clinico – pathological study. J Chin clin Med 2010;5:211-5.
6. Deodhar SD, Mohite JD, Joshi AS, Vora IM. Gastric carcinoma in the young (review of 14 cases). J Postgrad Med 1990;36:27-30.
7. Pavithran K, Doval DC, Pandey KK. Gastric cancer in India. Gastric Cancer 2002;5:240-3.
8. Mandong BM, Manasseh AN, Tanko MN, Echejoh GO, Madaki AJ. Epidemiology of gastric cancer in Jos University Teaching Hospital, Jos a 20 year review of cases. Niger J Med 2010;19:451-4.
9. Ho SB. Tumors of the stomach and small intestine. In: Friedman SL, McQuaid KR, Grendell JH, editors. Current diagnosis and treatment in Gastroenterology. 2nd ed. New York: McGraw-Hill; 2003. p. 389-402.
10. Konturek PC, Konturek SJ, Brzozowski T. *Helicobacter pylori* infection in gastric carcinogenesis. J Physiol Pharmacol 2009;60:3-21.
11. Zun-Wu Z, Farthing MJ. Molecular mechanisms of H. pylori associated gastric carcinogenesis. World J Gastroenterol 1999;5:369-74.

How to cite this article: Olokoba AB, Obateru OA, Bojuwoye MO, Ibrahim OK, Olokoba LB. That dyspepsia in the young could be cancer. Niger Med J 2013;54:143-5.

Source of Support: Nil, **Conflict of Interest:** None declared.