NATIONAL AGRICULTURAL AND FOOD CENTRE
RESEARCH INSTITUTE FOR ANIMAL PRODUCTION NITRA

Slovak J. Anim. Sci., 49, 2016 (1): 8–16
© 2016 NPPC
ISSN 1337-9984

TESTICULAR ULTRASOUND AS A BREEDING SOUNDNESS EXAMINATION AND BIOMETRIC TOOL FOR WEST AFRICAN DWARF BUCK GOATS

L. O. RAJI[1]*, O. O. AJALA[2], S. A. AMEEN[3]

[1]Department of Theriogenology and Production, University of Ilorin, Ilorin, Nigeria
[2]Department of Veterinary Surgery and Reproduction, University of Ibadan, Ibadan, Nigeria
[3]Department of Veterinary Medicine, University of Ilorin, Ilorin, Nigeria

ABSTRACT

This study was carried out to evaluate testicular ultrasound as a breeding soundness examination (BSE) and biometric tool for West African dwarf (WAD) buck goats. Twelve bucks of proven breeding capability were selected for this purpose. Scrotal circumferences of these animals were measured using a flexible tape. Testicular ultrasound was carried out on the transverse and longitudinal planes on the right and left testes. The electronic caliper on the ultrasound machine was used to measure the testicular length, height and width from which the testicular volume was calculated using the prolate ellipsoid formula (PEF), the prolate spheroid formula (PSF) and the Lambert formula (LF). These were compared with the true testicular volumes obtained by the water displacement method (WDM). Results showed that the mean scrotal circumference was 17.48 ± 0.31 cm. Testicular echo-texture revealed homogenously greyish parenchyma with hyper-echoic mediastinum line in the middle. The scrotal wall appeared as a hyper-echoic semi-circular border line at the caudo-dorsal portion of each testis. The heads of the epididymides of the right and left testes appeared as a small roundish hypo-echoic structure on the caudo-ventral and cranio-ventral portions of each testis respectively. Results of the parameters taken using the electronic caliper revealed that the mean width of both testes was 7.24 ± 0.16 cm. There was a high correlation between scrotal circumference and width of both testes measured on the ultrasound machine. There were no statistically significant differences between the means of the left and right testes length, height and width. Similarly, differences were not statistically significant in the testicular volumes obtained using the PEF and WDM. However, the testicular volumes obtained using the PSF and LF were significantly higher than the true testicular volumes obtained using the WDM. PEF was the best of the three formulae in estimating WAD buck testicular volume. In conclusion, we suggest that testicular ultrasound will be valuable in the BSE and in measuring the important biometric parameters in WAD buck goats.

Key words: testicular ultrasound; breeding soundness examination; West African dwarf buck goat

INTRODUCTION

The West African dwarf (WAD) goats are small ruminants endowed with great breeding potential. They are good sources of animal protein in terms of meat and milk (Devendra, 1999). Nevertheless, for improved production purposes, breeding soundness examination (BSE) is a prerequisite to investigating the fertility potentials of these animals. This is particularly more important in the buck because at least five does can be bred by one buck. The ratio is even many folds higher in assisted insemination programmes (Arrebola *et al*., 2012; Ajala *et al*., 2013). BSE includes the examination for physical soundness, testicular consistency and size, semen quality and mating ability (Ridler *et al*., 2012; Menegassi *et al*., 2014). During this examination, particular attention is given to the testes as it is the site of production of sperm cells and testosterone. The sperm cells are important for the fertilization of the ova from the doe while testosterone is responsible

***Correspondence:** E-mail: raji.lo@unilorin.edu.ng
Lukman Oladimeji Raji, Department of Theriogenology and Production,
Faculty of Veterinary Medicine, University of Ilorin, Ilorin, Kwara state, Nigeria
Tel.: +234 8038261951

Received: July 25, 2015
Accepted: February 13, 2016

for the production of sperm cells and other major WAD buck goat sexual characteristics required for efficient reproduction (Daramola *et al*., 2006; Udeh and Oghenesode, 2011). Even though in the routine BSE the testis is often palpated, the internal image or condition cannot be easily assessed. Hence, diagnosing normal and abnormal conditions of the testes is usually a difficult task. However, testicular ultrasound or sonogram offers a potential solution to this problem. It uses reflected sound waves to produce images of the testes, epididymis and scrotum. It is a safe, painless and non- invasive procedure. It does not use X-rays or other radiations and no side effects have been reported so far. The technique involves the use of a probe (transducer) to send sound waves into the testicular tissues. Reflective structures are referred to as being echogenic while the non-reflective ones are referred to as anechoic. Highly reflective structures are termed hyper-echoic while structures with low reflections are referred to as hypo-echoic (Dina Ragheb and Higgins, 2002). With this, the characteristic features of the normal and abnormal conditions of the testes and other associated structures like the epididymis can be observed. Research on testicular ultrasound has been carried out in cattle (Yimer *et al.*, 2011), camel (Pasha *et al*., 2011), sheep (Andrade *et al*., 2014), Alpine goats (Carazo *et al*., 2014) and dogs (Camara *et al*., 2014) but no such literature is available on WAD buck goats. Also, works on the use of testicular ultrasound to take into account the biometric parameters like testicular width, height and volume has not been carried out on WAD bucks. Some of these parameters are significant and have been reported to be important correlates of fertility. Testicular volume is an index of spermatogenesis. This is because ninety eight percent of the testicular volume is made up of seminiferous tubules which are responsible for spermatogenesis (Kollin *et al.*, 2006). This study was therefore carried out to evaluate testicular ultrasound as a BSE and biometric tool for WAD buck goats.

MATERIAL AND METHODS

Animals

Twelve matured healthy WAD buck goats of proven reproductive capability were selected for this study. The parameters taken and procedures carried out on these animals included:

Age: This was determined based on records from the breeders and by using the dentition formula for goats (Wosu, 2002).

Body weight: This was taken using bathroom scale (Camry®) as described by Raji and Ajala, (2015).

Scrotal circumference (SC): This was taken using a flexible tape as described earlier (Phillip and Okere, 2011; Raji and Ajala, 2015).

Testicular ultrasound and biometrics: In carrying out this, each buck was restrained by an assistant holding the animal firmly with the two limbs separated such that the testes were freely hanging caudally and at a distance of about 10 cm away from the ultrasound machine (UM). The testes were thoroughly cleaned with tissue paper before ultrasound gel (UG) was applied generously covering the entire testicular surface. The testes of the WAD buck is only covered by a thin layer of hair, hence there was no need for shaving. The UM was connected to a stabilizer which was fixed to a light source. The convex shaped transducer was then connected carefully to the monitor and switched on to the real time single B – mode at a frequency of 7.5 MHz. The UG was also applied on the probe covering the entire surface and then pressed gently on the surface of the testes. The images produced on the monitor were frozen and stored on the UM. Testicular ultrasound protocol for the bucks involved viewing the transverse plane (TP) for both testes, the right testis and the left testis; and then on the longitudinal planes (LP) for the right testis and the left testis. The testicular parameters measured were: width of both testes (W-SC) which was taken on the TP for both testes. This was measured from the most lateral point of the right testis to the most lateral point of the left testis using the electronic caliper (Figure 1). The length of the testis (L) was taken on the LP and was measured from the most cranial point on the testis to the most caudal point of the testis using the electronic caliper (Figure 2). The height of the testis (H) was measured by placing the electronic caliper from the highest ventral to the lowest dorsal points of the testes on the LP (Figure 2). The width (W) was measured as the widest diameter between the lateral and medial aspects of the testes on the TP (Figure 3). The volume of each testis was then calculated using three different formulae namely the prolate ellipsoid formula (PEF) – $L \times H \times W \times 0.52$ cm^3, the prolate spheroid formula (PSF) – $L \times W^2 \times 0.52$ cm^3 and the Lambert formula (LF) – $L \times H \times W \times 0.71$ cm^3. These were compared with the true testicular volumes using the water displacement method as described by Mbaeri *et al*. (2012). The parameters measured were recorded and analyzed (Sotos and Tokar, 2012). The UM used for this study was Biocare Ultrasonic Diagnostic Equipment (Model: BU – 907). Images were displayed on grey scale.

Statistical analysis

The data obtained in this study were analyzed using the Pearson Product Moment Correlation (PPMC) and the Student t-test at the level of significance $P < 0.05$ using SPSS version 20.

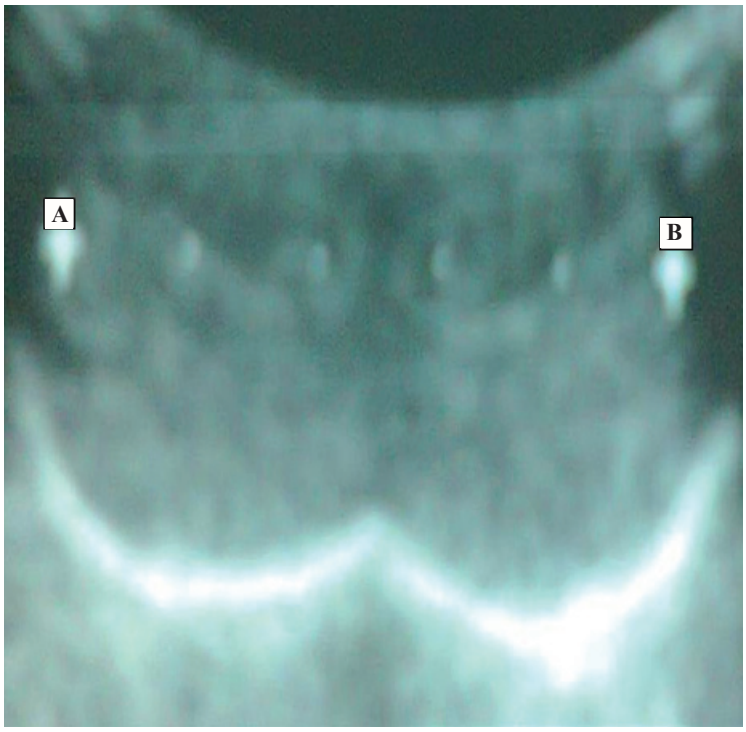

Fig. 1: Sonogram showing the width of both testes (A - B) on the transverse plane

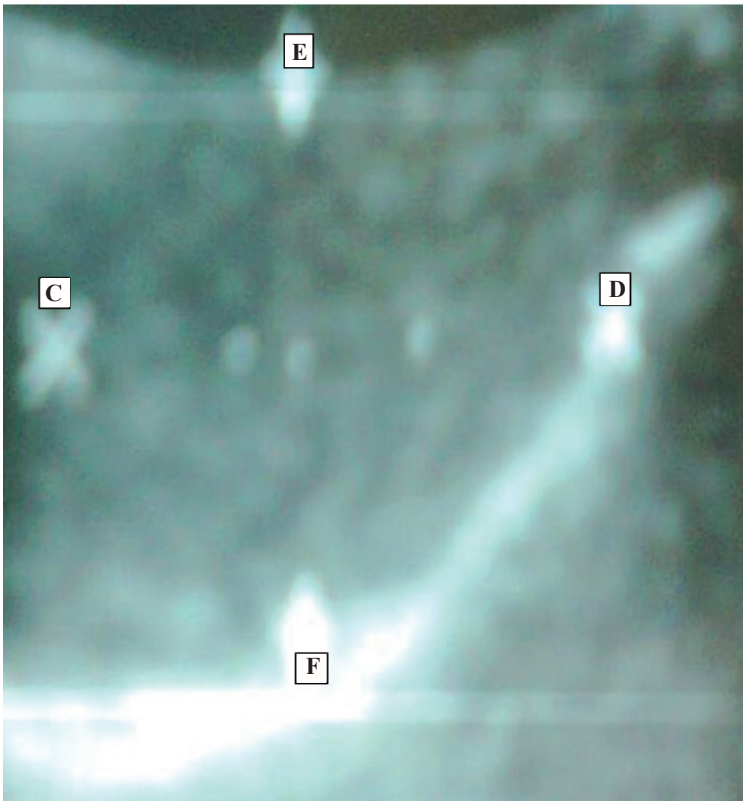

Fig. 2: Sonogram showing the length (C-D) and height (E-F) of the right testes on the longitudinal plane

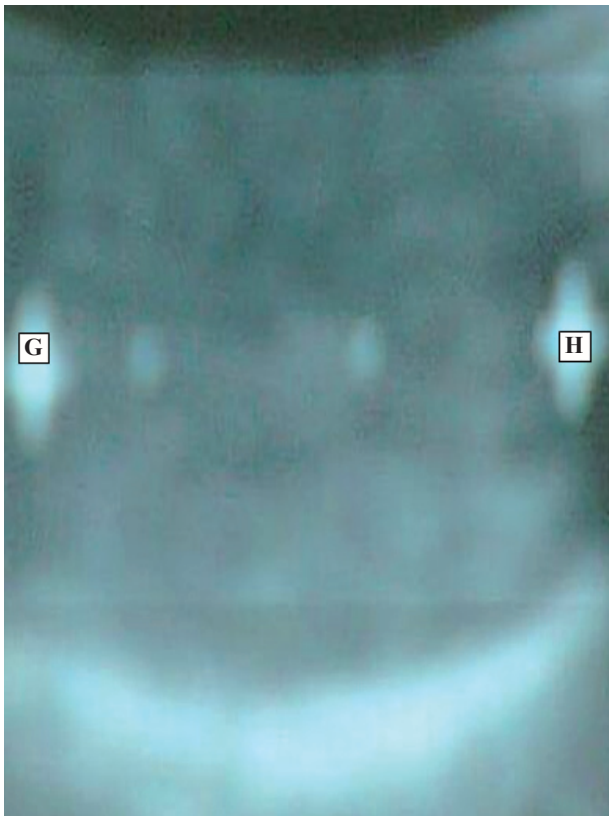

Fig. 3: Sonogram showing the width of testis (G-H) on the transverse plane

RESULTS

The bucks studied were between the ages 1 and 2 years. The average body weight and scrotal circumference observed were 12.6 ± 0.57 kg and 17.48 ± 0.31 cm respectively. Testicular ultrasound revealed that on the TP and LP for the right and left testes, testicular parenchyma appeared homogenously greyish while the mediastinum testes appeared as a white hyper-echoic thin line in the mid-section of the testes. The scrotal wall appeared as a thick hyper-echoic semi-circular layer forming a border line at the caudo-dorsal portion of each testis on the TP (Figure 4). The head of the epididymis of the right testis appeared as a small roundish dark hypo-echoic structure on the caudo-ventral part of the testes on the LP (Figure 5); while the head of the epididymis for the left testis appeared similar to that of the right testis but on the cranio-ventral portion of the testes also on the LP (Figure 6). The results for width of both the testes (W-SC), length, height and width of the right and left testes are as presented in Table 1. The mean W-SC was 7.24 ± 0.16 cm. This was highly correlated to the SC – 17.48 ± 0.31 cm ($r = 0.94$; $p \leq 0.01$). There were no significant differences between the means

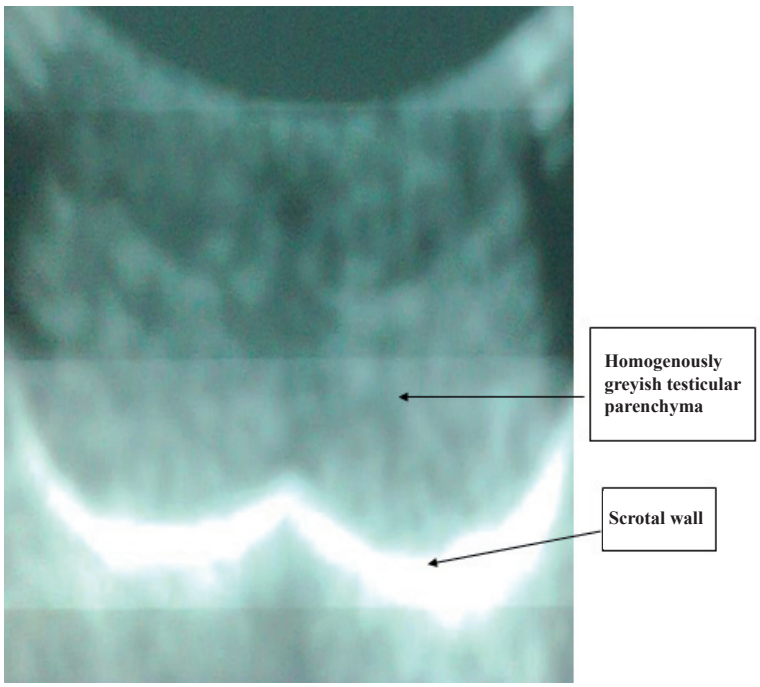

Fig. 4: Sonogram showing the homogenously greyish testicular parenchyma, and scrotal walls on the transverse plane of the right and left testes of the control group A buck

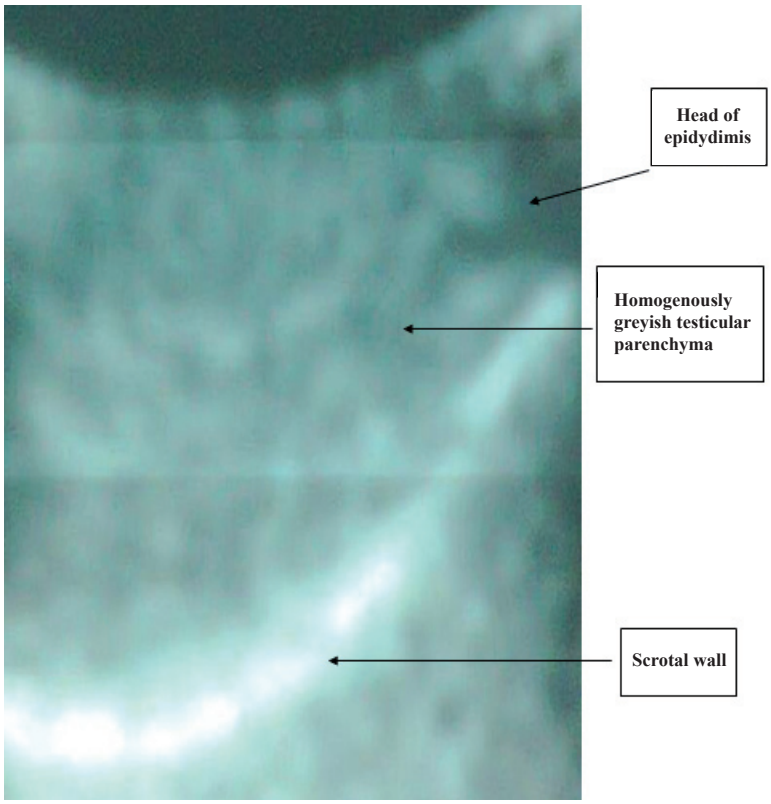

Fig. 5: Sonogram showing the head of the epidydimis, testicular parenchma and scrotal wall of the right testis on the longitudinal plane

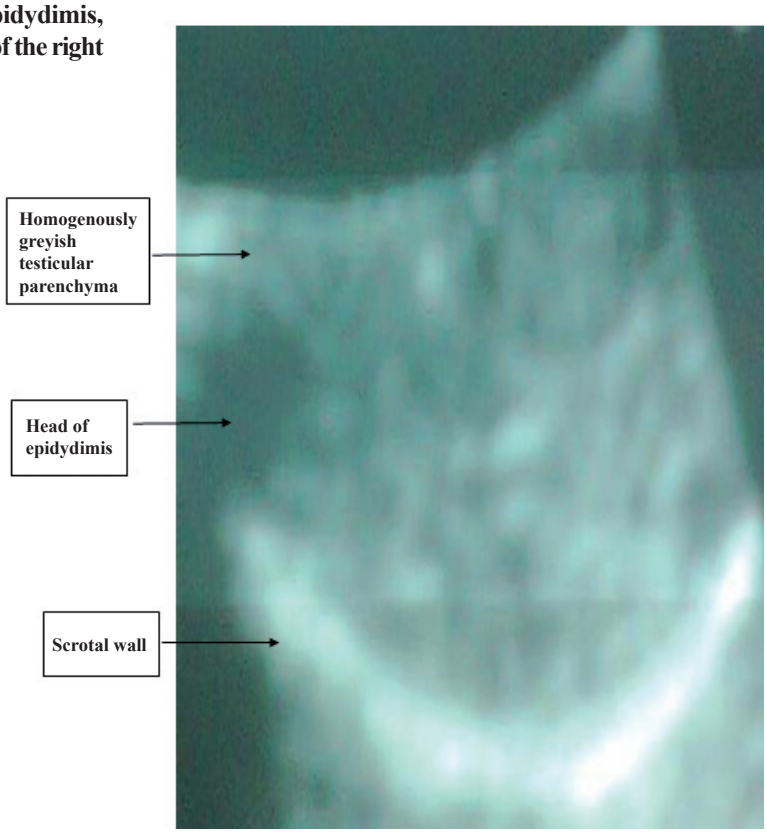

Fig. 6: Sonogram showing the head of the epidydimis, testicular parenchyma and scrotal wall of the left testis on the longitudinal plane

of the left and right testes length, height and width (p = 0.79, p = 0.81, p = 0.82, at the level of significance p < 0.05) respectively. The result for the testicular volume for the WAD buck goats are as presented in Table 2. There were no significant differences between the means of the true testicular volumes obtained by the WDM and the testicular volume obtained using the PEF for the right testis (p = 0.83) and left testis (p = 0.96) respectively. Similarly, no significant differences could be noted when the testicular volumes obtained by PSF were compared with those obtained using the LF for the right testis (p = 0.65) and the left testis (p = 0.47), respectively. However, the testicular volumes calculated by using the PSF were significantly higher than the true testicular volumes obtained by the WDM for the right testis (p = 0.02) and the left testis (p = 0.01), respectively. Similarly, no significant differences were observed when the testicular volumes obtained using the LF were compared with those obtained by the WDM for the right testis (p = 0.03) and the left testis (p = 0.02), respectively. The testicular volumes calculated by using the PSF were significantly higher than the testicular volumes obtained by the PEF for the right testis (p = 0.02) and the left testis (p = 0.01), respectively. Similarly, there were no significant differences when the testicular volumes obtained using the LF were compared with those obtained by the PEF for the right testis (p = 0.02) and the left testis (p = 0.02), respectively.

DISCUSSION

This study was conducted to evaluate testicular ultrasound as a BSE and biometric tool for WAD buck goats. The age, weight and scrotal circumference (SC) of the WAD buck studied were similar to those reported in matured WAD buck goats by Ugwu (2009). We also observed that the testicular echo-texture of the WAD buck goats were similar to those reported in fertile bulls (Ali *et al.*, 2011), rams (Ulker *et al*., 2005), camels (Pasha *et al*., 2011) and Alapine goats (Carazo *et al*., 2014).

The width of both the testes (W-SC) measured on the ultrasound machine was highly correlated to the SC measured with the flexible tape. We suggest that this could be taken as the SC when performing testicular ultrasound. Further studies should be carried out in this species and other species and breeds of animals to establish and further standardize this finding. We suggest this as a new finding to be adopted in the improved clinical approach to BSE of WAD buck goats.

Table 1: The testicular width of both testes, length, height and width of the of the right and left testis of West African Dwarf bucks measured using the electronic caliper on ultrasound machine

Goats	LRT (cm)	HRT (cm)	WRT (cm)	LLT (cm)	HLT (cm)	WLT (cm)	WDBT (cm)
1	6.03	2.61	3.65	5.91	2.52	3.49	7.14
2	5.98	2.53	3.50	6.03	2.54	3.70	7.20
3	5.87	2.58	3.44	5.89	2.58	3.66	7.10
4	6.19	2.57	3.73	6.07	2.56	3.48	7.21
5	5.92	2.48	3.57	5.88	2.51	3.81	7.38
6	5.83	2.54	3.71	5.79	2.52	3.53	7.24
7	6.23	2.59	3.65	6.12	2.53	3.69	7.34
8	5.97	2.50	3.40	5.91	2.49	3.54	6.94
9	5.83	2.61	3.76	5.80	2.59	3.80	7.56
10	6.16	2.50	3.59	6.07	2.50	3.62	7.21
11	5.94	2.55	3.61	5.86	2.56	3.60	7.21
12	5.87	2.56	3.72	5.92	2.51	3.64	7.36
	5.99	2.55	3.61	5.94	2.53	3.63	7.24
	± 0.14	± 0.04	± 0.12	± 0.11	± 0.03	± 0.11	± 0.16

P < 0.05 level of significance.
LRT- length of right testis, HRT – Height of right testis, WRT – width of right testis, LLT – length of left testis, HLT – height of left testis, WLT – width of left testis, WDBT – width of both testis.

Table 2: The testicular volume of West African Dwarf bucks taken using the water displacement method, prolate ellipsoid formula, prolate spheroid formula and Lambert formula (mean ± standard deviation)

Goats	Right Testis				Left Testis			
	VWDM (cm^3)	VPEF (cm^3)	VPSF (cm^3)	VLF (cm^3)	VWDM (cm^3)	VPEF (cm^3)	VPSF (cm^3)	VLF (cm^3)
1	28.00	29.87	41.77	40.79	29.00	27.03	37.43	36.90
2	29.40	27.54	38.09	37.60	27.90	29.47	42.93	40.24
3	28.80	27.09	36.12	36.99	28.30	28.92	41.03	39.49
4	27.90	30.86	44.78	42.13	28.00	28.12	38.23	38.39
5	29.10	27.25	39.23	37.21	28.70	29.24	44.38	39.92
6	28.90	28.57	41.73	39.01	28.40	26.78	37.52	36.59
7	28.60	30.63	43.16	41.82	27.90	29.71	43.33	40.57
8	28.00	26.39	35.89	36.03	28.40	27.09	38.51	36.99
9	28.50	29.75	42.86	40.62	27.90	29.68	43.55	40.53
10	29.30	28.75	41.28	39.25	28.40	28.57	41.36	39.00
11	27.90	28.43	40.25	38.82	28.10	28.08	39.49	38.34
12	28.60	29.07	42.24	39.69	29.40	28.13	40.79	38.40
	28.58^{*acd} ± 0.54	28.68^{*bcd} ± 1.43	40.62^{*cab} ± 2.79	39.16^{*dab} ± 1.95	28.37^{*egh} ± 0.47	28.40^{*fgh} ± 1.04	40.71^{*gef} ± 2.47	38.78^{*hef} ± 1.42

P < 0.05 level of significance.. *Significant acd i.e when column a is compared with column c and d respectively etc.
VWDM – volume by water displacement method, VPEF – volume by prolate ellipsoid formula,
VPSF – volume by prolate spheroid formula, VLF – volume by Lambert formula.

The testicular ultrasound biometric study also revealed that the mean length, height and width of the right testis were 5.99 ± 0.14 cm, 2.53 ± 0.04 cm and 3.61 ± 0.12 cm, respectively; and the left testis were 5.94 ± 0.11 cm, 2.53 ± 0.03 cm and 3.63 ± 0.11 cm, respectively. There were no significant differences when these parameters were compared between the right and the left testis. These are similar to the reports in humans but with some variation in the values of these parameters, probably due to species variation (Behre *et al*., 1989; Kiridi *et al*., 2012). However, reports on these testicular biometric parameters are scarce in the animal species. Further studies should be carried out for comparison and most importantly for improved production. This is the first report on these testicular ultrasound biometric parameters in WAD buck goat as far as the literature suggests. Also, the mean testicular volumes by VWDM, PEF, PSF and LF for the right testis were 28.58 ± 0.54 cm^3, 28.68 ± 1.43 cm^3, 40. 62 ± 2.79 cm^3 and 39.16 cm^3, respectively; and those for the left testis were 28.37 ± 0.47 cm^3, 28.40 ± 1.04 cm^3, 40.71 ± 2.47 cm^3 and 38.78 ± 1.42 cm^3, respectively. The PEF estimated testicular volumes closest to the true testicular volumes obtained by WDM without any significant difference. However, the PSF and LF over-estimated the testicular volume in these WAD buck goats, in our own view. We suggest that the PEF is the best of the three formulae, in estimating the testicular volume of the WAD buck breed of goat. Further studies should be carried out to fully establish this in these animals and other breeds and species as well. Souza *et al*. (2012) used the PEF to estimate testicular volumes in canine species. But they did not compare this with the other formulae and methods used by us in this study. However, Paltiel *et al.* (2002) compared these three formulae also in canine species and recommended the LF as the preferred formula for clinical practice. In humans, the LF was also reported to be the preferred formula for estimating testicular volume (Sotos and Tokar, 2012; Kiridi *et al*., 2007). This variation may be due to species differences but as far as this study is concerned, as suggested, the PEF is the preferred formula for testicular volume estimation in the WAD buck goat. These findings for the first time suggest these as valuable source of animal protein thus offering a new, more accurate, none invasive method of evaluating testicular volume which can be adopted to replace the invasive methods which require the removal of testes before testicular volume can be calculated (Franca *et al*., 2000). These alternatives offered by the use of TU in evaluating important testicular

parameters such as SC and TV will lead to a better clinical approach to predicting fertility potentials and possible rapid diagnosis of infertility problems that are related to testicular dysfunctions in WAD buck goats. These are accrued to the fact that SC has been reported to be a significant correlate of fertility in buck goats (Bongso *et al*., 1982; Raji *et al*., 2008; Ugwu, 2009). Also, TV has been documented to be an important index of spermatogenesis because about 98 % of the testis is made up of the seminiferous tubules where sperm cells are produced (Kollin *et al*., 2006).

CONCLUSION

In conclusion, this study has shown that testicular ultrasound is a potentially valuable tool in the BSE and in measuring important testicular biometric parameters such as SC and testicular volume particularly by using the prolate ellipsoid formula (PEF) in WAD buck goats. Therefore, we suggest that its use and introduction into the BSE programmes of these bucks should be encouraged. Adoption and use of the findings of this study can go a long way in improving the WAD buck goat production thereby leading to availability of more supply of animal proteins.

ACKNOWLEDGEMENTS

We wish to thank all the farmers that supplied some of the animals that were used for this study.

REFERENCES

AJALA, O. O. – OLOYE, A. A. – ADEBOLA, O. A. 2013. Study of Effective Artificial Insemination in West African Dwarf (WAD) Does Using 10 % Coconut Milk-egg Yolk Citrate Extended Semen. *Nigerian Veterinary Journal*, vol. 33, 2013, p. 395–402.

ANDRADE, A. K. G. – SOARES, A. T. – FREITAS, F. F. – SILVA, S. V. – PENA-ALFARO, C. E. – BATISTA, A. M. – GUERRA, M. M. P. 2014. Testicular and epididymal ultrasonography in Santa Inês lambs raised in Brazil. *Animal Reproduction*, vol. 11, 2014, p. 110–118.

ALI, K. M. – AHMAD, N. – AKHTAR, N. – ALI, S. – AHMAD, M. – YOUNIS, M. 2011. Ultrasound Imaging of Testes and Epididymides of Normal and Infertile Breeding Bulls. *Pakistan Veterinary Journal*, vol. 31, 2011, p. 345–350.

ARREOLA, F. A. – PARDO, B. – SANCHEZ, M. – LOPEZ, M. D. – PEREZ-MARIN, C. C. 2012. Factors influencing the success of an artificial insemination program in Florida goats. *Spanish Journal of Agricultural Research*, vol. 10, 2012, p. 338–344.

BEHRE, H. M. – NAHSAN, D. – NIESCHLAG, E. 1989. "Objective measurement of testicular volume by ultrasound: Evaluaton of the technique and comparison with orchidometer estimates". *International Journal of Andrology*, vol. 12, 1989, p. 395–403.

BONGSO, T. A. – JAINUDEEN, M. R. – ZAHRAH, A. S. 1982. Relationship of scrotal circumference to age, body weight and onset of spermatogenesis in goats. *Theriogenology*, vol. 18, 1982, p. 513–524.

CAMARA, L. B. – CAMARA, D. R. – MAIORINO, F. C. – SILVA JUNIOR, V. A. – GUERRA, M. P. 2014. Canine testicular disorders and their influence on sperm morphology. *Animal Reproduction*, vol. 11, 2014, p. 32–36.

CARAZO, L. R. – GUIMARAES, J. D. – MACHADO, T. P. – MACHADO, T. P. L. C. – OLIVEIRA, F. A. S. A. M. – PEREIRA, D. B. 2014. Testicular ultrasonography in young Alpine goats. *Arquivo Brasileiro de Medicina Veterinariae Zootecnia*, vol. 66, 2014, p. 388–394.

DARAMOLA, J. O. – ADELOYE, A. A. – FAYEYE, T. R. – FATOBA, T. A. – SOLADOYE, O. A. 2006. Influence of Photoperiods with or Without Melatonin on Spermiograms in West African Dwarf Bucks. *World Journal of Zoology*, vol. 1, 2006, p. 86–90,

DAVENDRA, C. 1999. Goats: Challenges for increased productivity and improved livelihoods. *Outlook on Agriculture*, vol. 28, 1999, p. 215–226.

DINA RAGHEB, M. D. – HIGGINS, J. L. 2002. Ultrasonography of the scrotum: Technique, Anatomy and Pathologic entities. *Journal of Ultrasound in Medicine*, vol. 21, 2002, p. 171–185.

FRANCA, L. R. – SILVA, V. A. – CHIARINI-GARCIA, H. – GARCIA, S. K. – DEBELJUK, L. 2000. Cell proliferation and hormonal changes during postnatal development of the testis in the pig. *Biology of Reproduction*, vol. 63, 2000, 1629–1636.

KIRIDI, E. K. – NWANKWO, N. C. – AKINOLA, R. A. – AGI, C. A. – AHMAD, A. 2012. Ultrasound Measurement of Testicular Volume in Healthy Nigerian Adults. *Journal of Asian Scientific Research*, vol. 2, 2012, p. 45–52.

KOLLIN, C. – HESSER, U. – RITZEN, E. M. – KARPE, B. 2006. Testicular growth from birth to two years of age and the effect of orchidopexy at age nine months: a randomized, controlled study. *Acta Paediatrica*, vol. 95, 2006, p. 318–324.

MBAERI, T. U. – ORAKWE, J. C. – NWOFOR, A. M. – ORANUSI, K. C. – MBONU, O. O. 2012. Accuracy of Prader orchidometer in measuring testicular volume. *Nigerian Journal of Clinicalpractice*, vol. 16, 2012, p. 348–351.

MENEGASSI, S. R. O. – BARCELLOS, J. O. J. – BORGES, J. B. S. – CANOZZI, M. E. A. – PRIPOLLI, V. – JUNIOR, C. K. – LOPES, F. G. – CERVO, H. J. 2014. Breeding Soundness Examination: Understanding the causes of examination failure in young and mature rams. *International Journal of Plant and Animal Sciences*, vol. 2, 2014, p. 98–104.

PALTIEL, H. S. – DIAMOND, D. A. – DI CANZIO, J. – ZURAKOWSKI, D. – BORER, J. G. – ATALA, A. 2002. Testicular volume: comparison of orchidometer and US measurements in dogs. *Radiology*, vol. 222, 2002, p. 114–119.

PASHA, R. H. – QURESHI, A. S. – LODHI, L. A. – JAMIL, H. 2011. Biometric and Ultrasonographic Evaluation of the Testis of One-humped Camel (*Camelus dromedarius*). *Pakistan Veterinary Journal*, vol. 31, 2011, p. 129–133.

RAJI, A. O. – KWEBUIKE, J. U. – ALIYA, J. 2008. Testicular Biometry and its Relationship with Body Weight of Indigenous Goats in a Semi-arid Region in Nigeria. *Journal of Agriculture and Biological Sciences*, vol. 39, 2008, p. 6–9.

RAJI, L. O. – AJALA, O. O. 2015. Scrotal circumference As a Parameter of Breeding Age for West African Dwarf Bucks. *Turkish Journal of Agriculture – Food Science and Technology*, vol. 3, 2015, p. 668–671.

RIDLER, A. L. – SMITH, S. H. – WEST, D. M. 2012. Ram and Buck management. *Animal Reproduction Science*, vol. 130, 2012, p. 180–183.

SOTOS, J. F. – TOKAR, N. J. 2012. Testicular volumes revisited: A proposal for a simple clinical method that can closely match the volumes obtained by ultrasound and its clinical application. *International Journal of Pediatric Endocrinology*, vol. 17, 2012, p. 1–11.

SOUZA, M. B. – BARBOSA, C. C. – PINTO, J. N. – UCHOA, D. C. – CAMPELLO, C. C. – SILVA, L. D. M. 2012. Comparison of testicular volume between French Bulldog and Brazilian Terrier dogs. *7th International Symposium on Canine and Feline Reproduction*, 2012, p. 1–3.

UDEH, I. – OGHENESODE, B. 2011. Effects of Type of Extender and Storage Conditions on the Motility of Goat Spermatozoa. *International Journal of Animal and Veterinary Advances*, vol. 3, 2011, p. 282–286.

UGWU, S. O. C. 2009. Relation between SC in-situ testicular measurements and sperm reserves in the WAD bucks. *African Journal of Biotechnology*, vol. 8, 2009, p. 1354–1357.

ÜLKER, H. – KANTERB, M. – GOKDALC, O. – AYGUNA, T. – KARAKUS, F. – SAKARYAD, M. E. – DAVID, M. A. – JERRY, J. R. 2005. Testicular development, ultrasonographic and histological appearance of the testis in ram lambs immunized against recombinant LHRH fusion proteins. *Animal Reproduction Science*, vol. 86, 2009, p. 205–219.

WOSU, L. O. 2002. Ageing of sheep and goats. In: The Veterinarian‘s Handbook. Mike Social Press, Nsukka, Nigeria, 2002, p. 44–45

YIMER, N. – ROSNINA, Y. – WAHID, H. – SAHAREE, A. A. – YAP, K. C. – GANESAMURTHI, P. – FAHMI, M. M. 2011. Trans-scrotal Ultrasonography and Breeding Soundness Evaluation of Bulls in a Herd of Dairy and Beef Cattle with Poor Reproductive Performance. Pertanika. *Journal of Tropical Agricultural Science*, vol. 34, 2009, p. 217–228.